

## Case Report

### Leiomyosarcoma of the Broad Ligament: A Case Report and Literature Review

Saadat Mirsadraee<sup>1</sup>, Ateie Mansouri<sup>2</sup>,  
Reza Ataei<sup>1</sup>, Sara Kakhi<sup>3</sup>

1. Dept. of Pathology, Mashhad University of Medical Sciences, Mashhad, Iran.

2. Dept. of Obstetrics and Gynecology, Mashhad University of Medical sciences, Mashhad, Iran.

3. Mashhad University of Medical Sciences, Mashhad, Iran.

#### ABSTRACT

Primary leiomyosarcoma of the broad ligament is a very rare, rapidly progressive and highly malignant gynecological tumor and only 16 cases have been reported in the literature.

Here, presentation of leiomyosarcoma of the left broad ligament in a 26-years-old woman is reported. Clinical presentation and histological diagnosis is discussed. The patient has been treated surgically and remains disease-free following three years follow up. A review of literature is also performed to discuss the diagnosis and management of leiomyosarcoma of broad ligament.

**Key words:** Broad ligament, Uterus, Leiomyosarcoma

#### Introduction

The most frequent solid tumor of the broad ligament is leiomyoma. In contrary, primary leiomasarcoma of the broad ligament is extremely rare. These tumors are rapidly progressive and highly malignant and rather seen in older age groups (1-6). Similarly, leiomyosarcoma of the ovary is also relatively rare with late presentation and poor prognosis. They are aggressive tumors and occur mostly in postmenopausal patients (1-6). Only 16 cases of primary leiomyosarcoma originating from the broad ligament have been previously reported (1-18)

(Table 1). The histological criteria for the diagnosis of leiomyosarcoma are high mitotic figures, cytological atypia, and areas of necrosis (13-16). Schmidt reported the first case of sarcoma of this site in 1887 (10), followed by few cases by German and French authors around the turn of century (11), but most of these were not diagnosed according to the criteria given by Gardner et al (7), and the last case have been reported in July 2007 by Ben Amara et al (1). In this study, a case of high grade leiomyosarcoma of the left broad ligament in a young patient with excellent response to surgery is described.

---

Received: 20 October 2007

Accepted: 7 December 2007

Address communications to: Dr Reza Ataei, Department of Pathology, Mashhad University of Medical Sciences, Mashhad, Iran.

Email: reza\_at641@yahoo.com

**Table 1: Leiomyosarcoma of broad ligament**

Case	Author	Age	Side of tumor	Mitosis/ 10 HPF	Initial treatment	Subsequent treatment	Survival
1	Lowell and Karsh (17)	50	Right	0-4	TAH BSO	—	>12 months
2	Ullman and Roumell (18)	50	Left	15	TAH BSO	RT, CT	7 months, DOD
3	Weed and Podger (21)	50	Left	12	TAH BSO	CT	19 months, DOD
4	DiDomenico et al (22)	48	Left	10.5	TAH BSO	—	No report
5	Raj-Kumar (13)	70	Left	<10	Enucleation	—	No report
6	Herbold et al (23)	73	Left	21	TAH BSO	—	1 months, DOD
7	Shimm and McDonough (24)	31	Right	8	Enucleation	RT, CT	>30 months
8	Lee et al (25)	36	Left	>10	TAH BSO	RT, CT	>33 months
9	Lee et al (25)	65	Left	>10	Subtotal hysterectomy BSO	CT	30 months, DOD
10	Cheng et al (8)	59	Right	>10	TAH BSO	—	Alive, >12 months
11	T.Pekin et al (9)	56	Right	14	TAH BSO	RT	Alive, >12 months
12	Shah et al (5)	87	Right	30-40	TAH BSO	—	2 months, DOD
13	Murialdo et al (3)	53	Right	<10	TAH BSO	—	Alive, >13 months
14	El-Idrissi et al (4)	52	Right	>10	TAH BSO	---	3 months, DOD
15	Falconi et al (2)	50	Right	>10	TAH BSO	---	DOD
16	Ben Amara et al (1)	49	Right	>10	TAH BSO, omentectomy and appendicectomy	---	5 months, DOD
17	Mirsadraei et al (This report)	26	Left	30-40	LSO and partial omentectomy	—	Alive, >3 years

TAH: total abdominal hysterectomy

BSO: bilateral salpingo-oophorectomy

RT: radiotherapy

DOD: dead of disease

HPF: high-power field

LSO: Left salpingo-oophorectomy

CT: chemotherapy

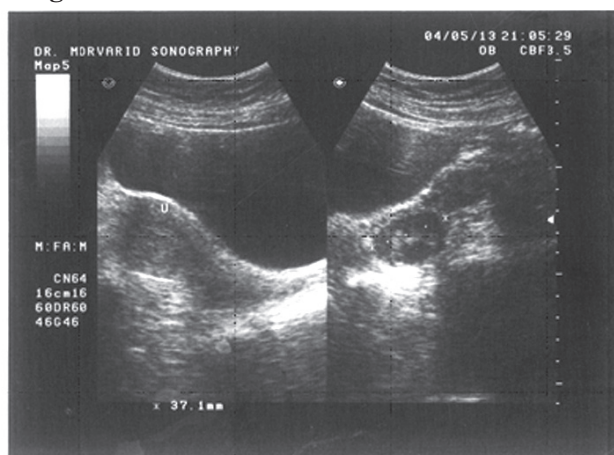
### Case report

A 26-years-old woman presented with fatigue, poor appetite, pelvic pain and metrorrhagia. The gynecological examination revealed a mass arising from the left side of the pelvis. On abdominal

examination, there was no evidence of ascites or metastasis. The past medical history was unremarkable. An ultrasound examination of the abdomen and pelvis showed a 37 mm isoechoic solid mass adherent to the posterior cortex of the left ovary.

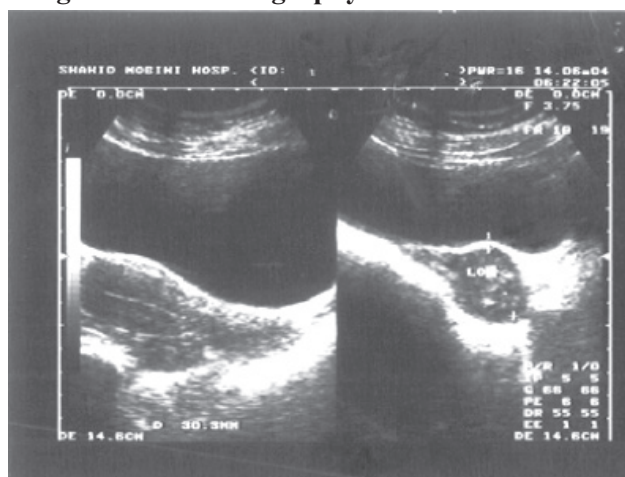
The uterus was normoechoic with normal thickness of endometrium (Figure 1). Ultrasonography also revealed another 30 mm heterogeneous lesion in the left ovary. Appearances were suggestive of an epidermoid cyst (Figure 2).

**Figure 1. An ultrasound examination of the**



abdomen and pelvis showed a 37 mm isoechoic solid mass adherent to the posterior cortex of the left ovary

**Figure 2. Ultrasonography also revealed another**




**30 mm heterogeneous lesion in the left ovary**

In laparotomy, a 5×4.5×4 cm well-defined solid and fibrotic mass within the left broad ligament was found (Figure 3). The cut surface had a raw silk appearance similar to what is seen in benign leiomyomas (Figure 4). Surgically, the uterus and left ovary appeared normal and small. No evidence of disease was found elsewhere in the abdomen and pelvis. Cytological examination of a peritoneal wash out showed no malignant cell. Histological examination of the intraligamentous mass confirmed a completely resected high grade leiomyosarcoma. Microscopic examination showed a

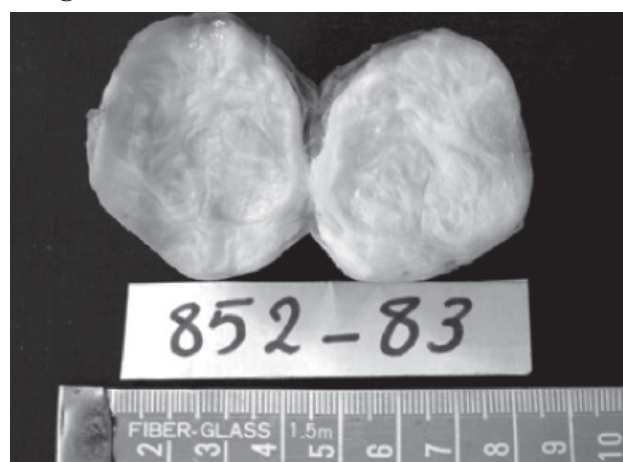
hypercellular tumor composed of malignant spindle cell (Figure 5) with moderate nuclear atypia and pleomorphism, and high rate of mitosis with some atypia (30-40 mitosis per ×10 high power field (HPF) (Figure 6). Further microscopical examination showed areas of necrosis (Figure 7) and generally morphology similar to that of a leiomyosarcoma of myometrium. There were no findings to suggest that the tumor originated anywhere other than the left broad ligament.

**Figure 3. A 5×4.5×4 cm well-defined solid and**




fibrotic mass within the left broad ligament was found

**Figure 4. The cut surface had a raw silk**




appearance similar to what is seen in benign leiomyomas



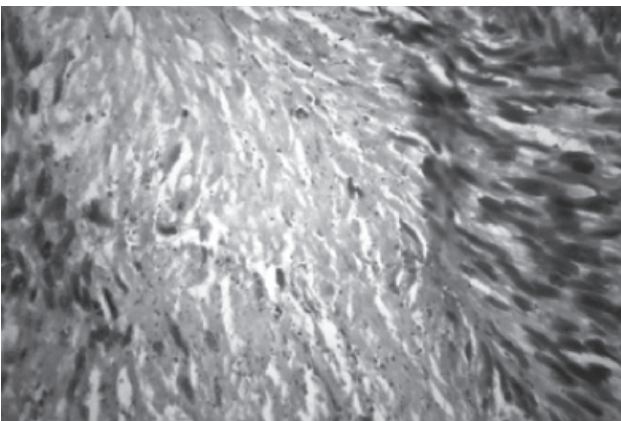


**Figure 5. Microscopic examination showed a hypercellular tumor composed of malignant spindle cell**

**Figure 6. Moderate nuclear atypia and pleomorphism and high rate of mitosis with some atypia**



**Figure 7. Microscopical examination showed areas of necrosis**



#### areas of necrosis

A further surgical laparotomy was performed a month later to remove any residual disease and a left salpingo-oophorectomy and partial omentectomy was performed. However, only histological evidence of

foreign body granulomatous reaction and no tumoral residue was found. During three years follow up, the patient remained free of disease without a need for further treatment. Furthermore, she had a successful pregnancy during the follow up period. Uterus and right adnexae were unremarkable during cesarean section.

## Discussion

Primary leiomyosarcoma originating in the broad ligament is a rare neoplasm.

Schmidt reported the first case of sarcoma of this site in 1887 (10), followed by few cases by German and French authors around the turn of century (11), but most of these cases did not match the criteria given by Gardner et al (7). Leiomyosarcoma of broad ligament occurs mainly in women in their post menopausal years with non-specific clinical manifestations and carries a poor prognosis. No diagnosis could be made preoperatively (1-6).

The patient reported in the current study was different in a number of ways. First, she was quite younger at 26 years compared to the reported mean age of 57 (5). Two other younger patients were also previously reported (31 and 36 years old) (5). The development of very quick recurrent pelvic disease in the absence of disseminated metastasis is an unusual behavior for leiomyosarcoma following surgery (5). The criteria for leiomyosarcoma proposed by Zaloudek and Norris of 10 or more mitotic figures per x10 HPF with cellular atypia were commonly used in previous recent reports (13). Recently, the reliance on mitotic figure counts has been questioned due to increased appreciation of the lack of reproducibility between observers and the influence of hormones and adjacent tissue necrosis (14). Their criteria to this unusual tumor specific to smooth muscle tumors originating in the broad ligament were: degree of cytological atypia none to mild or moderate to marked, presence or absence of coagulative tumor cell necrosis, and mitotic index if moderate/severe atypia is present without necrosis.

The histological differential diagnosis includes gastrointestinal stromal tumors, endometrial stromal sarcoma, and carcinoma (5). There was no convincing evidence of an origin in gastrointestinal tract with the tumor centered in the broad ligament and apparently invading other structures from outside. There was no coexisting endometrial or myometrial tumor apart from the benign leiomyomas and the morphology did not indicate an endometrial stromal sarcoma.

Extensive sampling of the tumor did not demonstrate epithelial elements and therefore there was no evidence for a diagnosis of carcinosarcoma. As very few cases of leiomyosarcoma of uterine ligament are reported, the exact nature and biological activity of the tumor remains poorly understood. The staging and management of leiomyosarcoma of broad ligament are currently based on criteria used for uterine leiomyosarcoma.

There is wide variation in the management practices of this uncommon tumor, but the cornerstone remains total abdominal hysterectomy with bilateral salpingo-oophorectomy (16). The ovaries should be conserved in the premenopausal patient with clinical early stage disease (16). Adjuvant chemotherapy and/or radiotherapy may be used in selected cases (16).

It is concluded that low grade leiomyosarcoma of the broad ligament should be only treated by surgery.

## References

1. Ben AF, Jouini H, Nasr M, Malek M, Neji K, Reziga H, et al. Primary leiomyosarcoma of broad ligament. *Tunis Med* 2007 Jul;85(7):591-5.
2. Falconi M, Crippa S, Sargenti M, Capelli P, Pederzoli P. Pancreatic metastasis from leiomyosarcoma of the broad ligament of the uterus. *Lancet Oncol* 2006 Jan;7(1):94-5.
3. Murialdo R, Usset A, Guido T, Carli F, Boccardo F, Amoroso D. Leiomyosarcoma of the broad ligament: a case report and review of literature. *Int J Gynecol Cancer* 2005 Nov;15(6):1226-9.
4. El-Idrissi F, Fadli A. [Leiomyosarcoma of the broad ligament]. *Presse Med* 2004 Sep 11;33(15):1004-5.
5. Shah A, Finn C, Light A. Leiomyosarcoma of the broad ligament: a case report and literature review. *Gynecol Oncol* 2003 Aug;90(2):450-2.
6. Kir G, Eren S, Akoz I, Kir M. Leiomyosarcoma of the broad ligament arising in a pre-existing pure neurilemmoma-like leiomyoma. *Eur J Gynaecol Oncol* 2003;24(6):505-6.
7. Gardner GH, Greene RR, Peckham B. Tumors of the broad ligament. *Am J Obstet Gynecol* 1957 Mar;73(3):536-54.
8. Cheng WF, Lin HH, Chen CK, Chang DY, Huang SC. Leiomyosarcoma of the broad ligament: a case report and literature review. *Gynecol Oncol* 1995 Jan;56(1):85-9.
9. Pekin T, Eren F, Pekin O. Leiomyosarcoma of the broad ligament: case report and literature review. *Eur J Gynaecol Oncol* 2000;21(3):318-9.
10. Schmidt K. Leiomyosarcoma of the broad ligament. *Prag Med Wschr* 1878;35:260.
11. Lubarsch O, Henke F. *Handbuch der speziellen pathologischen anatomic and histologic*. Berlin: Springer; 1993.
12. Kumarn R. *Blaustein's Pathology of the female genital tract*. New York: Springer-Verlag; 1987.
13. Raj-Kumar G. Leiomyosarcoma of probable ovarian or broad ligament origin. *Br J Obstet Gynaecol* 1982 Apr;89(4):327-9.
14. Bell SW, Kempson RL, Hendrickson MR. Problematic uterine smooth muscle neoplasms. A clinicopathologic study of 213 cases. *Am J Surg Pathol* 1994 Jun;18(6):535-58.
15. Hendrickson M, Kempson R. A diagnostic approach to smooth muscle tumours of the uterus. *Curr Diagn Pathol* 2000;6(1):21-30.
16. Gard GB, Mulvany NJ, Quinn MA. Management of uterine leiomyosarcoma in Australia. *Aust N Z J Obstet Gynaecol* 1999 Feb;39(1):93-8.
17. Lowell DM, Karsh J. Leiomyosarcoma of the broad ligament. A case report. *Obstet Gynecol* 1968 Jul;32(1):107-10.
18. Ullmann AS, Roumell TL. A case report. Leiomyosarcoma of the broad ligament. *Mich Med* 1973 Jun;72(18):411-4.