

Case Report

Ureteral Endometriosis: A Report of Two Cases

Nasser Rakhshani¹, Arman Morakabati², Mohsen Ayati³, Mahshid Hoormazdi⁴

1.Dept. of Pathology, Iran University of Medical Sciences, Tehran, Iran.

2.Dept. of pathology, Qom University of Medical Sciences, Qom, Iran.

3.Dept. of Urology, Tehran University of Medical Sciences, Tehran, Iran.

4.Dept. of Pathology, Mehr Hospital, Tehran, Iran.

ABSTRACT

Endometriosis is the presence of benign endometrial glands and stroma outside the uterus. Urinary system involvement by endometriosis is a rare occurrence accounting for only 1.5 % of all endometriosis cases.

Case 1. The patient was a 41 years old woman admitted for right flank pain. The physical and gynaecologic examination was unyielding. Intravenous urography (IVU) revealed stenosis in distal part of right ureter, unfortunately associated with hydronephrosis. Case 2. A 26 years old woman who suffered from colic pain in low abdomen and pelvis. The only positive finding was microscopic hematuria. Abdominal sonography showed hydronephrosis of right kidney and proximal part of ureter. Ureterolysis by an open surgical procedure performed for both patients and histologic examination revealed endometriosis of ureter.

Endometriosis of ureter is mainly asymptomatic and unfortunately ends in functionless kidney due to prolonged hydronephrosis. Early diagnosis needs high index of suspicion and intended use of paraclinic aids to save patients normal renal function. An individualized therapy plan depending on the patient's age and the extent of the endometriosis should be attempted.

Key words: Endometriosis, Ureteral Obstruction, Hydronephrosis

Introduction

Endometriosis is defined as the presence of endometrial glands and stroma outside the uterus and is the second most common pelvic pathology in females (1). It is most commonly diagnosed in women at child-bearing age, with a peak age of 40 to 44 years (2). It can also occur in menopausal women if taking exogenous estrogen or during increased endogenous production of estrogen

from the adrenals or pituitary gland. The most common sites of involvement are ovaries, fallopian tubes, rectovaginal septum, and pelvic peritoneum and cul-de-sac in the order of decreased frequency. In addition, it has also been described in the skin, lungs, diaphragm, gastrointestinal tract (colon), laparotomy incision site, umbilicus, obturator nerve and axillary lymph nodes (3). Involvement of the genitourinary tract has been reported at an incidence of 1.5%, with

Received: 2 May 2008

Accepted: 8 July 2008

Address communications to: Dr. Nasser Rakhshani, Department of Pathology, Iran University of Medical Sciences, Tehran, Iran.

Email: n_rakhshani@yahoo.com

peak age incidence at 30 to 35 years (4). The ratio of bladder-to-ureteral-to-urethral involvement is 40:5:1 (5). In a review of 147 patients with endometriosis, Abeshouse and Abeshouse noted that involvement of the bladder, ureter, kidney and urethra to be 85%, 10%, 4% and 2% respectively (6).

Ureteral endometriosis is a rare entity and its diagnosis requires a high index of suspicion. Cullen described the first case of endometriosis causing obstructive uropathy in 1917(7). Since then, more than 200 cases of ureteral obstruction due to endometriotic implants have been described in the medical literature, but the actual prevalence of this condition is difficult to determine. Because of its association with silent renal obstruction, up to 47% of patients will require nephrectomy at the time of diagnosis (8). Most reported cases are unilateral. However, endometriosis involving both ureters has been described in patients with more extensive pelvic disease (9). Ureteral endometriosis is more commonly observed in the distal segment of the left ureter. The close anatomical proximity of the distal ureter to the female reproductive organs makes it an ideal target for the development of extrinsic compression of the ureter. To date, only 1 known case of mid-ureteral endometriosis has been reported, and endometriosis affecting the proximal ureter has not been previously noted (10).

Case reports

Case report 1

The patient was a 41 years old woman admitted for right flank pain. The gynaecologic examination was unyielding. Imaging study (sonography, IVU and pelvic CT scan) revealed stenosis in distal part of right ureter associated with hydronephrosis (Fig1). The patient planned for cystoscopy and ureter stenting but the ureteral sond of ureteroscope failed to go up more than 6 cm, so surgery with right Gibson incision was performed. The ureter was obstructed 4-6 cm above the bladder. The stenotic region resected with a safe margin because of the fear of malignancy and anastomosis carried out by Psoas Hitch method. The pathology examination revealed dilated glandular structures with cuboidal linings along with foci of endometrial stroma and hemorrhage mainly in subserosa and muscular coatings of ureter wall. Ureter stent removed 4 weeks after surgery.

Case report 2

A 26 years old woman came to visit with a complaint

of right flank pain. The physical and gynaecologic examination and all laboratory workups were normal except for microscopic hematuria reported in previous urine analysis. Ultrasonography showed right kidney hydronephrosis. CT scan and IVU revealed stenosis of distal portion of right ureter. The patient planned for surgery; after opening by Gibson incision and resection of stenosis, anastomosis performed by Psoas Hitch method. The histologic examination of the submitted specimen confirmed ureteral endometriosis characterized by endometrial glands and stroma located in outer half of ureter wall which extends to submucosa (Fig. 2). The patient discharged in good health condition and ureter stent removed after 4 weeks.

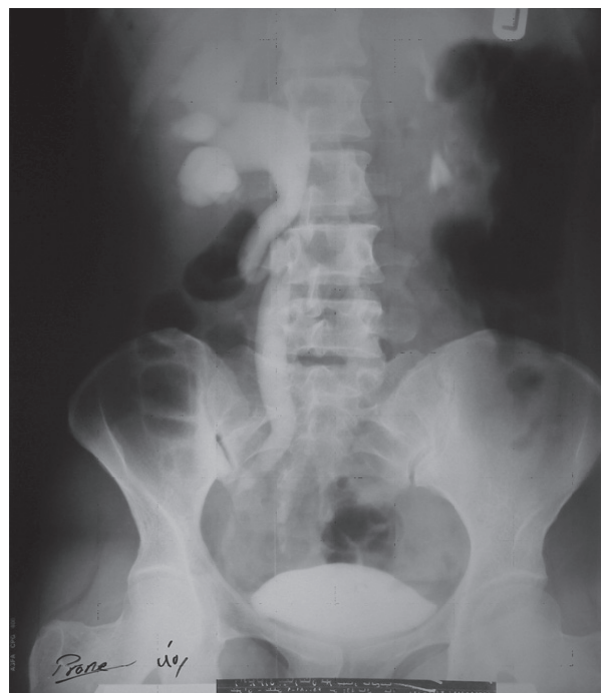

Fig. 1: The right kidney shows hydronephrosis and the ureteral obstruction is visible above the bladder

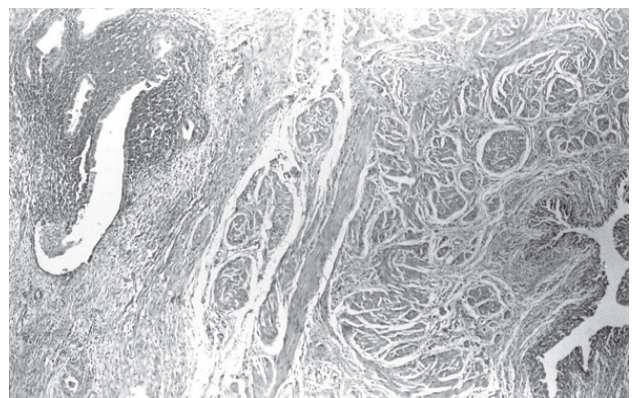


Fig. 2: The histologic examination revealed endometrial glands and hemorrhage in subserosa of ureter (H&E Staining ×100)

Discussion

Ureteral endometriosis is categorized into two groups as extrinsic and intrinsic. The extrinsic one is more common and constitutes more than 80% of reported literature. The serosa is the sole site of involvement in this type (11). The internal type is less common in which the submucosa is the main site of involvement. The distinction of extrinsic or intrinsic nature of ureteral involvement may be somewhat arbitrary, since the depth of invasion in the extrinsic form is seldom histologically corroborated and the differentiation could not be reliably made (12). Combined external and internal endometriosis of ureter are also seen and either type may or may not present with other foci of endometriosis (12).

The pathophysiology of endometriosis is unclear, more so with ureteral involvement than other sites of endometriosis. Several presumed mechanisms are "direct transfer" of endometrial tissue (5;6;13) lymphatic or even hematogenous spread or metaplastic transformation of Mullerian and Wolffian duct remnants. Some evidences such as previous history of pelvic surgery supports the theory of direct transfer (5). Rock and Markham have also postulated the immunologic mechanisms as a cause for endometriosis at least in some cases (13). Although all the proposed theories are feasible, more than one mechanism may be responsible for the development of ureteral endometriosis in a single patient.

Sign and symptoms of ureteral endometriosis are related to the site and degree of obstruction. Ureteral endometriosis can be associated with the classic gynecological symptoms secondary to endometriosis or urological symptoms directly related to the effect of endometrial tissue on the ureter; although, it is more commonly asymptomatic. The classical common presentations of pelvic endometriosis are dyspareunia, dysmenorrhea, pelvic pain and menorrhagia. The incidence of hematuria in patients with ureteral endometriosis is 15% (8). Periodic hematuria, historically regarded as the classic symptom of endometriosis involving the genitourinary tract is commonly seen with intrinsic but also rarely reported with extrinsic ureteral endometriosis (9;13). Acosta et al have reported endometriosis mimicking sigmoid carcinoma associated with ureteral obstruction and hypertension (14).

Several paraclinical tests are used for confirmation of ureteral endometriosis depending on the presenting symptom of patient. Ureteroscopy, transluminal

sonography, laparoscopy, CT-scanning, IVP and pelvic sonography are among the most useful diagnostic modalities. The role of laparoscopy limited to peritoneal and cul-de-sac endometriosis. The best test for internal type ureteral endometriosis is IVP. Intrinsic endometriosis creates a filling defect within the lumen of the ureter, thereby mimicking numerous urological conditions such as radiolucent stones and transitional cell cancer. In addition, IVP provides information regarding renal function and degree of obstructive uropathy. IVP remains a valuable diagnostic tool for ureteral endometriosis, however, the definitive diagnosis of this disease entity will rely on histologic examination of biopsy material of the lesion (5). CT scan also yields equal results and can be used for estimation of the grade of ureter obstruction, although its diagnostic sensitivity for internal endometriosis is limited (5). Most recently, endoluminal ultrasonography was introduced to evaluate ureteropelvic junction obstruction and help avoid crossing vessels during endoscopic treatment of this condition (12).

Therapeutic options are medical therapy, surgery or combination of them. The main goal of therapy is release of ureter stenosis to save normal function of kidney and should be tailored for each patient relative to the extent of disease and degree of stenosis. Medical therapy with the aim of hormonal therapy is indicated for early stage disease, and is not recommended for advanced disease due to the high incidence of recurrence.. Historically, the role of medical therapy has been in the management of residual disease (5).

Surgical therapy can be categorized into minimally invasive and conventional

open surgical treatment options. When the disease is more extensive, it includes total abdominal hysterectomy and bilateral salpingophorectomy with nephrectomy albeit if the kidney is functionless. In the presence of good renal function and less extensive pelvic involvement, only simple release of stenotic ureter is sufficient. Nowadays, minimally invasive procedures such as ureterostomy, laparoscopic ureterolysis and reimplantation can be performed with minimal morbidity (15;16). Finally, combination therapy may be used to minimize the endometriotic mass and help simplify the operation.

Here we described two cases of ureteral endometriosis, both of them with chief complaints of vague abdominal and pelvic pain in a period of at least one year before admission, unfortunately, by the time of diagnosis both of them had severe hydronephrosis.

Open surgical ureterolysis performed for patients because of the fear of malignancy.

Endometriosis of the ureter is an exceptionally rare occurrence that is often diagnosed very late because of the rareness of this situation and its asymptomatic nature. Unfortunately, it may lead to renal function loss. So, in every woman with complaints of pelvic pain, this diagnosis should also be kept in mind and thoroughly searched for. Many diagnostic procedures are now available but the diagnosis of ureteral endometriosis requires a high index of suspicion. An individualized therapeutic plan depending on the patient's age, desire for children, and the extent of the endometriosis foci should be always attempted.

References

1. Vessey MP, Villard-Mackintosh L, Painter R. Epidemiology of endometriosis in women attending family planning clinics. *BMJ* 1993 Jan 16;306(6871):182-4.
2. Dick AL, Lang DW, Bergman RT, Bhatnagar BN, Selvaggi FP. Postmenopausal endometriosis with ureteral obstruction. *Br J Urol* 1973 Apr;45(2):153-5.
3. Ludwig M, Bauer O, Wiedemann GJ, Diedrich K. Ureteric and pulmonary endometriosis. *Arch Gynecol Obstet* 2001 Aug;265(3):158-61.
4. Antonelli A, Simeone C, Zani D, Sacconi T, Minini G, Canossi E, et al. Clinical aspects and surgical treatment of urinary tract endometriosis: our experience with 31 cases. *Eur Urol* 2006 Jun;49(6):1093-7.
5. Comiter CV. Endometriosis of the urinary tract. *Urol Clin North Am* 2002 Aug;29(3):625-35.
6. Abeshouse BS, Abeshouse G. Endometriosis of the urinary tract: a review of the literature and a report of four cases of vesical endometriosis. *J Int Coll Surg* 1960 Jul;34:43-63.
7. Cullen T. Adenomyoma of the tect-vaginal septum. *Bull Johns Hopkins Hosp* 1917;(28):343-9.
8. Klein RS, Cattolica EV. Ureteral endometriosis. *Urology* 1979 May;13(5):477-82.
9. Miller MA, Morgan RJ. Bilateral ureteric obstruction due to endometriosis resulting in unilateral loss of renal function. *Br J Urol* 1990 Apr;65(4):421.
10. Rosemberg SK, Jacobs H. Endometriosis of the upper ureter. *J Urol* 1979 Apr;121(4):512-3.
11. Stanley KE, JR., Utz DC, Dockerty MB. Clinically Significant Endometriosis Of The Urinary Tract. *Surg Gynecol Obstet* 1965 Mar;120:491-8.
12. Takeuchi S, Minoura H, Toyoda N, Ichio T, Hira-no H, Sugiyama Y. Intrinsic ureteric involvement by endometriosis: a case report. *J Obstet Gynaecol Res* 1997 Jun;23(3):273-6.
13. Rock JA, Markham SM. Pathogenesis of endometriosis. *Lancet* 1992 Nov 21;340(8830):1264-7.
14. Acosta S, Leandersson U, Svensson SE, Johnsen J. A case report. Endometriosis caused colonic ileus, ureteral obstruction and hypertension. *Lakartidningen* 2001 May 2;98(18):2208-12.
15. Nezhat C, Nezhat F, Nezhat CH, Nasserbakht F, Rosati M, Seidman DS. Urinary tract endometriosis treated by laparoscopy. *Fertil Steril* 1996 Dec;66(6):920-4.
16. Marcelli F, Collinet P, Vinatier D, Robert Y, Triboulet JP, Biserte J, et al. Ureteric and bladder involvement of deep pelvic endometriosis. Value of multidisciplinary surgical management. *Prog Urol* 2006 Nov;16(5):588-93.