

Original Article

Alport's Syndrome: Ultra-structural Study of 26 Suspected Cases

Isa Jahanzad¹, Sakineh Amoueian², Armin Attaranzadeh²

1. Dept. of Pathology, School of Medicine, Tehran University of Medical Sciences, Tehran, Iran

2. Dept. of Pathology, School of Medicine, Mashhad University of Medical Sciences, Mashhad, Iran

ABSTRACT

Introduction and Objective: Alport's syndrome (hereditary nephritis with deafness) is a familial uncommon disease that ultra-structural studies are gold standard method of its diagnosis.

Materials and Methods: We studied 26 Iranian patients suspicious of Alport's syndrome by electron microscopy. We examined 19 men and 7 women (male to female ratio was 2.7) and the average age was 11.5 years (with a range of 2.5-75 years).

Results: The most common findings were irregularity of the glomerular basement membrane with splitting, lamination, and foot process effacement. Thinning in basement membrane was also reported and one case had disruption of capillary walls in study by only light microscopy. All of the patients had a diagnosis of megansial hypercellularity. Immunoflourscence studies did not show any deposits of immunoglobulin and complement component.

Conclusion: definite diagnosis must be confirmed by ultra-structural findings.

Key words: Ultra-structural, Electron microscopy, Glomerular Basement Membrane, Alport's syndrome

Introduction

Alport's syndrome (AS) is an inherited disease in which affected individuals have hematuria and develop renal failure, often with a sensorineural hearing loss, anterior lenticonus, and dot-and fleck retinopathy. Reports suggest that approximately 85% of patients have x-linked inheritance and rest have an autosomal recessive disease. The diagnosis of AS is suspected when there is a family history of the condition and confirmed when typical clinical features or a lamellated GBM are present (1, 2).

Patients and Methods

In our study, we identified all suspicious cases of Alport's syndrome among the whole patients that referred for EM examination to Cancer Institute of Imam

Khomeini hospital (Tehran, Iran) during 4 years (2001-2005). We reviewed all cases according to age, sex, light microscopic findings, immunoflourscent changes, and electron microscopic abnormality. We compared primary diagnosis by light microscopy with secondary diagnosis by both LM and EM findings.

Unfortunately, because of being a retrospective study and not having complete documents of clinical symptoms and family history, these data were listed in our checklist.

Results

In this study, 26 cases with a diagnosis of Alport's syndrome were selected from all referred patients to Cancer Institute (Imam Khomeini hospital) for 4 years. All patients had hematuria, some proteinuria, and a little chronic renal failure. The youngest patient was 2.5

Received: 24 December 2006

Accepted: 24 January 2007

Address communications to: Dr. Sakineh Amoueian, Department of Pathology, School of Medicine, Mashhad University of Medical Sciences, Mashhad, Iran.

Email: s_amouian@yahoo.com

and the oldest was 75 years old. Meanwhile, 10 cases were in the first decade of their life (2.5-10 years; 38%), 8 patients in the second decade (12-16 years), and only 4 cases were older than 30 years. We examined 19 men and 7 women with a male to female ratio of 2.7.

Renal biopsy specimens were examined. These had been processed routinely for light microscopy, IF, and EM. Light microscopy sections were examined by a histopathologist for glomerular sclerosis, tubulointerstitial abnormalities (atrophy, inflammation, and fibrosis), and arteriosclerosis. Pathologists evaluated light microscopic review with H&E, PAS, trichrom, and Jons staining.

Mild to moderate mesangial hypercellularity was the constant finding in all biopsies. Other findings included mild GBM thickening (2 cases), tubular atrophy (6 cases), segmental sclerosis (1 case), and chronic inflammation in interstitium. In addition, in 2 patients there was foamy cell in interstitium.

Then, pathologist examined electron microscopic sections from paraffin-embedded blocks of specimens. Electron micrographs were examined for width, lamellation, and other Alport's findings. Lamellation was defined as duplication and splitting of lamina densa. Electron microscopic findings included lobal and partial foot process effacement in 21 cases. GBM irregularity in all patients, GBM thinning in 6 cases, and in 2 patients GBM rupture was seen (Figure.1 and Figure .2). There was also GBM splitting and lamination in 23 patients (88%) and 9 cases had basket weave (Figure.3). Visceral epithelial cell and vaculistation appeared in 2 specimens and in 2 biopsies microvilli was reported. Other changes were GBM deposition (mesengial and subendothelial) and tubular basal membrane splitting.

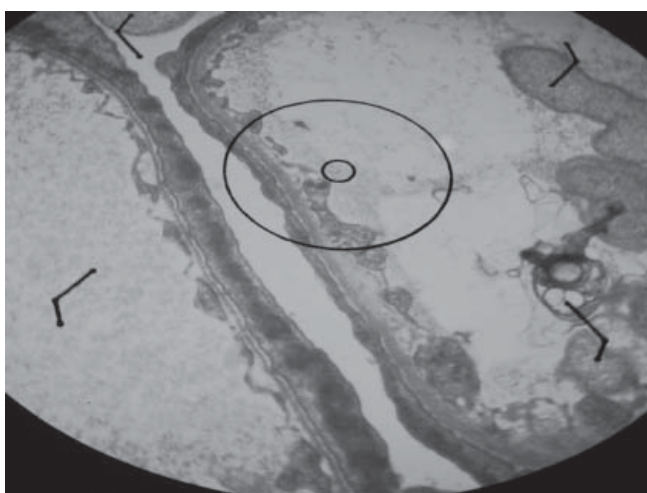


Figure 1. Irregularity and thinning of GBM in EM study




Figure 2. Marked thinning of GBM in one patient

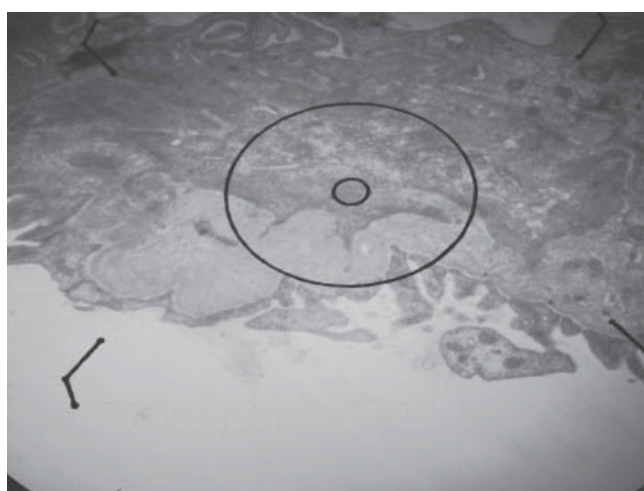


Figure 3. Longitudinal splitting in GBM in EM study

Discussion

Alport's syndrome is an uncommon inherited progressive nephropathy with deafness, ocular defect, or both. In 1927, Alport reported the association of deafness with a form of hereditary familial congenital hemorrhagic nephritis occurring in a family previously observed by Guthrie (1902), then by Hurst (1927) (3). About 80-85% of patients have x-linked inheritance and the rest have autosomal recessive disease (4, 5). It is more severe in males and renal failure develops in the second or less often in the first decade of life (5, 6, 7). It is a genetically heterogenous disease arising from mutations in different genes coding for basement membrane type IV collagen. The gene encode the 5-alpha chain of type IV collagen (alfa 5 (IV)) (3, 8, 9). Familial benign hematuria may represent a benign variant of type IV collagen disease and the heterogenous form of autosomal recessive (5). It is

the differential diagnosis of hematuria variability in clinical presentation and the ultra-structural changes of the glomerulus that can make the diagnosis of the disease as a challenge, especially in female patients (2). In patient with familial hematuria, ultra-structural study of renal biopsy has been the gold standard for the diagnosis of Alport's disease, based on characteristic findings of glomerular basement membrane. Thickening is due to reduplication of the lamina densa (4, 10, 11, 12). But the diagnosis has difficulties since all biopsies from all patients do not have these structural changes. In some patients, especially in women and in children, extensive thinning of basement membrane can be the major abnormality by EM (4, 8, 12, 13, 14).

The purpose of this report was ultra-structural study of Alport's syndrome in Iranian patients. Most of the patients were male (73%). The most common age decades of the disease was the first decade, the same in the world age range which is 2.5-75 years. Light microscopic changes are variable. The most common was mesangial expansion with mild changes or unremarkable findings in tubulointerstitial tissue. In all of the biopsies, the diagnosis was mesangial hypercellularity by only LM studies. Immunofluorescent findings in all patients did not show any depositions of immunoglobulins. The characteristic electron microscopic abnormality in all of our patients was thickening of the glomerular basement membrane with splitting and lamellation of the lamina densa. It is occasionally accompanied by disruption of capillary walls. A few of female and some younger male patients had GBM thinning. Other reports of ultra-structural findings in AS was similar with our final results.

There are many documents about Alport's syndrome clinicopathological correlation with (9) ultra-structural finding (3), and glomerular basement membrane abnormality (8, 10) that all of them confirmed our results. Habib et al (11) showed morphologic features identifiable by electron microscopy that has been described in patients presenting with Alport's syndrome. They are diffuse thickening and splitting of glomerular basement membrane which are either isolated or associated with thinning (16). To conclude, the diagnosis of AS is suspected when there is a family history of the condition, typical clinical features, light microscopic and IF findings, and electron microscopic changes. Without accompanying EM study with LM examination, we can not make a diagnosis of Alport's syndrome.

References

1. Dagher H, Buzza M, Colville D, Jones C, Powell H, Fassett R, et al. A comparison of the clinical, histopathologic, and ultrastructural phenotypes in carriers of X-linked and autosomal recessive Alport's syndrome. *Am J Kidney Dis*. 2001 Dec;38(6):1217-28.
2. Meleg-Smith S, Magliato S, Cheles M, Garola RE, Kashtan CE. X-linked Alport syndrome in females. *Hum Pathol*. 1998 Apr;29(4):404-8.
3. Cosgrove D, Samuelson G, Meehan DT, Miller C, McGee J, Walsh EJ, et al. Ultrastructural, physiological, and molecular defects in the inner ear of a gene-knockout mouse model for autosomal Alport syndrome. *Hear Res*. 1998 Jul;121(1-2):84-98.
4. Battini G, Meroni M, Torri Tarelli L, Sessa A. Ultrastructural lesions of tubular basement membranes and peritubular capillaries in hereditary nephritis. *Contrib Nephrol*. 1990;80:47-55.
5. Gubler MC, Heidet L, Anlignac C. Alport's syndrome in Heptistall's pathology of the kidney, 5th edit, volume 2, 1998 P 1207-22.
6. Meleg-Smith S. Alport disease: a review of the diagnostic difficulties. *Ultrastruct Pathol*. 2001 May-Jun;25(3):193-200.
7. Yum M, Bergstein JM. Basement membrane nephropathy: a new classification for Alport's syndrome and asymptomatic hematuria based on ultrastructural findings. *Hum Pathol*. 1983 Nov;14(11):996-1003.
8. Mazzucco G, Barsotti P, Muda AO, Fortunato M, Mihatsch M, Torri-Tarelli L, et al. Ultrastructural and immunohistochemical findings in Alport's syndrome: a study of 108 patients from 97 Italian families with particular emphasis on COL4A5 gene mutation correlations. *J Am Soc Nephrol*. 1998 Jun;9(6):1023-31.
9. White RH, Raafat F, Milford DV, Komianou F, Moghal NE. The Alport nephropathy: clinicopathological correlations. *Pediatr Nephrol*. 2005 Jul;20(7):897-903.
10. Akhtar M, Al-Sabban E. Alport-like glomerular changes in a patient with nephrotic syndrome: report of a case. *Pediatr Nephrol*. 2000 Sep;14(10-11):973-5.
11. Habib R, Gubler MC, Hinglais N, Noël LH, Droz D, Levy M, et al. Alport's syndrome: experience at Hôpital Necker. *Kidney Int Suppl*. 1982 May;11:S20-8.
12. Prasad RA, Bhatnagar RK, Ratnakar C, Veliath AJ. Alport's syndrome--a case report. *Indian J Pathol Microbiol*. 1996 Jul;39(3):225-7.
13. Bernstein J. The glomerular basement membrane abnormality in Alport's syndrome. *Am J Kidney Dis*. 1987 Sep;10(3):222-9.
14. Spear GS. The pathology of the kidney in the Alport syndrome. *Birth Defects Orig Artic Ser*. 1974;10(4):109-13.