

Case Report

Monoclonal Gammopathy of Undetermined Significance with Metastatic Carcinoma – A Rare Presentation

*Priyanka Joseph Koshy¹, Mijil Anand Justin¹, Meenakshi Vedavyasan²,
Thomas Alexander³, Renu G'Boy Varghese¹*

1.Dept. of Pathology, Pondicherry Institute of Medical Sciences, Pondicherry, India

2.Dept. of Biochemistry, Pondicherry Institute of Medical Sciences, Pondicherry, India

3.Dept. of Gastroenterology, Pondicherry Institute of Medical Sciences, Pondicherry, India

ABSTRACT

The presence of a low level of M protein in the peripheral blood <3mg/dl which is below the required cut off for the diagnosis of plasma cell myeloma is known as monoclonal gammopathy of undetermined significance (MGUS). Elevated levels of serum M protein and detection of M band on serum protein electrophoresis (SPE) can occur in chronic diseases not related to B cell disorders and not always diagnostic for B cell dyscrasias. It can also be seen in non hematological malignancies as seen in our case. We present a case of MGUS in a 59yr male patient, previously diagnosed and surgically treated for carcinoma prostate and colon. Serum electrophoresis revealed an M Band – monoclonal protein of 1.9 mg/dl. Urine for Bence Jones proteins was negative and his skeletal X-rays did not reveal lytic lesions. Bone marrow aspiration revealed metastatic carcinoma. Plasma cells formed 1% of the bone marrow differential count.

Keywords: Monoclonal Gammopathy of Undetermined Significance, Metastasis, Carcinoma

Received: 20 December 2010

Accepted: 27 March 2011

Address communications to: Dr Priyanka Joseph Koshy, Department of Pathology, Pondicherry Institute of Medical Sciences, Pondicherry, India

Email: priyanka@koshy.in

Introduction

Monoclonal Gammopathy of Under-terminated Significance (MGUS) was a term originally coined by Dr Kyle of Mayo Clinic in 1978, around 30 years back(1).

The World Health Organization (WHO) has defined MGUS as the presence in the serum of M-protein <30mg/L, bone marrow (BM) clonal plasma cells <10%, no end organ damage (CRAB: hypercalcemia, renal insufficiency, anemia, bone lesions) and no evidence of B-cell lymphoma or other disease known to produce an M-protein (2).

MGUS denotes the presence of a monoclonal immunoglobulin(Ig), also called M-protein, in the serum or urine in persons without evidence of multiple myeloma (MM), Waldenström macroglobulinemia (WM), amyloidosis (AL) or other lymphoproliferative disorders (3).

MGUS is not considered neoplastic and is found in approximately 3% of persons over 50 yr of age and in more than 5% of individuals past 70 yr. It is more common in men than women (~1.5:1). It is thought to be a precursor to multiple myeloma and other plasma cell dyscrasias (4). However, the etiology of MGUS is not always associated with a plasma cell dyscrasia or a B cell disorder and it has been shown by various studies to be a non specific entity which may be associated with connective tissue disorders, peripheral neuropathies, dermatological, endocrine and liver diseases (2, 5).

MGUS has also been reported in non haematological malignancies like solid tumors of bladder, female genital tract, lung, prostate and gastrointestinal tract (6, 7). In this case report, we present a case in which MGUS was associated with a metastatic adenocarcinoma.

In routine clinical practice, an elevated M protein and M band on electrophoresis is strongly associated with a plasma cell dyscrasia. However in this case report, we would like to suggest that an elevated M protein and M band are non specific findings that are seen in a variety of diseases apart from the conventional association with plasma cell dyscrasias. The importance of this report is to stress on the various other causes of an elevated M band that should be kept in mind before making a diagnosis. Hence, elevated levels of M protein and M band on SPE must be correlated with clinical, biochemical and radiological parameters for a definitive diagnosis.

Case Report

A 59 yr male patient presented with early satiety and increased frequency of stools for a period of two months in 2010. The patient was a known case of carcinoma prostate and carcinoma colon and was treated surgically in 2008. He had a history of weight loss of about 10 kg over three months duration, passing two episodes of loose stools per day and decreased appetite. No history of abdominal pain, hematemesis or melena. No history of fever, cough, back pain or bony tenderness. Patient was a known case of diabetes mellitus and hypertension for 10 yr on regular medication. On examination, patient was pale; vital signs were within normal limits (WNL). Abdominal examination showed a vertical surgical scar in the midline, hepatomegaly and no splenomegaly.

Laboratory investigations were determined follows: hemoglobin: 10.1 mg%; total count: 9800/mm³; erythrocyte sedimentation rate: 105 mm/hr; peripheral smear: normocytic normochromic anemia; S. bilirubin: 0.7mg/dl;

conjugated bilirubin: 0.3mg/dl; unconjugated bilirubin: 0.4mg/dl; total protein: 6.7 mg/dl; serum albumin: 1.5 mg/dl; serum globulin: 5.2 mg/dl; PSA: 2.7; carcinoembryonic antigen (CEA): 4.8; Alpha fetoprotein: 1.2; 24 hr urine protein: 110mg; urine for Bence Jones protein: negative; serum electrophoresis: albumin: 48.3, α_1 - 3.4, α_2 - 6.9, β - 6.9, γ - 34.5 (Fig.1); M Band: 20.7 (contribute 60% of γ globulin) and myeloma protein: 1.9 mg/dl. On skeletal X-ray, no lytic lesions were seen.

Bone marrow aspiration showed metastatic carcinoma (Fig. 2) and plasma cells formed 1% of the bone marrow differential count.

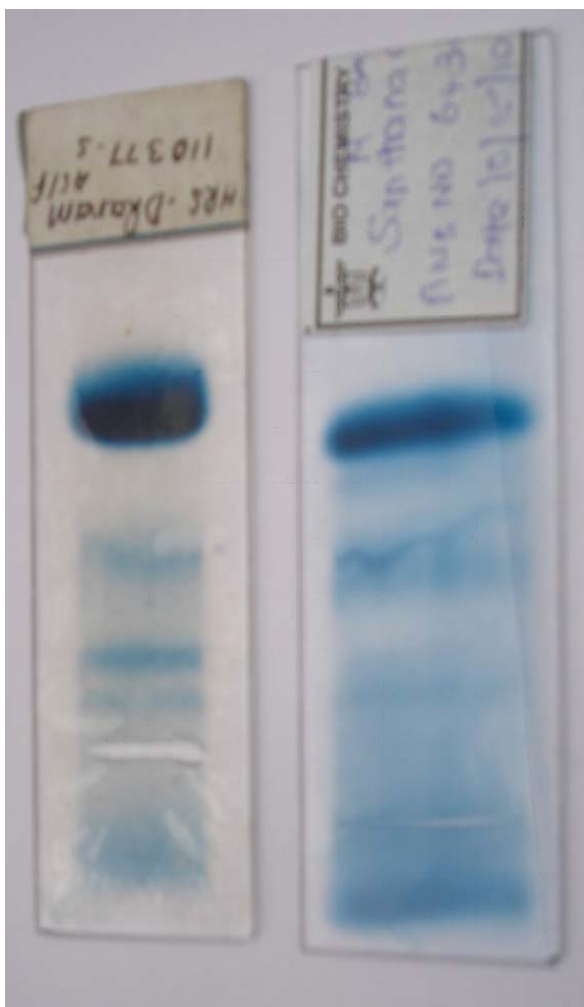


Fig. 1- Serum protein electrophoresis

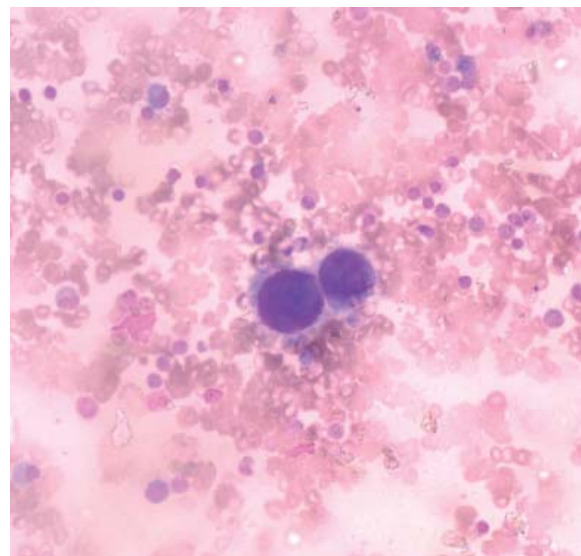


Fig 2: Bone marrow aspiration showing meta-static cells. (Leishman's stain $\times 400$)

Discussion

Monoclonal gammopathy of undertermined significance is characterized by the presence of M protein in the serum of individuals without evidence of multiple myeloma, Waldenström's macroglobulinemia, primary amyloidosis or other lymphoproliferative disorders. MGUS can be seen in various reactive and also neoplastic conditions.

In a case report by Chen and Carroll (8), a patient with carcinoma colon having an IgG-kappa monoclonal peak which within two years after the resection of the carcinoma, the IgG-kappa had completely disappeared. The authors concluded that the disappearance of the monoclonal protein was a response of the immune system to the underlying neoplasm.

Few studies have suggested that M components could be a paraneoplastic phenomenon as they found the occurrence of non-hematological malignancies in 3-16% of patients with monoclonal gammopathy. Association with MGUS has been reported for cancer of the colon, prostate, breast, female genital organs, stomach and lungs (7).

In our study, the M band was probably due to the metastatic adenocarcinoma detected in the bone marrow and could have been a response by the immune system or a paraneoplastic phenomenon as shown by the above studies. To the best of our knowledge, MGUS associated with a metastatic adenocarcinoma has not been reported so far.

The detection of M band is often an incidental finding in a routine work up. (9) Out of the total 1155 samples received during the 3 yrs of study, 282 (24.4%) samples were positive for M component on SPE. These patients presented with features of anemia (7.2%), renal failure (22.7%) and low backache (30.5%). 18.8% of cases which showed positive M band, were cases of benign chronic inflammatory disorders, carcinomas, collagen vascular diseases and gastrointestinal disorders.

In the guidelines given by the UK Myeloma Forum and other studies (10, 11), MGUS could be seen in other clinical situations other than plasma cell dyscrasias such as rheumatoid arthritis, SLE, scleroderma, polymyositis and ankylosing spondylitis. There was also a prevalence of monoclonal gammopathy in patients with hepatitis C virus related chronic liver disease (12). Also, MGUS has been linked to *Helicobacter pylori* infection (13). MGUS is frequent after autologous stem cell transplantation (14) and also following solid organ transplantation (15-17). Hematological associations of MGUS include pernicious anemia, acquired von Willebrand disease, lupus anticoagulant, polycythaemia vera, myelofibrosis, pure red cell aplasia, refractory anemia, congenital dyserythropoietic anemia type III and Gaucher disease. (5)

In our case, the patient had elevated levels of M protein and M band on SPE with bone

marrow metastasis but there was no evidence of Multiple Myeloma or other plasma cell dyscrasias. Elevated levels of M protein and M band on SPE are usually associated with Multiple Myeloma or plasma cell dyscrasias in clinical practice, however, it is not always diagnostic for plasma cell dyscrasias but can also occur in other chronic diseases unrelated to B cell disorders like carcinomas, as seen in our case report and also in aging, chronic reactive conditions and also associated with drug treatment (diphenylhydantoin, sulfonamides, penicillin) as shown by other studies (6-17). In addition, to the best of our knowledge, this case report is the first to show MGUS in a metastatic adenocarcinoma of bone marrow.

Hence, we suggest that elevated levels of M protein and M band on SPE are nonspecific findings and must be correlated with clinical, biochemical and radiological parameters for a definitive diagnosis.

Acknowledgements

The authors declare that there is no conflict of interests.

References

1. Kyle RA. Monoclonal gammopathy of undetermined significance. Natural history in 241 cases. *Am J Med* 1978;64(5):814-26.
2. Swerdlow S, Campo E, Harris N, Jaffe E, Pileri S, Stein H. WHO Classification of Tumors of Haematopoietic and Lymphoid Tissues. 4 th. Lyon: IARC; 2008.
3. Bida JP, Kyle RA, Therneau TM, Melton LJ, III, Plevak MF, Larson DR, *et al.* Disease associations with monoclonal gammopathy of undetermined significance: a population-based study of 17,398 patients. *Mayo Clin Proc* 2009;84(8):685-93.
4. Kyle RA, Therneau TM, Rajkumar SV, Larson DR, Plevak MF, Melton LJ, III. Long-term follow-

up of 241 patients with monoclonal gammopathy of undetermined significance: the original Mayo Clinic series 25 years later. *Mayo Clin Proc* 2004;79(7):859-66.

5. Kyle RA, Rajkumar SV. Monoclonal gammopathy of undetermined significance. *Br J Haematol* 2006;134(6):573-89.

6. Anagnostopoulos A, Galani E, Gika D, Sotou D, Evangelopoulou A, Dimopoulos MA. Monoclonal gammopathy of undetermined significance (MGUS) in patients with solid tumors: effects of chemotherapy on the monoclonal protein. *Ann Hematol* 2004;83(10):658-60.

7. Gregersen H, Mellekjær L, Salling IJ, Sørensen HT, Olsen JH, Pedersen JO, *et al.* Cancer risk in patients with monoclonal gammopathy of undetermined significance. *Am J Hematol* 2000;63(1):1-6.

8. Chen HP, Carroll JA. Monoclonal gammopathy in carcinoma of the colon. *Am J Clin Pathol* 1980;73(4):607-10.

9. Chopra G, Gupta P, Mishra D. Evaluation of Suspected Monoclonal Gammopathies: Experience in a Tertiary Care Hospital. *MJAFI* 2006;(62):134-7.

10. Bird J, Behrens J, Westin J, Turesson I, Drayson M, Beetham R, *et al.* UK Myeloma Forum (UKMF) and Nordic Myeloma Study Group (NMSG): guidelines for the investigation of newly detected M-proteins and the management of monoclonal gammopathy of undetermined significance (MGUS). *Br J Haematol* 2009;147(1):22-42.

11. Hardiman KL, Horn S, Manoharan

A, Phadke K, Gibson J, McGuigan L, *et al.* Rheumatic autoantibodies in the sera of patients with paraproteins. *Clin Exp Rheumatol* 1994;12(4):363-8.

12. Idilman R, Colantoni A, De MN, Alkan S, Nand S, Van Thiel DH. Lymphoproliferative disorders in chronic hepatitis C. *J Viral Hepat* 2004;11(4):302-9.

13. Malik AA, Ganti AK, Potti A, Levitt R, Hanley JF. Role of *Helicobacter pylori* infection in the incidence and clinical course of monoclonal gammopathy of undetermined significance. *Am J Gastroenterol* 2002;97(6):1371-4.

14. Zent CS, Wilson CS, Tricot G, Jagannath S, Siegel D, Desikan KR, *et al.* Oligoclonal protein bands and Ig isotype switching in multiple myeloma treated with high-dose therapy and hematopoietic cell transplantation. *Blood* 1998;91(9):3518-23.

15. Caforio AL, Gambino A, Belloni FA, Piaserico S, Scarpa E, Feltrin G, *et al.* Monoclonal gammopathy in heart transplantation: risk factor analysis and relevance of immunosuppressive load. *Transplant Proc* 2001;33(1-2):1583-4.

16. Radl J, Valentijn RM, Haaijman JJ, Paul LC. Monoclonal gammopathies in patients undergoing immunosuppressive treatment after renal transplantation. *Clin Immunol Immunopathol* 1985;37(1):98-102.

17. Renoult E, Bertrand F, Kessler M. Monoclonal gammopathies in HBsAg-positive patients with renal transplants. *N Engl J Med* 1988;318(18):1205.