

Respiratory Epithelial Adenomatoid Hamartoma: A Very Rare Entity Originating from the External Auditory Canal

Behrouz Shokouhi¹, Parisa Mehrasa^{2*}, Farzad Aslani³

1. Department of Pathology, Alzahra Hospital, Tabriz University of Medical Sciences, Tabriz, Iran
2. Department of Pathology, Emam Reza Hospital, Tabriz University of Medical Sciences, Tabriz, Iran
3. Department of Internal Medicine, Emam Ali Hospital, Tabriz University of Medical Sciences, Tabriz, Iran

ABSTRACT

Scan to discover online



Main Subjects:
Head & Neck Pathology

Received 12 Oct 2019;

Accepted 10 Apr 2020;

Published Online 13 May 2020;

 [10.30699/ijp.2020.94221.1916](https://doi.org/10.30699/ijp.2020.94221.1916)

Respiratory epithelial adenomatoid hamartoma (REAH) is an uncommon lesion of the upper aerodigestive tract. It is characterized by abnormal glandular formations with ciliated epithelium arising from the nasal cavity, paranasal sinuses and nasopharynx, but other locations have also been described. We did not find any other cases of this hamartomas in the external auditory canal in the literature. A 40-year-old man was referred to the otorhinolaryngology department due to otorrhea and decreased hearing from 1 year ago. Oscopic examination showed a reddish hemorrhagic mass in the left external auditory canal. Intraoperatively, the tumor was completely resected. The pathologic findings were consistent with REAH.

KEYWORDS: External Auditory Canal, Hamartoma, Respiratory Epithelial adenomatoid hamartoma

Corresponding Information: Parisa Mehrasa; Department of Pathology, Emam Reza Hospital, Tabriz University of Medical Sciences, Tabriz, Iran Email: ParisaMehrassa@yahoo.com

Copyright © 2020. This is an open-access article distributed under the terms of the Creative Commons Attribution- 4.0 International License which permits Share, copy and redistribution of the material in any medium or format or adapt, remix, transform, and build upon the material for any purpose, even commercially.

Introduction

Hamartomas are tumor-like but non-neoplastic, malformation or inborn errors of tissue development, characterized by an abnormal mixture of indigenous tissue with an excess of one or more of Indigenous tissue (1).

Respiratory epithelial adenomatoid hamartoma is an uncommon lesion of the upper aerodigestive tract (2). It is characterized by abnormal glandular formations with ciliated epithelium arising from the nasal cavity, paranasal sinuses and nasopharynx (3), but other locations have also been described (2).

We did not find any other cases of this hamartomas in the external auditory canal in the literature.

Case Report

A 40-year-old man was referred to the otorhinolaryngology department due to otorrhea and decreased hearing from 1 year ago.

Oscopic examination showed a reddish hemorrhagic mass in the left external auditory canal, without otitis sings. Intraoperatively, the tumor was completely resected.

Histological examinations showed a polypoid lesion composed of numerous glands lined by several layers of bland ciliated respiratory epithelium and surrounded by a thick collagenized basement membrane (Figures 1 and 2). The glands were round to oval and varied in size from small to large and cystically dilated. The glandular lumina contained mucinous or amorphous material (Figure 3). Frequent areas of mucous metaplasia were seen. The stroma was edematous and contained mixed inflammatory cells (Figure 4). The pathologic findings were consistent with REAH.

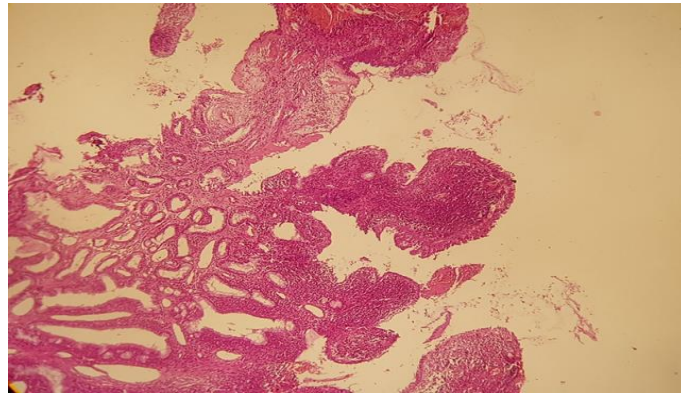


Fig. 1. The glands are lined by ciliated respiratory epithelium. The nuclei are bland.

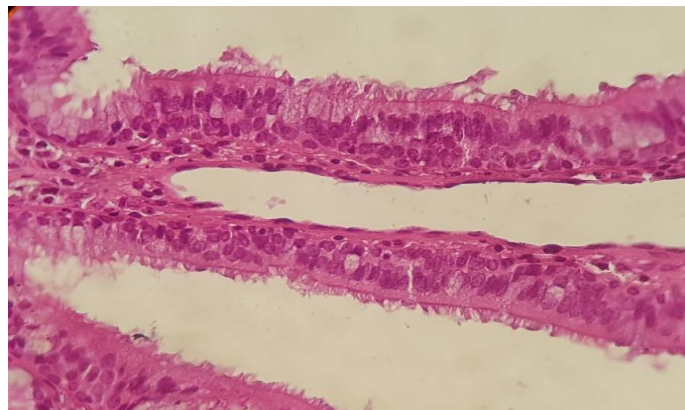


Fig. 2. The glands are lined by ciliated respiratory epithelium. The nuclei are bland.

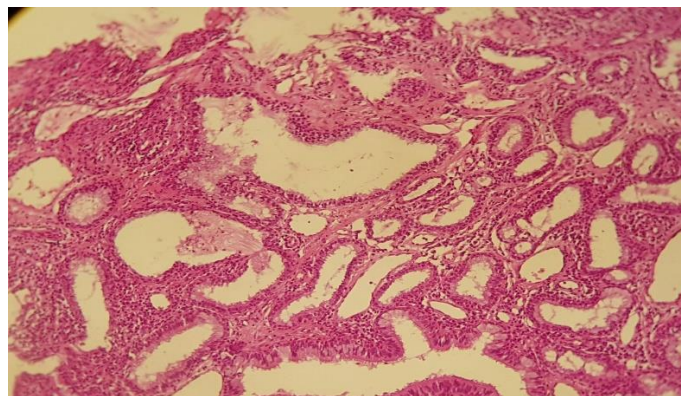


Fig. 3. The dilated glands, containing mucinous or amorphous material.

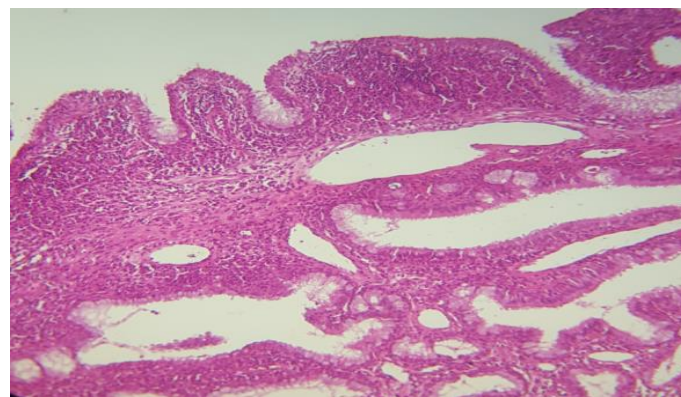


Fig. 4. Polypoid appearance with numerous glands and inflamed stroma

Discussion

Respiratory epithelial adenomatoid hamartoma (REAH) was first reported in a series of 31 cases by Wening and Heffner in 1995 (4). Approximately 70% of REAH present in the nasal cavity, especially in the posterior part of nasal septum. Besides, nasopharynx, ethmoid, frontal and maxillary sinuses could be involved (3). Until now, no case was reported in the external auditory canal.

Grossly, REAH is a variable size polypoid rubbery to firm mass with glistening yellow to white cut surface (2). Histologically, it is characterized by submucosal glandular proliferation. The glands are lined by bland-looking ciliated respiratory epithelium and are surrounded by a thick collagenized basement membrane (2). Differentiation of these tumor from other aggressive tumors is important (5).

The main differential diagnosis in external auditory canal are ceruminous adenocarcinoma and adenoid cystic carcinoma (6).

Ceruminous adenocarcinoma, microscopically, characterized by variously sized glandular formations arranged in back to back proliferation and lined by apocrine cells (7). Presence of more than occasional mitotic activity, pleomorphism, the absence of a myoepithelial layer, necrosis and invasiveness are the main diagnostic features (8).

Adenoid cystic carcinoma is diagnosed by pseudocysts and true glandular structures with cribriform pattern. The glands are lined by a monolayer of eosinophilic epithelial cells with scant cytoplasm and hyperchromatic angulated nuclei (9). Perineural invasion is the main diagnostic clue (10).

The other differential diagnosis is inflammatory aural polyp, which is characterized by squamous or ciliated cells epithelium with mixed inflammatory cells infiltrations and granulation tissue formation, but no glandular structures are seen (11).

Conclusion

REAH is an uncommon lesion of the upper aerodigestive tract, but until now, no case was reported in the external auditory canal. The main differential diagnosis in the external auditory canal are ceruminous adenocarcinoma and adenoid cystic carcinoma. Therefore, the rule out of this differential diagnosis will aid in determining the best treatment protocol.

Acknowledgements

The authors would like to express gratitude towards all who helped in the improvement of this paper.

Conflict of Interest

The authors declared that there is no conflict of interest regarding the publication of this article.

References

1. Kacker K, Dasgupta G. Hamartomas of ear and nose. The Journal of Laryngology & Otology. 1973 Aug;87(8):801-5. [DOI:10.1017/S002221510007763X] [PMID]
2. Fitzhugh VA, Mirani N. Respiratory epithelial adenomatoid hamartoma: a review. Head and neck pathology. 2008 Sep 1;2(3):203. [DOI:10.1007/s12105-008-0064-3] [PMID] [PMCID]
3. Jurado FX, Toste JM, Alobid I, Alós L, i Miret JM. The importance of the differential diagnosis in rhinology: respiratory epithelial adenomatoid hamartoma of the sinonasal tract. Acta Otorrinolaringologica (English Edition). 2012 Jan 1;63(1):55-61. [DOI:10.1016/j.otoeng.2010.12.006]
4. Wenig BM, Heffner MC, USN CD. Respiratory epithelial adenomatoid hamartomas of the sinonasal tract and nasopharynx: a clinicopathologic study of 31 cases. Annals of Otology, Rhinology & Laryngology. 1995 Aug;104(8):639-45. [DOI:10.1177/000348949510400809] [PMID]
5. Sangoi AR, Berry G. Respiratory epithelial adenomatoid hamartoma: diagnostic pitfalls with emphasis on differential diagnosis. Adv Anatom Pathol. 2007 Jan 1;14(1):11-6. [DOI:10.1097/PAP.0b013e31802efb1e] [PMID]
6. Devaney KO, Boschman CR, Willard SC, Ferlito A, Rinaldo A. Tumours of the external ear and temporal bone. The Lancet Oncology. 2005 Jun 1;6(6):411-20. [DOI:10.1016/S1470-2045(05)70208-4]
7. Cankar V, Crowley H. Tumors of ceruminous glands. Cancer. 1964 Jan;17(1):67-75. https://doi.org/10.1002/1097-0142(196401)17:1<67::AID-CNCR2820170109>3.0.CO;2-A [DOI:10.1002/1097-0142(196401)17:13.0.CO;2-A]
8. Nelson, B.L., Thompson, L.D.R. and Barnes, L., 2003, January. Ceruminous gland carcinomas: A clinicopathologic study of 17 cases. In LABORATORY INVESTIGATION (Vol. 83, No. 1, pp. 221A-221A). 530 WALNUT ST, PHILADELPHIA, PA 19106-3621 USA: LIPPINCOTT WILLIAMS & WILKINS.
9. Hoshino M, Yamamoto I. Ultrastructure of adenoid cystic carcinoma. Cancer. 1970 Jan;25(1):186-98. https://doi.org/10.1002/1097-0142(197001)25:1<186::AID-CNCR2820250127>3.0.CO;2-H [DOI:10.1002/1097-0142(197001)25:13.0.CO;2-H]
10. Kowalski PJ, Paulino AF. Perineural invasion in adenoid cystic carcinoma: Its causation/promotion by brain-derived neurotrophic factor. Human pathology. 2002 Sep 1;33(9):933-6. [DOI:10.1053/hupa.2002.128249] [PMID]
11. Thompson LD. Otic polyp. Ear, Nose & Throat Journal. 2012 Nov;91(11):474-5. [DOI:10.1177/014556131209101106] [PMID]

How to Cite This Article

Shokouhi, B., Mehra, P., Aslani, F. Respiratory Epithelial Adenomatoid Hamartoma: A Very Rare Entity Originating from the External Auditory Canal. *Iranian Journal of Pathology*, 2020; 15(3): 256-258. doi: 10.30699/ijp.2020.115463.2255