

Application and Assessment of Allogeneic Fibroblasts for Cell Therapy

Seyedeh Mehrnaz Kouhbananejad¹, Farzaneh Armin¹, Shahriar Dabiri², Ali Derakhshani^{3,2},
Maryam Iranpour², Alireza Farsinejad^{4,1,5*}

1. Dept. of Hematology and Laboratory Sciences, Faculty of Allied Medical Sciences, Kerman University of Medical Sciences, Kerman, Iran
2. Pathology and Stem Cell Research Center, Kerman University of Medical Sciences, Kerman, Iran
3. Research Center for Hydatid Disease in Iran, Kerman University of Medical Sciences, Kerman, Iran
4. Cell Therapy and Regenerative Medicine Comprehensive Center, Kerman University of Medical Sciences, Kerman, Iran
5. Physiology Research Center, Institute of Basic and Clinical Physiology Sciences, Kerman University of Medical Sciences, Kerman, Iran

KEYWORDS

Fibroblast,
Allogeneic,
Immune system,
Wound healing

Article Info

Received 28 March 2017;
Accepted 13 Sep 2018;
Published Online 25 Sep 2018;

ABSTRACT

Background and Objective: In recent years, due to increasing number of patients with non-healing skin ulcers, skin substitutes have been used. Skin substitutes contain living cells causing faster and more effective wound healing. Therefore, research on the use of autologous and allogeneic cells such as fibroblasts in skin substitutes has attracted attentions. However, there are discrepancies in the immune responses to allogeneic fibroblasts. Therefore, we aimed to review the immune responses to allogeneic fibroblasts.

Methods: Donor fibroblasts were isolated from the skin of three rats. Nine recipient rats which were subcutaneously injected with three different regimens, were divided into three groups: Group 1; phosphate buffered saline (PBS) without cells (control), group 2: allogeneic fibroblasts of one animal source suspended in phosphate buffered saline, and group 3; phosphate buffered saline containing mixed allogeneic fibroblasts of three animal sources. The skin samples were biopsied at 1, 3 and 7 days after injection and studied histopathologically.

Results and Conclusion: No signs of redness and edema were observed in the injection sites. In pathology examination, changes such as vasculitis, eosinophils and lymphocytes accumulation around fibroblasts, fibroblast apoptosis and transplant rejection at the injection site were not observed in either group.

Subcutaneous injection of allogeneic fibroblasts in rats can be introduced as a promising approach for wound healing as they do not stimulate the immune system.

Corresponding information:

Alireza Farsinejad; Cell Therapy and Regenerative Medicine Comprehensive Center, Kerman University of Medical Sciences, Kerman, Iran; E-mail: farsinezhad239@yahoo.com

Copyright © 2018, IRANIAN JOURNAL OF PATHOLOGY. This is an open-access article distributed under the terms of the Creative Commons Attribution-non-commercial 4.0 International License which permits copy and redistribute the material just in noncommercial usages, provided the original work is properly cited.

Introduction

In recent years, the number of patients who suffer from difficult-to-heal wounds such as surgical wounds, extensive burns and diabetic ulcers has been increased (1). During the process of wound healing, dressings are often used for tissue repair of dermis and epidermis (2). Over the years, the wound dressings have been developed from animal fat, honey

and plant herbs to tissue-engineered scaffolds (3, 4). There are two main types of wound dressings including traditional wound dressings (gauzes, plasters, lint and cotton wool), and modern wound dressings (foams, films, hydrogels, bioactive dressings and hydrocolloids) (3, 5, 6). In general, these dressings are derived from natural tissues or artificial sources such as collagen (7), glycosaminoglycans (8), chitosan (9), curcumin-loaded poly (lactic-co-glycolic) acid nano-

fiber etc. (10). Tissue-engineered skin substitutes have recently been developed (5, 11, 12).

The first living bilayered skin substitute was created by Bell et al. (13). Then attempts began to produce new skin substitutes to help healing wounds, and eventually, faster skin regeneration (14). Many researchers believe that wound healing with skin substitutes containing living cells is faster and supreme and takes less fibrosis (15). In this way, cultured autologous epidermal cells have been used for more than two decades for the treatment of extensive burns (16). Although this technique accelerates wound healing in the patients with extensive burns, it faces some challenges including the creation of second wound for cell separation, long-term proliferation of patient cells and the absence of dermal components. To overcome these obstacles, the use of skin cells like fibroblasts is getting more popular (1, 17). Fibroblasts in skin substitutes play a role in producing extracellular matrix (ECM) and growth factors, which provide a suitable environment for epidermis formation and wound healing (18, 19). However, these cells induce chemokine production that can cause activation and recruitment of neutrophils into the damaged area, which eventually exacerbates wound infection. These events also accelerate the keratinocyte migration into the wound and re-epithelialization of the wound (20). Even though the use of fibroblasts is significantly contributed to dermis formation but as previously mentioned, challenges of cultured autologous cells are still the major barriers to the widespread use of these cells (1). Therefore, the researchers have studied the use of allogeneic fibroblasts (14). Transplantation of allogeneic cells causes some problems such as immune response of recipient, transplant rejection, viral infection etc. The reaction and its severity depend on various factors such as the number of transplanted cells, its immunophenotypes structure, transplantation site and the species. There are also conflicting reports on the immune system responses against fibroblasts. The aim of this study was to assess the effect of allogeneic fibroblasts on the immune responses in rats.

Materials and Methods

Culture and proliferation of rat dermal fibroblasts

Three Wistar male rats weighing 160-200 g were used as donors for fibroblasts isolation and culture. This study was approved by the Ethics Committee of Kerman University of Medical Sciences, Kerman. Animals were given intraperitoneal injections of Ketamine (100 mg/kg) and Xylazine (10 mg/kg) and anesthetized. Back of the rats was shaved and the skin was disinfected by Povidone-iodine and 75% alcohol solution. Then, a sterile biopsy punch (3 mm) was taken from each animal and washed three times with PBS containing antibiotics. The epidermis was separated from the dermis. The dermis was divided into pieces smaller than 1 mm and incubated with collagenase type II enzyme for 30 min at 37°C in 5% CO₂. Digested skin patches were individually cultured in 60 mm sterile plate containing MEM- α medium, 20% FBS, 100 U/ml penicillin and 100 μ g/ml streptomycin. The medium was routinely changed every 3 days. After a week, spindle-shaped fibroblasts were observed by inverted microscope in radial arrangements surrounding the tissue. Fibroblasts which reached suitable confluency were sub-cultured using trypsin.

Subcutaneous fibroblasts injection

Nine Wistar male rats weighing 200-250 g were used as the cell recipients. Animals were subcutaneously injected with fibroblasts according to the rules of Ethics Committee of Kerman University of Medical Sciences. The animals divided into 3 groups were subcutaneously injected with three different regimens (3 rats in each group): Group 1: PBS without cells (control); group 2: allogeneic fibroblasts of one animal source suspended in PBS; and group 3: PBS containing mixed allogeneic fibroblasts of three animal sources. Cultured fibroblasts from donor rats were isolated by trypsin in passage three at 80% confluency and suspended in PBS. After shaving the dorsal skin of rats in each group, the solutions (2×10^6 cells/ml of PBS) were injected subcutaneously. On days 1, 3 and 7 post-injection, the appearance of injection site were examined for signs of swelling, redness and in-

flammation. The skin samples were also biopsied for histopathological changes and comparison between the groups. In this study, the following pathological responses were assessed: immune cells accumulation, eosinophils accumulation, fibroblasts apoptosis and vasculitis.

Fluorescent staining for cell tracking

The fluorescent tracking dye [Cell Tracker™ CM-Dil (C7000)] was used to label and track the injected fibroblasts. Stock solution was prepared in dimethyl sulfoxide at 1–2 mg/ml. The working solution (1 μ M) was prepared from stock solution diluted with Dulbecco's phosphate-buffered saline (DPBS) immediately before labeling. Then, 5 μ l of labeling solution was added to 1 ml medium and incubated for 5 min at 37°C, and then for 15 min at 4°C. Afterwards, the cells were washed with PBS and resuspended in fresh medium.

Immunocytochemical staining

The isolated cells were cultured on the slide for 24 hr. Then, the slide was fixed with acetone-methanol and placed in the microwave oven into the buffer (pH=9) for 10 min. After cooling at room temperature and washing with Tris-Borate-EDTA (TBE) buffer, the hydrogen peroxide was shed on the slide. Following 5 min incubation and washing, 100 μ l Vimentin was shed on the slide and it was placed in the moisture for 1 hr. Then, secondary antibody was added and the slide was washed after 30 min and diaminoperoxidase (chromogenic) was added. Then, the slide was rinsed with tap water. For nuclear staining, Hematoxylin color was used. The slide was dehydrated in ascending grades of alcohol, cleared in xylene then mounted.

Histopathological assessment

The skin samples were biopsied at 1, 3 and 7 days after injection. The samples were fixed in 10% formalin for 24 hr, and dehydrated through rising alcohol grades, cleared in xylene and soaked in paraffin. Tissue sections (3 μ m) were made from paraffin blocks. Then, the sections were stained for histopathological evaluation using Hematoxylin and Eosin (H&E).

Results & Discussion

Spindle-shaped fibroblasts isolated from the skin of donor rats were monitored in the primary cell culture by inverted microscope. Fibroblasts surrounded the nutrient tissue radially (Figure 1). Vimentin-stained fibroblasts were observed in brown color (Figure 2).

A skin tissue section that was subcutaneously injected with fluorescent fibroblasts was observed by fluorescent microscope. The red fluorescent fibroblasts were observed on black background (Figure 3). Gross finding of injected site showed no signs of redness and edema in the groups in different days.

Histopathological changes were evaluated by H&E staining in each group. Group 1 (control) at day one showed intact epidermis and stromal edema in the dermis. At day three, this group showed intact epidermis but dermal edema decreased. At day seven, scattered edema and small collection of mast cells were observed (Figure 4; A-C).

Group 2 at day one showed hyperkeratosis of the epidermis. In the papilla, focal accumulation of fibroblasts as 5-10 cells/HPF (high power field) were observed, which some of them were spindle-shaped and some were wrinkle-shaped cells. At day three, intact epidermis, more fibroblast accumulation (10-15 cells/HPF) and lymphocytes in small numbers and scattered were observed. At day seven, also intact epidermis and fibroblasts with lower density (<5 cells/HPF) were observed as a cluster. Lymphocytes were a bit more focally aggregated, but no transplant rejection was observed (Figure 4; D-F).

Observations in group 3 at days 1, 3 and 7 after the injection were similar to those in group 2 and fibroblasts were spindle-shaped and active on day 7 (Figure 4; G-I).

In groups 2 and 3 which were injected with allogeneic cells, transplant rejection reactions such as vasculitis, eosinophils accumulation, lymphocytes accumulation around fibroblasts and fibroblast apoptosis were not observed.

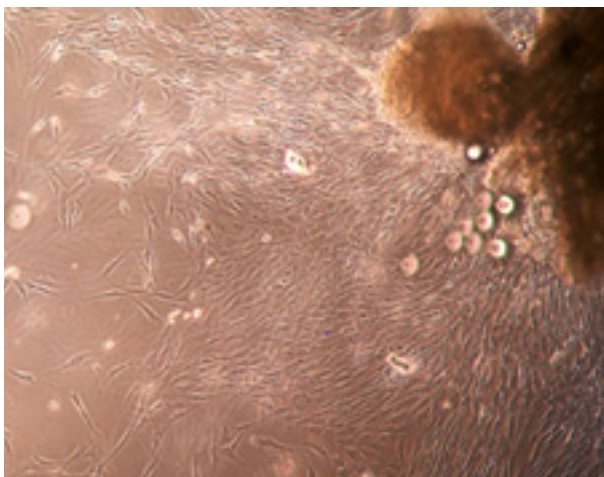


Figure 1. Fibroblasts isolated from skin of the rats

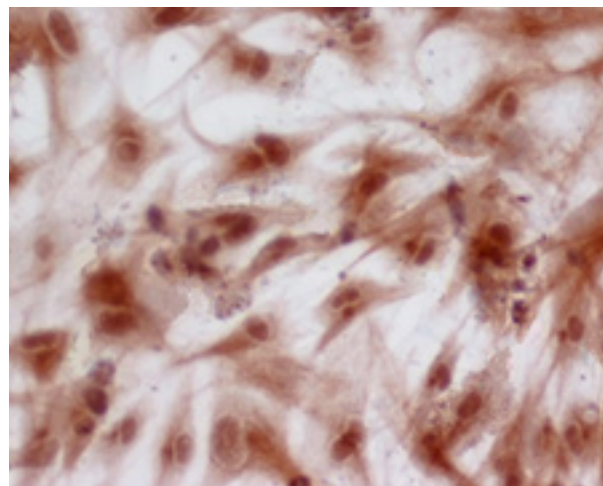


Figure 2. Vimentin-stained fibroblasts

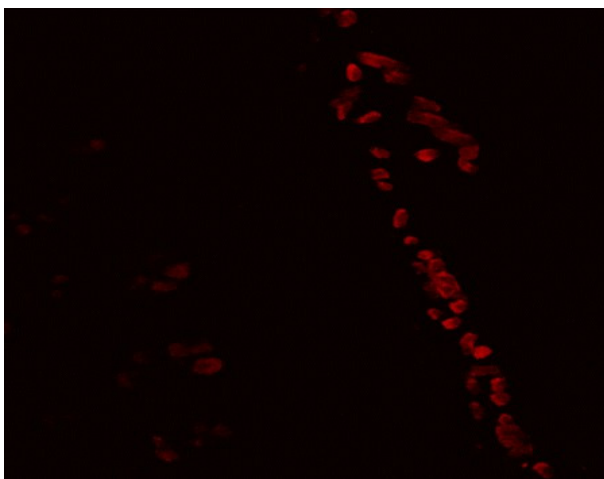


Figure 3. Fluorescent microscope image of the red fluorescent fibroblasts in the section of rat skin

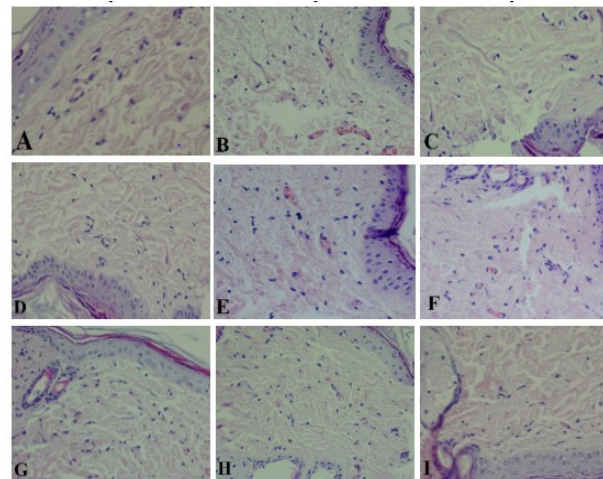


Figure 4. H & E stained sections on days 1 (A, D, G), 3 (B, E, H) and 7 (C, F, I). Group 1: control (A-C); group 2: allogeneic cells of one animal source (D-F); group 3: allogeneic cells of three animal sources (G-I). (400× magnification)

So far, treatment methods for deep dermal and full thickness wounds have not been satisfactory thus, more effective treatment strategies are needed. For this purpose, skin substitutes have been studied. Skin substitutes accelerate the wound healing process using normal repair mechanism of the body and prevent bacterial infections (21). Over the years, researchers have found that skin substitutes contain living cells causing faster and desirable wound healing. Therefore, research on the use of autologous and allogeneic cells in the skin substitutes has begun (1, 15). Several studies have tested different animals including mice, rats, dogs and pigs.

In this study, fibroblasts were isolated from 3 donor rats, cultured and suspended in PBS. Then PBS or allogeneic cell suspensions were subcutaneously injected to the animals of three groups and the animals were examined over seven days. The injection sites showed no signs of redness and edema in the groups. Pathological studies showed that in groups 2 and 3, only a few lymphocytes were spread on the skin on days 3 and 7 and did not aggregate around fibroblasts compared with those in group 1. Also no significant signs of immune response and transplant rejection reactions were observed.

In allogeneic fibroblast groups, eosinophils accumu-

lation in the injection site, lymphocytes aggregation around fibroblasts, fibroblast apoptosis and immune response such as vasculitis were not observed (2, 3). In this regard, Revi et al. used co-culture of allogeneic keratinocytes and fibroblasts on chitosan scaffold for wound healing in rabbits. The results showed better healing and less scar formation, therefore, this therapeutic graft was suggested to be useful for healing of wounds such as burns where dermis layer is totally destroyed (22). It was also revealed that these cells did not cause inflammatory reactions and transplant rejection, which is consistent with the results of this study. Reagan et al. compared acellular and cellular allogeneic skin grafts. They found out that cellular allogeneic graft induced severe inflammatory response which was likely against epithelial follicular elements rather than fibroblasts or extracellular matrix. However, no transplant rejection reaction was observed, which worsened the cosmetic results (23). Although this study was conducted on different animals, no immune response against allogeneic fibroblasts and no transplant rejection reaction were observed, which is consistent with the results of the current study. In previous studies, autologous fibroblasts have also been used. Mahmoodi Rad et al. used autologous co-culture of keratinocytes and fibroblasts on collagen scaffold for wound healing in rats. The results showed improved wound healing in the experimental group compared to that in the control group. Lack of transplant rejection reaction and no risk of infection were mentioned for using autologous cells (24). Because of the discrepancies in the use of autologous and allogeneic cells, the authors of this study decided to review the immune response to allogeneic fibroblasts. In this regard, Evert et al. studied induction of inflammation and scar formation by autologous and allogeneic fibroblasts in skin substitutes using a porcine wound model. They used autologous fibroblasts for control group, and allogeneic fibroblasts isolated from the skin of three donor pigs with two different (high and low) genetic similarities with the recipient pig for allogeneic groups. The results showed that allogeneic fibroblasts were recognized by lymphocytes and stimulated the immune response in allogeneic groups,

whereas no immune response in the control group was observed. However, the immune response to allogeneic fibroblasts was variable. The highest response was against allogeneic fibroblasts with low genetic similarity with recipient, and the least reaction was against allogeneic fibroblasts with high genetic similarity with recipient (14), which is inconsistent with the results of this study. This study was conducted on pigs and differences in the immune system of different animals may have yielded different results. Also, the skin graft may be another factor stimulating the immune system. For this reason, we injected fibroblasts subcutaneously to counteract other factors that may stimulate the immune system. Also, in this study, three different pigs were used for fibroblasts isolation to measure the effect of genetic similarity on the activity of the immune system. In this study, the highest reactions were observed in recipient pigs with low genetic similarity that it could explain the discrepancies between the results. For more antigenic challenge of the rat immune system, we used fibroblasts derived from three animal sources of the same breed. However, no significant differences were reported in the immune response between groups 2 and 3. Thus, it can be concluded that subcutaneous injection of allogeneic fibroblasts does not stimulate the immune system response and transplant rejection significantly.

Our findings showed no signs of allogeneic fibroblasts rejection in rats. Therefore, it seems that allogeneic fibroblasts can be used for wound healing especially in cases where there is no possibility of using autologous fibroblasts. Such wounds are burn wounds where autologous cells are difficult to culture, and/or diabetic ulcers where creation of another wound is a complicated phase.

Conclusion

According to this study, allogeneic fibroblasts do not stimulate immune responses and transplant rejection in rats. It seems that these cells can be used to help wound healing, particularly in cases such as diabetic ulcers and burns.

Acknowledgment

The authors would like to gratitude Dr. Sara Samiee

for her valuable comments. Special thanks to Mrs. Ziasistani and Sheykhshoai from Pathology and Stem Cell Research Center, Kerman University of Medical sciences, Kerman for their excellent technical assistance.

References

- Zuliani T, Saiagh S, Knol AC, Esbelin J, Dréno B. Fetal fibroblasts and keratinocytes with immunosuppressive properties for allogeneic cell-based wound therapy. *PloS one*. 2013; 8(7): e70408. <https://doi.org/10.1371/journal.pone.0070408> PMID: [23894651](https://pubmed.ncbi.nlm.nih.gov/23894651/)
- Mogoşanu GD, Grumezescu AM. Natural and synthetic polymers for wounds and burns dressing. *Int J Pharm*. 2014; 463(2):127-36. <https://doi.org/10.1016/j.ijpharm.2013.12.015> PMID: [24368109](https://pubmed.ncbi.nlm.nih.gov/24368109/)
- Boateng JS, Matthews KH, Stevens HN, Eccleston GM. Wound healing dressings and drug delivery systems: a review. *J Pharm Sci*. 2008; 97(8):2892-923. <https://doi.org/10.1002/jps.21210> PMID: [17963217](https://pubmed.ncbi.nlm.nih.gov/17963217/)
- Mahboob Morshed NIA, Chowdhury S, Ruzzymah B. The current available biomaterials being used for skin tissue engineering. *Regenerative Research*. 2014; 3(1):17-22.
- Dhivya S, Padma VV, Santhini E. Wound dressings-a review. *BioMedicine*. 2015; 5(4):22. <https://doi.org/10.7603/s40681-015-0022-9> PMID: [26615539](https://pubmed.ncbi.nlm.nih.gov/26615539/)
- Strecker-McGraw MK, Jones TR, Baer DG. Soft tissue wounds and principles of healing. *Emerg Med Clin North Am*. 2007; 25(1):1-22. <https://doi.org/10.1016/j.emc.2006.12.002> PMID: [17400070](https://pubmed.ncbi.nlm.nih.gov/17400070/)
- Murali R, Anumary A, Ashokkumar M, Thanikaivelan P, Chandrasekaran B. Hybrid biodegradable films from collagenous wastes and natural polymers for biomedical applications. *Waste and Biomass Valorization*. 2011; 2(3):323-335. <https://doi.org/10.1007/s12649-011-9072-8>
- Salbach J, Rachner TD, Rauner M, Hempel U, Anderegg U, Franz S, et al. Regenerative potential of glycosaminoglycans for skin and bone. *J Mol Med*. 2012; 90(6):625-35. <https://doi.org/10.1007/s00109-011-0843-2> PMID: [22187113](https://pubmed.ncbi.nlm.nih.gov/22187113/)
- Ishihara M, Nakanishi K, Ono K, Sato M, Kikuchi M, Saito Y, et al. Photocrosslinkable chitosan as a dressing for wound occlusion and accelerator in healing process. *Biomaterials*. 2002; 23(3):833-40. [https://doi.org/10.1016/S0142-9612\(01\)00189-2](https://doi.org/10.1016/S0142-9612(01)00189-2) PMID: [11771703](https://pubmed.ncbi.nlm.nih.gov/11771703/)
- Nguyen TTT, Ghosh C, Hwang S-G, Dai Tran L, Park JS. Characteristics of curcumin-loaded poly (lactic acid) nanofibers for wound healing. *Journal of Materials Science*. 2013; 48(20):7125-7133. <https://doi.org/10.1007/s10853-013-7527-y>
- Ahmed TA, Dare EV, Hincke M. Fibrin: a versatile scaffold for tissue engineering applications. *Tissue Eng Part B Rev*. 2008; 14(2):199-215. <https://doi.org/10.1089/ten.teb.2007.0435> PMID: [18544016](https://pubmed.ncbi.nlm.nih.gov/18544016/)
- Metcalf AD, Ferguson MW. Tissue engineering of replacement skin: the crossroads of biomaterials, wound healing, embryonic development, stem cells and regeneration. *J R Soc Interface*. 2007; 4(14):413-37. <https://doi.org/10.1098/rsif.2006.0179> PMID: [17251138](https://pubmed.ncbi.nlm.nih.gov/17251138/)
- Bell E, Ehrlich HP, Buttle DJ, Nakatsuji T. Living tissue formed in vitro and accepted as skin-equivalent tissue of full thickness. *Science*. 1981; 211(4486):1052-4. <https://doi.org/10.1126/science.7008197> PMID: [7008197](https://pubmed.ncbi.nlm.nih.gov/7008197/)
- Lamme EN, Van Leeuwen RT, Mekkes JR, Middelkoop E. Allogeneic fibroblasts in dermal substitutes induce inflammation and scar formation. *Wound Repair Regen*. 2002; 10(3):152-60. <https://doi.org/10.1046/j.1524-475X.2002.10901.x> PMID: [12100376](https://pubmed.ncbi.nlm.nih.gov/12100376/)
- Zaulyanov L, Kirsner RS. A review of a bilayered living cell treatment (Apligraf) in the treatment of venous leg ulcers and diabetic foot

Conflict of Interest

The authors declare that there is no conflict of interest regarding the publication of this article.

- ulcers. *Clin Interv Aging*. 2007; 2(1):93-8.
16. Gallico III GG, O'Connor NE, Compton CC, Kehinde O, Green H. Permanent coverage of large burn wounds with autologous cultured human epithelium. *N Eng J Med*. 1984; 311:448-451. <https://doi.org/10.1056/NEJM198408163110706> PMID: [6379456](https://pubmed.ncbi.nlm.nih.gov/6379456/)
 17. Ronfard V, Rives J-M, Neveux Y, Carsin H, Barrandon Y. Long-term regeneration of human epidermis on third degree burns transplanted with autologous cultured epithelium grown on a fibrin matrix 1, 2. *Transplantation*. 2001; 70(11):1588-98. <https://doi.org/10.1097/00007890-200012150-00009> PMID: [11152220](https://pubmed.ncbi.nlm.nih.gov/11152220/)
 18. Wong T, McGrath J, Navsaria H. The role of fibroblasts in tissue engineering and regeneration. *Br J Dermatol*. 2007; 156(6):1149-55. <https://doi.org/10.1111/j.1365-2133.2007.07914.x> PMID: [17535219](https://pubmed.ncbi.nlm.nih.gov/17535219/)
 19. Xia F, Liang Hp. Circulating fibrocytes: a potent cell population in antigen-presenting and wound healing. *Chin J Traumatol*. 2010; 13(2):111-6. PMID: [20356448](https://pubmed.ncbi.nlm.nih.gov/20356448/)
 20. Mansbridge J. Commercial considerations in tissue engineering. *J Anat*. 2006; 209(4):527-532. <https://dx.doi.org/10.1111%2Fj.1469-7580.2006.00631.x> PMID: [17005024](https://pubmed.ncbi.nlm.nih.gov/17005024/)
 21. Gomathysankar S, Halim AS, Yaacob NS. Proliferation of keratinocytes induced by adipose-derived stem cells on a chitosan scaffold and its role in wound healing, a review. *Arch Plast Surg*. 2014; 41(5):452-7. <https://doi.org/10.5999/aps.2014.41.5.452> PMID: [25276634](https://pubmed.ncbi.nlm.nih.gov/25276634/)
 22. Revi D, Paul W, Anilkumar T, Sharma CP. Chitosan scaffold co-cultured with keratinocyte and fibroblast heals full thickness skin wounds in rabbit. *J Biomed Mater Res A*. 2014; 102(9):3273-81. <https://doi.org/10.1002/jbma.35003> PMID: [24133040](https://pubmed.ncbi.nlm.nih.gov/24133040/)
 23. Reagan BJ, Madden MR, Huo J, Mathwich M, Staiano-Coico L. Analysis of cellular and decellular allogeneic dermal grafts for the treatment of full-thickness wounds in a porcine model. *J Trauma*. 1997; 43(3):458-66. <https://doi.org/10.1097/00005373-199709000-00012> PMID: [9314308](https://pubmed.ncbi.nlm.nih.gov/9314308/)
 24. Mahmoodi Rad M, Dehghani F, Mirzaei M, Ghasemi M, Mosafa N. Investigating the effect of skin substitute prepared from collagen scaffold co-culture with keratinocyte and fibroblast on wound healing in rat. *Research Journal of faculty Medicine*. 2012; 36(1):19-28.

How to Cite This Article

Kouhbanani Nejad S, Armin F, Dabiri S, Derakhshani A, Iranpour M, Farsinejad A. Application and Assessment of Allogeneic Fibroblasts for Cell Therapy. *Iranian Journal of Pathology*, 2018; 13(4): 454-460.