

Genetic and Epigenetic Alterations in Parathyroid Neoplasms

Seyed Amir Miratashi Yazdi¹ , Elham Nazar^{*2} 

1. Department of General Surgery, Sina Hospital, Tehran University of Medical Sciences, Tehran, Iran
2. Department of Pathology, Sina Hospital, Tehran University of Medical Sciences, Tehran, Iran

KEYWORDS

Carcinoma, Mutation, Parafibromin,
Parathyroid gland

[Scan to discover online](#)



Main Subjects:
Molecular Pathology

Received 01 Apr 2022;

Accepted 16 Aug 2022;

Published Online 25 Aug 2022;

 [10.30699/ijp.2022.551233.2865](https://doi.org/10.30699/ijp.2022.551233.2865)

ABSTRACT

The exact etiology of parathyroid carcinomas (PC) is still unknown. Their associations with several inherited syndromes or specific genetic lesions have been established. The management of PC is challenging for clinicians. The complexity of molecular phenotypes increases with tumor aggressiveness. Lack of parafibromin on immunohistochemistry staining and HRPT2 mutation would be helpful in differentiation of carcinoma from adenoma. Lack of parafibromin expression, the gene product of HRPT2 is now used as a diagnostic, prognostic, and predictive marker for parathyroid carcinoma. The epigenetic alteration, for example, DNA methylation and modifications in the chromatin structure, are known as significant events involved in the parathyroid tumorigenesis. We suggest that adjuvant genetic and epigenetic target therapy should be considered in treatment of the patients with PC.

Corresponding Information:

Elham Nazar, 2. Department of Pathology, Sina Hospital, Tehran University of Medical Sciences, Tehran, Iran

Email: elhamnazar@yahoo.com

Copyright © 2022. This is an open-access article distributed under the terms of the Creative Commons Attribution- 4.0 International License, which permits Share, copy and redistribution of the material in any medium or format or adapt, remix, transform, and build upon the material for any purpose, even commercially.

Introduction

The parathyroid glands are located in the back of the thyroid gland and secrete parathyroid hormone (PTH), which is needed for calcium homeostasis (1). Parathyroid glands sense the calcium level in extracellular parts via the G-protein coupled calcium-sensing receptor and secrete PTH (2). The etiology for parathyroid cancer is principally mysterious. Some familial syndromes with specific genetic mutations have been described (3). Also, patients with familial hyperparathyroidism, multiple endocrine neoplasia type 1 (MEN 1), and a history of cervical radiotherapy are at high risk for parathyroid cancer development (4).

The incidence of benign parathyroid disease is higher in women compared to men (3-4:1 ratio) but parathyroid cancer may occur with an equivalent rate in both genders. The age at diagnosis of parathyroid cancer is earlier than benign primary hyperparathyroidism (PHPT) (5). Parathyroid cancer in young people has familial and genetic basis (6). Parathyroid carcinoma (PC) is an infrequent tumor of different behavior of aggressiveness without an existing staging system (7).

Most parathyroid cancers release PTH and consequently induce hypercalcemia. So, parathyroid cancer's morbidity and mortality are generally due to metabolic issues (8). Increased serum PTH level is the reason for bone resorption and damage, which is

acknowledged as osteitis fibrosa cystica (9). The most common manifestations are bone disease, palpable neck mass, and renal stone with increased serum calcium (10). Although diagnosis before surgery is difficult, clinicians should suspect hyperparathyroid patients with a palpable neck mass, severe hypercalcemia, a noticeable rise in serum PTH level, and metabolic complications (11).

However, in developed countries, most PHPT patients are asymptomatic (12) due to routine neck ultrasonography assessment and incidental parathyroid lesion (13). PC is a slow-growing tumor, and metastasis occurs lately in the most common sites, including lungs, cervical lymph nodes, and liver. Local recurrence in PC is usual and happens in cervical areas (14). So, PC resection with a shift of intraoperative PTH level to normal range confirmation should be considered (15). PC usually has local recurrence with adjacent lymph node involvement (16) as the decisive prognosis relates to successful complete tumor excision at the first surgery (17). Due to the variable aggressiveness of this tumor, treatment should be individualized (18). A bulky gray-white mass with local invasion is usually seen as the surgical finding of these tumors (19).

Histomorphologic evaluation for PC consists of presence of a trabecular growth pattern; thick fibrous trabeculae; mitotic rate (>1/10 HPFs); capsular or

vascular invasion; lymph node involvement; or metastasis (20). The 2022 World Health Organization (WHO) classification described the role of molecular assessment in parathyroid neoplasms (21). Also, the WHO histopathologic criteria are described for diagnosing PC now, including adjacent tissue invasion and distant metastasis (22). PC and atypical parathyroid adenoma (APA) are different in tumor biology, recurrence rate, disease-free survival, and overall survival. So, there are diverse clinical entities (23). Clinical and paraclinical findings and operative discoveries may be indicated for PC but may not be definite, especially if there is no invasion or metastasis document (24). Awareness at the time of operation is required for the malignant potential of the encountered parathyroid mass (25). So, the treatment choice for primary and recurrent PC is surgery (26).

Severe uncontrolled hypercalcemia is the main cause of morbidity and mortality after surgery (27). Patients' gold standard of operation is en bloc resection of the tumor (28). But the worth of en bloc resection at initial surgery is still controversial because surgery discoveries cannot discriminate APA from PC definitely (29). So, radiotherapy may be useful in patients whose PC diagnosis has been proved after surgery and histopathology evaluation (30). After tumor resection, the probability of recurrence is high and may need resection metastasis several times until control hypercalcemia manifestations (31). Also, adjuvant radiotherapy may decrease the recurrence rate and is useful for local control (32). In fact, PC management is challenging for clinicians (33). The absence of a presurgery diagnosis and inappropriate surgery schedule with its influence on survival are incompletely described (34). In addition, tumor features in histopathology examination and stage prognosis of PC are significantly related to the surgeon's skill, which is correlated with preoperative diagnosis (35). Transforming a normal cell to a neoplastic cell needs numerous genetic and epigenetic mutation series (36). For example, transcription factors, including paired box-1 (PAX1), have an active role in parathyroid neoplasms (37). So, our review described genetic and epigenetic mutations related to PC for use as diagnostic markers and new therapeutic agents for these tumors (38).

Types of Parathyroid Neoplasms

Parathyroid tumors are a common reason for PHPT, and the diagnostic workup is often straightforward in most patients (39). Serum calcium, PTH, and alkaline phosphatase (ALP) levels in patients with PC are higher than in patients with benign disease (40). Serum calcium, PTH levels, and tumor weights are meaningfully more in the PC but are not always a discriminatory method (41). PC manifestations are profound hypercalcemia and skeletal and renal problems due to hyperparathyroidism (42). However, nonfunction parathyroid cancers have aggressive behavior (43). Also, non-invasive cervical ultrasonography may suggest a diagnostic clue to PC (44). Almost entirely recognized PCs are >15 mm at the time of diagnosis (45).

Parathyroid lesions with ill-defined borders and non-homogeneous echogenicity on ultrasonography are expected to be PC (46). Magnetic resonance imaging (MRI) and computerized tomography (CT) scans are specifically valuable for recognizing mediastinal and thoracic recurrences of PC (47). Established histopathological parameters for discriminating benign from malignant parathyroid masses are not presented and cannot be predicted unfavorable prognosis (48). Clinical distinction between PC and APA has critical significance in deciding the proper extent of surgery and follow up (49).

Also, age, sex, and tumor size have uncertain effects on survival in patients with PC (50). Based on histopathology evaluation, nuclear atypia and mitotic figures are predominant in PC (51). Nevertheless, clinical follow-up of patients with marked mitotic figures on histopathology examination exhibits no evidence of recurrence or aggressive behavior. Mitotic rate is not a reliable indicator of malignant potential in parathyroid masses (52). So, these findings are not distinctive for malignancy. According to WHO criteria, PC diagnosis should be limited to tumors with adjacent soft tissues, thyroid gland, blood vessel invasion, or patients with known metastases (53). Capsular invasion is the most important histopathologic finding (54). Also, tumor nuclear DNA index is beneficial in PC diagnosis verification, but they are limited in predicting prognosis in PC (55). Patients with established metastasis have profound hypercalcemia due to high PTH levels (56). And post-operative development of PC has a high mortality (57). Some studies showed that local cervical radiotherapy may have decreased the probability of local recurrence (58). The complexity of genetic and epigenetic mutations increases tumor aggressiveness (59). Histopathology and molecular evaluation are important factors for predicting the time of recurrence (60).

Material and Methods

Our literature review was done by an electronic search for published articles in PubMed, Web of Science, NCBI, Scopus, and Google Scholar databases. The search was done using keywords including parathyroid gland, parathyroid carcinoma, parafibromin, and mutation. We had no limitations for the date of publication. The inclusion criteria for our search consisted of those articles showing the keywords in the title or abstract. The exclusion criteria were those articles not found in English literature. A library of all used articles was made using EndNote X20.1 software.

Genetic Profiles

Malignant potential evaluation of parathyroid lesions in the lack of metastases can be problematic by histomorphology findings alone (61). Genome-wide study of parathyroid tumors described some genes with transformed DNA methylation patterns as supposed to be important to benign and malignant parathyroid tumorigenesis (62). Some known genetics include

deactivating and triggering alterations, and epigenetics include suppressive CpG methylation and H3K27 methylation detected in parathyroid tumors (63). The etiology of PC is unidentified, but the newly revealed HRPT2 gene (1q21-q32), a tumor suppressor gene encoding for the protein parafibromin, has been concerned in tumorigenesis (64). HRPT2 mutation is the cause of parafibromin inactivation in the germline of patients with hyperparathyroidism-jaw tumor (HPT-JT) syndrome first time (65). Parafibromin is a helpful molecular indicator for PC (66). Parafibromin produced from HRPT2/CDC73 gene is the human homolog of the yeast Cdc73 protein and is a section of the Protein Associated Factor1 complex (PAF1) and

implicated in transcription and post-transcription control ways (67). Lack of parafibromin on immunohistochemistry (IHC) staining presents capable consequences in differentiating PC from APA and might also assist as a prognostic factor (Figure 1) (68) as well as deactivating mutations of the CDC73 (tumor suppressor gene) have been informed in PC which is accompanying by lack of nuclear expression of parafibromin. The occurrence of the CDC73 mutation and lack of parafibromin predict unfavorable prognosis and high recurrence or metastasis rate (69).

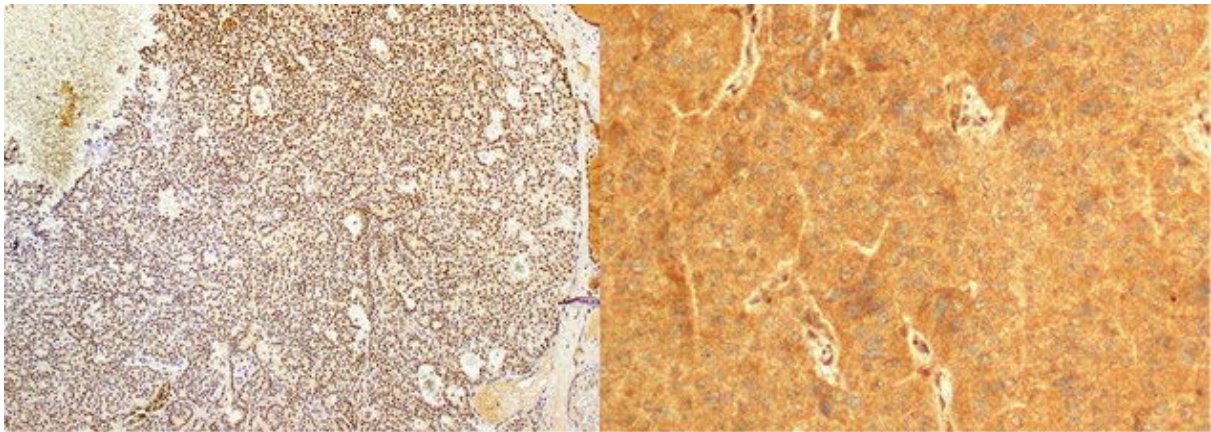


Fig. 1. Immunohistochemical staining shows nuclear staining in the hyperplastic parathyroid gland (left) and lack of nuclear staining in parathyroid carcinoma (right) (70).

IHC staining for parafibromin is difficult technically and has been arrayed by diverse researchers with variable methods and grades (71). So, parafibromin immunostaining cannot substitute genetic profile examination or be introduced as a single indicator to discrete APA from PC (72). Sporadic PCs predominantly have HRPT2 mutations that are expected to be the reason for tumorigenesis (73). Also, HRPT2 mutations indicate malignancy in both familial and sporadic parathyroid neoplasms (74). Strong immunostaining for PGP9.5 has a sensitivity of 78% for discovering PC in parathyroid tumors with some features of malignancy. PGP9.5 is positive in a parathyroid neoplasm with the HRPT2 mutation, which no expressed parafibromin (75). In HPT-JT syndrome, patients with HRPT2 mutations have a high chance for development of PC, which is supported for being responsible for HRPT2 mutations in the development of PC (76).

Parathyroid tumors know familial MEN-1, and the gene related to MEN-1, located on chromosome 11 (11q13), may generally prevent tumor proliferation; tumors could arise from deactivating one or both of the alleles (77). The MEN1 gene produces menin, which may act in a transcription regulation pathway, including JunD and other menin-interacting proteins (78). Parathyroid neoplasms in the MEN2A syndrome are result of

mutation of the RET oncogene. Also, CCND1/PRAD1 oncogene is revealed by examination of sporadic parathyroid neoplasms (79). As well as respectable studies support mutation in the CDKN1B/p27 cyclin-dependent kinase inhibitor (CDKI) gene and in other CDKI genes are cause of parathyroid neoplasms (80). Cyclin D1 protein overexpression is not restricted to neoplastic process of parathyroid gland but is also identified in the non-neoplastic process of parathyroid tissue. Cyclin D1 protein overexpression seldom exists in the normal parathyroid gland (81). Other cell cycle regulators may interfere in the parathyroid tumorigenesis, such as rearrangement and overexpression of the PRAD1/cyclin D1 gene in APA and deactivation of the retinoblastoma tumor (RB) suppressor gene in PC (82). Although the loss of expression of RB and BRCA2 genes may relate to PC, the role of 13q loss needs supplementary study as a diagnostic indicator for PC (83).

Also, the RB gene deactivation usually happens in PC and is expected to be a significant indicator in molecular profile. Such deactivations may aid in discrimination of benign from malignant parathyroid disease and may be beneficial for diagnosis, prognosis, and therapeutic choices (84). So, RB or loss of 13q is definite for parathyroid neoplasms with aggressive behaviour (85). Gal-3 immunostaining is

an important marker to support a diagnosis of PC in tumors with high proliferative index (Ki67 >6%) which involves a single parathyroid gland (86). MiRNAs are small noncoding RNAs that prevent the translation and stability of messenger RNAs (mRNAs) (87). Comparative genomic hybridization (CGH) analysis recognized chromosomal differences with recurrent loss or gain of regions in parathyroid cancers. Chromosomal imbalances have been known as a way could change the expression of miRNAs (88). Aberrant regulation of Wnt/ β -catenin signaling might be significant for the growth of parathyroid tumors (89). Aberrant accretion of β -catenin is also actually common in parathyroid tumors (90). The β -catenin target gene c-myc is overexpressed in many patients with parathyroid tumors (91). β -Catenin is accompanied by PC with adjacent tissue invasion, metastasis, and poor outcome. Some new research has established that abnormal β -catenin expression, particularly in the nucleus, is an important factor in the wingless/Wnt signaling pathway (92). Recent studies proved that both gene and protein expression, including Histone 1 Family 2, amyloid β precursor protein, and E-cadherin are suitable indicators for PC and propose the occurrence of the HRPT2 mutation (93). PC has a three- to fourfold decline in p27 expression compared with adenoma. These results have advised that decreased p27 expression and high Ki-67 index may be beneficial for the difference between adenoma and carcinoma (94).

Also, the coding region of the calcium sensing receptor gene mutations and deletions are not triggered in the tumorigenesis of sporadic parathyroid neoplasms (95). Whole exome sequencing recognized other genes consisting of mTOR, kmt2d, cdkn2c, thrap3, pik3ca, and ezh2 mutation and ccnd1 gene amplification (96). Loss of chromosome arm 1p is the most prevalent finding in molecular profile of parathyroid neoplasms recommending that 1p is the region of a tumor suppressor gene which deactivation interferes to parathyroid tumorigenesis (97). Also, the newly described tumor suppressor gene RIZ1, sited at 1p36, has appeared as a presumed indicator to be elaborated in endocrine tumorigenesis (98). So, loss of chromosome 1p is meaningfully accompanied by PC and used as a discriminating marker from adenoma (99). Unlike genetic variations are involved in growth of parathyroid neoplasms including predominantly genes losses in adenoma and gains coexistent with some losses in carcinoma (100).

In addition, some significant target proteins associated with angiogenesis and cell proliferation may be therapeutic targets in PC such as COX-1/2, Gst- π and members of sonic hedgehog pathway (101). A qualified surgeon should perform parathyroid resection in HRPT2 mutated patients and consist of visual examination of all bilateral parathyroid glands

and en bloc excision of any uncharacteristic appearance glands (102). Molecular examination including specific micro-RNAs and proteins, and germ line mutations in CDC73 can detect in high risk patients but is inappropriate for presurgery evaluation due to the probable risks related with biopsy (103). In fact, the diagnostic use of molecular genetic investigates to separate benign from aggressive parathyroid neoplasms will possible need investigation of a panel of some markers or chromosomal regions, rather than any single one, to reach numerical and clinical consequences (104). A panel of IHC study including PGP9.5, galectin-3, parafibromin, and Ki67 is better than any single immunostaining and can be used as supplementary evaluation for parathyroid neoplasm diagnosis (105). Other tumor markers including P53 and BCL2 are not suitable in discriminating adenoma from carcinoma (106).

Epigenetic Profiles

Tumor suppressor gene loss is vital in the beginning and development of cancer cells. Epigenetic alterations, for example, DNA methylation and modifications in the chromatin structure, are known as significant events that are the reason for tumor suppressor deactivation (107). DNA methylation, microRNA deregulations, and histone methylation diminishing are distinguished in parathyroid neoplasms (108). Downregulation of miRNAs is seen in PC and upregulation of miRNAs in the hyperplastic parathyroid gland. Also, miRNA profile evaluation reveals discrete miRNAs expression by tumor type, which may help as supportive indicator to discriminate benign from malignant (109). So, downregulation of miRNA is discovered in PC and is a diagnostic marker (110). However, the epigenetic status is not correlated with C19MC miRNA expression levels; decreased C19MC promoter methylation is meaningfully connected with PC and metastasis (111).

DNA hypermethylation of CDKN2B, CDKN2A, WT1, SFRP1, SFRP2, and SFRP4 is related to decreased gene expression in equally adenoma and carcinoma (62). Loss of heterozygosity of chromosome 11 and MEN1 gene modifications in sporadic parathyroid adenoma and associates with an unrelated methyltransferase gene EZH2 has an important role in endocrine tumorigenesis (112). Hypermethylated in cancer 1 (HIC1) is a tumor suppressor gene in parathyroid glands that impaired expression of HIC1 may describe an initial occurrence through tumor progress, and only PC shows an increased methylation level and decreased HIC1 expression (113). Promoter hypermethylation in RASSF1 and APC genes has been defined in PC, like thyroid tumors. Hypermethylated CDKN2B, P16, WT1, SFRP1, SFRP2, and SFRP4 are also seen in PC (114). Promoter hypermethylation of APC and RASSF1A are recognized in parathyroid neoplasms (115). Aberrant WNT/ β -catenin signaling by loss of

expression and DNA methylation of APC and accumulation of active non-phosphorylated β -catenin is detected in the examined PC (116).

Probably, DNA methylation, histone acetylation, or deacetylation of genes identified to be linked with parathyroid tumorigenesis or unknown genes until now may reason for the unprogrammed proliferation of parathyroid cells (117). Other events, including HRPT2 intronic regions mutation, added epigenetic regulation including histone modifications, or further regulatory deactivation events, including pointing by microRNAs, may act as a reason for decreased parafibromin expression (118). Post translation histone modification was related to parathyroid tumorigenesis and the potential for new target therapy agents (119). Therefore, some studies recommend that adjuvant epigenetic therapy be noticed as an extra choice in managing patients with recurrent or metastatic PC (120).

Conclusion

Measurement of DNA content is a suitable indicator for proper diagnosis of PC and estimates of overall survival (44). Parafibromin immunostaining could be introduced as a beneficial marker for improved PC diagnosis along with proliferation index (121). Lack of parafibromin immunostaining is nearly always linked with HRPT2 mutations, and the lack of parafibromin immunostaining powerfully suggests PC.

This immunostaining could be beneficial in parathyroid neoplasms with confusing histopathological features (122). So, due to a lack of parafibromin expression, the gene product of HRPT2 is now used as a diagnostic, prognostic, and predictive marker for PC (123). No single indicative marker now distinguishes whether a parathyroid mass is a PC. Still, lack of parafibromin and other molecular changes, for example, Rb expression, and galectin-3 over-expression, usually discriminate PC from other parathyroid neoplasms (124). Germline DNA analysis for HRPT2/CDC73 mutation is advised in all patients with parathyroid neoplasm for the possible advantage for first-degree families (125). We suggest that adjuvant genetic and epigenetic target therapy should be considered in treating PC patients.

Acknowledgments

None

Conflict of Interest

The authors declared no conflict of interest.

Funding

None.

References

1. Palestro CJ, Tomas MB, Tronco GG, editors. Radionuclide imaging of the parathyroid glands. Seminars in nuclear medicine; 2005: Elsevier. [DOI:10.1053/j.semnucmed.2005.06.001] [PMID]
2. Wynne AG, van Heerden J, Carney JA, Fitzpatrick LA. Parathyroid carcinoma: clinical and pathologic features in 43 patients. *Medicine (Baltimore)*. 1992;71(4):197-205. [DOI:10.1097/00005792-199207000-00002]
3. Rodgers SE, Perrier ND. Parathyroid carcinoma. *Curr Opin Oncol*. 2006;18(1):16-22. [PMID] [DOI:10.1097/01.cco.0000198019.53606.2b]
4. Koea JB, Shaw JH. Parathyroid cancer: biology and management. *Surg Oncol*. 1999;8(3):155-65. [DOI:10.1016/S0960-7404(99)00037-7]
5. Marcocci C, Cetani F, Rubin MR, Silverberg SJ, Pinchera A, Bilezikian JP. Parathyroid carcinoma. *J Bone Miner Res*. 2008;23(12):1869-80. [DOI:10.1359/jbmr.081018] [PMID] [PMCID]
6. Hamill J, Maoate K, Beasley SW, Corbett R, Evans J. Familial parathyroid carcinoma in a child. *J Paediatr Child Health*. 2002;38(3):314-7. [DOI:10.1046/j.1440-1754.2002.00802.x] [PMID]
7. Kleinpeter KP, Lovato JF, Clark PB, Wooldridge T, Norman ES, Bergman S, et al. Is parathyroid carcinoma indeed a lethal disease? *Ann Surg Oncol*. 2005;12(3):260-6. [DOI:10.1245/ASO.2005.03.036] [PMID]
8. Lee PK, Jarosek SL, Virnig BA, Evasovich M, Tuttle TM. Trends in the incidence and treatment of parathyroid cancer in the United States. *Cancer*. 2007;109(9):1736-41. [DOI:10.1002/cncr.22599] [PMID]
9. Huang R, Zhuang R, Liu Y, Li T, Huang J. Unusual presentation of primary hyperparathyroidism: report of three cases. *BMC Med Imaging*. 2015;15(1):23. [DOI:10.1186/s12880-015-0064-1] [PMID] [PMCID]
10. Schantz A, Castleman B. Parathyroid carcinoma. A study of 70 cases. *Cancer*. 1973;31(3):600-5. [DOI:10.1002/1097-0142(197303)31:33.0.CO;2-0]

11. Wang CA, Gaz RD. Natural history of parathyroid carcinoma. Diagnosis, treatment, and results. *Am J Surg.* 1985;149(4):522-7. [[DOI:10.1016/S0002-9610\(85\)80050-7](https://doi.org/10.1016/S0002-9610(85)80050-7)]
12. Shah VN, Bhadada S, Bhansali A, Behera A, Mittal BR. Changes in clinical & biochemical presentations of primary hyperparathyroidism in India over a period of 20 years. *Indian J Med Res.* 2014;139(5):694-9.
13. Zhao L, Liu JM, He XY, Zhao HY, Sun LH, Tao B, et al. The changing clinical patterns of primary hyperparathyroidism in Chinese patients: data from 2000 to 2010 in a single clinical center. *J Clin Endocrinol Metab.* 2013;98(2):721-8. [[DOI:10.1210/jc.2012-2914](https://doi.org/10.1210/jc.2012-2914)] [[PMID](#)]
14. Betea D, Bradwell AR, Harvey TC, Mead GP, Schmidt-Gayk H, Ghaye B, et al. Hormonal and biochemical normalization and tumor shrinkage induced by anti-parathyroid hormone immunotherapy in a patient with metastatic parathyroid carcinoma. *J Clin Endocrinol Metab.* 2004;89(7):3413-20. [[DOI:10.1210/jc.2003-031911](https://doi.org/10.1210/jc.2003-031911)] [[PMID](#)]
15. Clayman GL, Gonzalez HE, El-Naggar A, Vassilopoulou-Sellin R. Parathyroid carcinoma: evaluation and interdisciplinary management. *Cancer.* 2004;100(5):900-5. [[DOI:10.1002/cncr.20089](https://doi.org/10.1002/cncr.20089)] [[PMID](#)]
16. Hundahl SA, Fleming ID, Fremgen AM, Menck HR. Two hundred eighty-six cases of parathyroid carcinoma treated in the US between 1985-1995: a National Cancer Data Base Report. *Cancer.* 1999;86(3):538-44. [[DOI:10.1002/\(SICI\)1097-0142\(19990801\)86:33.0.CO:2-K](https://doi.org/10.1002/(SICI)1097-0142(19990801)86:33.0.CO:2-K)]
17. Shane E. Clinical review 122: Parathyroid carcinoma. *J Clin Endocrinol Metab.* 2001;86(2):485-93. [[DOI:10.1210/jcem.86.2.7207](https://doi.org/10.1210/jcem.86.2.7207)] [[PMID](#)]
18. Sandelin K, Thompson NW, Bondeson L. Metastatic parathyroid carcinoma: dilemmas in management. *Surgery.* 1991;110(6):978-86; discussion 86-8.
19. Kebebew E. Parathyroid carcinoma. *Curr Treat Options Oncol.* 2001;2(4):347-54. [[DOI:10.1007/s11864-001-0028-2](https://doi.org/10.1007/s11864-001-0028-2)] [[PMID](#)]
20. Fernandez-Ranvier GG, Khanafshar E, Jensen K, Zarnegar R, Lee J, Kebebew E, et al. Parathyroid carcinoma, atypical parathyroid adenoma, or parathyromatosis? *Cancer.* 2007;110(2):255-64. [[DOI:10.1002/cncr.22790](https://doi.org/10.1002/cncr.22790)] [[PMID](#)]
21. Erickson LA, Mete O, Juhlin CC, Perren A, Gill AJ. Overview of the 2022 WHO Classification of Parathyroid Tumors. *Endocr Pathol.* 2022;33(1):64-89. [[DOI:10.1007/s12022-022-09709-1](https://doi.org/10.1007/s12022-022-09709-1)] [[PMID](#)]
22. Cakir B, Polat SB, Kilic M, Ozdemir D, Aydin C, Süngü N, et al. Evaluation of preoperative ultrasonographic and biochemical features of patients with aggressive parathyroid disease: is there a reliable predictive marker? *Arch Endocrinol Meta.* 2016;60(6):537-44. [[DOI:10.1590/2359-3997000000224](https://doi.org/10.1590/2359-3997000000224)] [[PMID](#)]
23. Christakis I, Bussaidy N, Clarke C, Kwatampora LJ, Warneke CL, Silva AM, et al. Differentiating Atypical Parathyroid Neoplasm from Parathyroid Cancer. *Ann Surg Oncol.* 2016;23(9):2889-97. [[DOI:10.1245/s10434-016-5248-6](https://doi.org/10.1245/s10434-016-5248-6)] [[PMID](#)]
24. Temmim L, Sinowatz F, Hussein WI, Al-Sanea O, El-Khodary H. Intrathyroidal parathyroid carcinoma: a case report with clinical and histological findings. *Diagn Pathol.* 2008;3(1):46. [[DOI:10.1186/1746-1596-3-46](https://doi.org/10.1186/1746-1596-3-46)] [[PMID](#)] [[PMCID](#)]
25. Schoretzanitis G, Daskalakis M, Melissas J, Tsiftsis DD. Parathyroid carcinoma: clinical presentation and management. *Am J Otolaryngol.* 2009;30(4):277-80. [[DOI:10.1016/j.amjoto.2008.05.006](https://doi.org/10.1016/j.amjoto.2008.05.006)] [[PMID](#)]
26. Hoelting T, Weber T, Werner J, Herfarth C. Surgical treatment of parathyroid carcinoma (Review). *Oncol Rep.* 2001;8(4):931-4. [[DOI:10.3892/or.8.4.931](https://doi.org/10.3892/or.8.4.931)] [[PMID](#)]
27. Givi B, Shah JP. Parathyroid carcinoma. *Clin Oncol (R Coll Radiol).* 2010;22(6):498-507. [[DOI:10.1016/j.clon.2010.04.007](https://doi.org/10.1016/j.clon.2010.04.007)] [[PMID](#)] [[PMCID](#)]
28. Lumachi F, Basso SM, Basso U. Parathyroid cancer: etiology, clinical presentation and treatment. *Anticancer Res.* 2006;26(6C):4803-7.
29. Ippolito G, Palazzo FF, Sebag F, De Micco C, Henry JF. Intraoperative diagnosis and treatment of parathyroid cancer and atypical parathyroid adenoma. *Br J Surg.* 2007;94(5):566-70. [[DOI:10.1002/bjs.5570](https://doi.org/10.1002/bjs.5570)] [[PMID](#)]
30. Kirkby-Bott J, Lewis P, Harmer CL, Smellie WJ. One stage treatment of parathyroid cancer. *Eur J Surg Oncol.* 2005;31(1):78-83. [[DOI:10.1016/j.ejso.2004.06.014](https://doi.org/10.1016/j.ejso.2004.06.014)] [[PMID](#)]
31. Thompson SD, Prichard AJ. The management of parathyroid carcinoma. *Curr Opin Otolaryngol Head Neck Surg.* 2004;12(2):93-7. [[DOI:10.1097/00020840-200404000-00007](https://doi.org/10.1097/00020840-200404000-00007)]
32. Busaidy NL, Jimenez C, Habra MA, Schultz PN, El-Naggar AK, Clayman GL, et al. Parathyroid carcinoma: a 22-year experience. *Head Neck.* 2004;26(8):716-26. [[DOI:10.1002/hed.20049](https://doi.org/10.1002/hed.20049)] [[PMID](#)]
33. Chiofalo MG, Scognamiglio F, Losito S, Lastoria S, Marone U, Pezzullo L. Huge parathyroid carcinoma: clinical considerations and literature

- review. *World J Surg Oncol.* 2005;3(1):39. [DOI:10.1186/1477-7819-3-39] [PMID] [PMCID]
34. Schaapveld M, Jorna FH, Aben KK, Haak HR, Plukker JT, Links TP. Incidence and prognosis of parathyroid gland carcinoma: a population-based study in The Netherlands estimating the preoperative diagnosis. *Am J Surg.* 2011;202(5):590-7. [DOI:10.1016/j.amjsurg.2010.09.025] [PMID]
 35. Villar-del-Moral J, Jimenez-Garcia A, Salvador-Egea P, Martos-Martinez JM, Nuno-Vazquez-Garza JM, Serradilla-Martin M, et al. Prognostic factors and staging systems in parathyroid cancer: a multicenter cohort study. *Surgery.* 2014;156(5):1132-44. [DOI:10.1016/j.surg.2014.05.014] [PMID]
 36. Nazar E, Khatami F, Saffar H, Tavangar SM. The Emerging Role of Succinate Dehydrogenase Genes (SDHx) in Tumorigenesis. *Int J Hematol Oncol Stem Cell Res.* 2019;13(2):72-82. [PMCID] [DOI:10.18502/ijhoscr.v13i2.692] [PMID]
 37. Singh P, Bhadada SK, Arya AK, Saikia UN, Sachdeva N, Dahiya D, et al. Aberrant Epigenetic Alteration of PAX1 Expression Contributes to Parathyroid Tumorigenesis. *J Clin Endocrinol Metab.* 2022;107(2):e783-e92. [DOI:10.1210/clinem/dgab626] [PMID]
 38. Silva-Figueroa AM, Perrier ND. Epigenetic processes in sporadic parathyroid neoplasms. *Mol Cell Endocrinol.* 2018;469:54-9. [DOI:10.1016/j.mce.2017.04.007] [PMID]
 39. Carling T, Udelsman R. Parathyroid tumors. *Curr Treat Options Oncol.* 2003;4(4):319-28. [DOI:10.1007/s11864-003-0007-x] [PMID]
 40. Bae JH, Choi HJ, Lee Y, Moon MK, Park YJ, Shin CS, et al. Preoperative predictive factors for parathyroid carcinoma in patients with primary hyperparathyroidism. *J Korean Med Sci.* 2012;27(8):890-5. [DOI:10.3346/jkms.2012.27.8.890] [PMID] [PMCID]
 41. Robert JH, Trombetti A, Garcia A, Pache J-C, Herrmann F, Spiliopoulos A, et al. Primary hyperparathyroidism: can parathyroid carcinoma be anticipated on clinical and biochemical grounds? Report of nine cases and review of the literature. *Ann Surg Oncol.* 2005;12(7):526-32. [DOI:10.1245/ASO.2005.06.005] [PMID]
 42. Shane E, Bilezikian JP. Parathyroid carcinoma: a review of 62 patients. *Endocr Rev.* 1982;3(2):218-26. [DOI:10.1210/edrv-3-2-218] [PMID]
 43. Anderson BJ, Samaan NA, Vassilopoulou-Sellin R, Ordonez NG, Hickey RC. Parathyroid carcinoma: features and difficulties in diagnosis and management. *Surgery.* 1983;94(6):906-15.
 44. Obara T, Fujimoto Y. Diagnosis and treatment of patients with parathyroid carcinoma: an update and review. *World J Surg.* 1991;15(6):738-44. [DOI:10.1007/BF01665308] [PMID]
 45. Sidhu PS, Talat N, Patel P, Mulholland NJ, Schulte K-M. Ultrasound features of malignancy in the preoperative diagnosis of parathyroid cancer: a retrospective analysis of parathyroid tumours larger than 15 mm. *Eur Radiol.* 2011;21(9):1865. [DOI:10.1007/s00330-011-2141-3] [PMID]
 46. Hara H, Igarashi A, Yano Y, Yashiro T, Ueno E, Aiyoshi Y, et al. Ultrasonographic features of parathyroid carcinoma. *Endocr J.* 2001;48(2):213-7. [DOI:10.1507/endocrj.48.213] [PMID]
 47. Kebebew E, Arici C, Duh QY, Clark OH. Localization and reoperation results for persistent and recurrent parathyroid carcinoma. *Arch Surg.* 2001;136(8):878-85. [DOI:10.1001/archsurg.136.8.878] [PMID]
 48. Abbona G, Papotti M, Gasparri G, Bussolati G. Proliferative activity in parathyroid tumors as detected by Ki-67 immunostaining. *Hum Pathol.* 1995;26(2):135-8. [DOI:10.1016/0046-8177(95)90028-4]
 49. Quinn CE, Healy J, Lebastchi AH, Brown TC, Stein JE, Prasad ML, et al. Modern experience with aggressive parathyroid tumors in a high-volume New England referral center. *J Am Coll Surg.* 2015;220(6):1054-62. [DOI:10.1016/j.jamcollsurg.2014.10.007] [PMID]
 50. Asare EA, Sturgeon C, Winchester DJ, Liu L, Palis B, Perrier ND, et al. Parathyroid Carcinoma: An Update on Treatment Outcomes and Prognostic Factors from the National Cancer Data Base (NCDB). *Ann Surg Oncol.* 2015;22(12):3990-5. [DOI:10.1245/s10434-015-4672-3] [PMID]
 51. Sandelin K, Tullgren O, Farnebo LO. Clinical course of metastatic parathyroid cancer. *World J Surg.* 1994;18(4):594-8; discussion 9. [DOI:10.1007/BF00353773] [PMID]
 52. Snover DC, Foucar K. Mitotic activity in benign parathyroid disease. *Am J Clin Pathol.* 1981;75(3):345-7. [DOI:10.1093/ajcp/75.3.345] [PMID]
 53. DeLellis RA. Challenging lesions in the differential diagnosis of endocrine tumors: parathyroid carcinoma. *Endocr Pathol.* 2008;19(4):221. [DOI:10.1007/s12022-008-9050-2] [PMID]
 54. Cordeiro AC, Montenegro FL, Kulcsar MA, Dellanegra LA, Tavares MR, Michaluart P, Jr., et al. Parathyroid carcinoma. *Am J Surg.* 1998;175(1):52-5. [DOI:10.1016/S0002-9610(97)00228-6]
 55. Lumachi F, Ermani M, Marino F, Poletti A, Basso SM, Iacobone M, et al. Relationship of AgNOR counts and nuclear DNA content to survival in patients with parathyroid carcinoma. *Endocr Relat*

- Cancer. 2004;11(3):563-9. [DOI:10.1677/erc.1.00792] [PMID]
56. Shaha AR, Ferlito A, Rinaldo A. Distant metastases from thyroid and parathyroid cancer. *ORL J Otorhinolaryngol Relat Spec.* 2001;63(4):243-9. [DOI:10.1159/000055749] [PMID]
 57. Munson ND, Foote RL, Northcutt RC, Tiegs RD, Fitzpatrick LA, Grant CS, et al. Parathyroid carcinoma: is there a role for adjuvant radiation therapy? *Cancer.* 2003;98(11):2378-84. [DOI:10.1002/cncr.11819] [PMID]
 58. Chow E, Tsang RW, Brierley JD, Filice S. Parathyroid carcinoma-the princess margaret hospital experience. *Int J Radiat Oncol Biol.* 1998;41(3):569-72. [DOI:10.1016/S0360-3016(98)00098-4]
 59. Stojadinovic A, Hoos A, Nissan A, Dudas ME, Cordon-Cardo C, Shaha AR, et al. Parathyroid neoplasms: clinical, histopathological, and tissue microarray-based molecular analysis. *Hum Pathol.* 2003;34(1):54-64. [DOI:10.1053/hupa.2003.55] [PMID]
 60. Sandelin K, Auer G, Bondeson L, Grimelius L, Farnebo LO. Prognostic factors in parathyroid cancer: a review of 95 cases. *World J Surg.* 1992;16(4):724-31. [DOI:10.1007/BF02067369] [PMID]
 61. Farnebo F, Auer G, Farnebo L-O, Teh BT, Twigg S, Aspenblad U, et al. Evaluation of retinoblastoma and Ki-67 immunostaining as diagnostic markers of benign and malignant parathyroid disease. *World J Surg.* 1999;23(1):68-74. [DOI:10.1007/s002689900567] [PMID]
 62. Starker LF, Svedlund J, Udelsman R, Dralle H, Akerstrom G, Westin G, et al. The DNA methylome of benign and malignant parathyroid tumors. *Genes Chromosomes Cancer.* 2011;50(9):735-45. [DOI:10.1002/gcc.20895] [PMID] [PMCID]
 63. Westin G. Molecular genetics and epigenetics of nonfamilial (sporadic) parathyroid tumours. *J Intern Med.* 2016;280(6):551-8. [DOI:10.1111/joim.12458] [PMID]
 64. Mittendorf EA, McHenry CR. Parathyroid carcinoma. *J Surg Oncol.* 2005;89(3):136-42. [DOI:10.1002/jso.20182] [PMID]
 65. Gill AJ, Clarkson A, Gimm O, Keil J, Dralle H, Howell VM, et al. loss of nuclear expression of parafibromin distinguishes parathyroid carcinomas and hyperparathyroidism-jaw tumor (HPT-JT) syndrome-related adenomas from sporadic parathyroid adenomas and hyperplasias. *Am J Surg Pathol.* 2006;30(9):1140-9. [PMID] [DOI:10.1097/01.pas.0000209827.39477.4f]
 66. Tan M-H, Morrison C, Wang P, Yang X, Haven CJ, Zhang C, et al. loss of parafibromin immunoreactivity is a distinguishing feature of parathyroid carcinoma. *Clin Cancer Res.* 2004;10(19):6629-37. [DOI:10.1158/1078-0432.CCR-04-0493] [PMID]
 67. Wang O, Wang C, Nie M, Cui Q, Guan H, Jiang Y, et al. Novel HRPT2/CDC73 gene mutations and loss of expression of parafibromin in Chinese patients with clinically sporadic parathyroid carcinomas. *PloS one.* 2012;7(9):e45567. [DOI:10.1371/journal.pone.0045567] [PMID] [PMCID]
 68. Kim HK, Oh YL, Kim SH, Lee DY, Kang HC, Lee JI, et al. Parafibromin immunohistochemical staining to differentiate parathyroid carcinoma from parathyroid adenoma. *Head Neck.* 2012;34(2):201-6. [DOI:10.1002/hed.21716] [PMID]
 69. Cetani F, Banti C, Pardi E, Borsari S, Viacava P, Miccoli P, et al. CDC73 mutational status and loss of parafibromin in the outcome of parathyroid cancer. *Endocr Connect.* 2013;2(4):186-95. [DOI:10.1530/EC-13-0046] [PMID] [PMCID]
 70. Turchini J, Gill AJ. Hereditary parathyroid disease: sometimes pathologists do not know what they are missing. *Endocr Pathol.* 2020;31(3):218-30. [DOI:10.1007/s12022-020-09631-4] [PMID]
 71. Gill AJ. Understanding the genetic basis of parathyroid carcinoma. *Endocr Pathol.* 2014;25(1):30-4. [DOI:10.1007/s12022-013-9294-3] [PMID]
 72. Juhlin C, Villablanca A, Sandelin K, Haglund F, Nordenstrom J, Forsberg L, et al. Parafibromin immunoreactivity: its use as an additional diagnostic marker for parathyroid tumor classification. *Endocr Relat Cancer.* 2007;14(2):501-12. [DOI:10.1677/ERC-07-0021] [PMID]
 73. Shattuck TM, Valimaki S, Obara T, Gaz RD, Clark OH, Shoback D, et al. Somatic and germline mutations of the HRPT2 gene in sporadic parathyroid carcinoma. *N Engl J Med.* 2003;349(18):1722-9. [DOI:10.1056/NEJMoa031237] [PMID]
 74. Howell VM, Haven CJ, Kahnoski K, Khoo SK, Petillo D, Chen J, et al. HRPT2 mutations are associated with malignancy in sporadic parathyroid tumours. *J Med Genet.* 2003;40(9):657-63. [DOI:10.1136/jmg.40.9.657] [PMID] [PMCID]
 75. Howell VM, Gill A, Clarkson A, Nelson AE, Dunne R, Delbridge LW, et al. Accuracy of combined protein gene product 9.5 and parafibromin markers for immunohistochemical diagnosis of parathyroid carcinoma. *J Clin Endocrinol Metab.* 2009;94(2):434-41. [DOI:10.1210/jc.2008-1740] [PMID]

76. DeLellis RA. Parathyroid carcinoma: an overview. *Adv Anat Pathol.* 2005;12(2):53-61. [[DOI:10.1097/01.pap.0000151319.42376.d4](https://doi.org/10.1097/01.pap.0000151319.42376.d4)] [[PMID](#)]
77. Friedman E, Sakaguchi K, Bale AE, Falchetti A, Streeten E, Zimering MB, et al. Clonality of parathyroid tumors in familial multiple endocrine neoplasia type 1. *N Engl J Med.* 1989;321(4):213-8. [[DOI:10.1056/NEJM198907273210402](https://doi.org/10.1056/NEJM198907273210402)] [[PMID](#)]
78. Arnold A, Shattuck TM, Mallya SM, Krebs LJ, Costa J, Gallagher J, et al. Molecular pathogenesis of primary hyperparathyroidism. *J Bone Miner Res.* 2002;17 Suppl 2:N30-6.
79. Sharretts JM, Simonds WF. Clinical and molecular genetics of parathyroid neoplasms. *Best Pract Res Clin Endocrinol Metab.* 2010;24(3):491-502. [[DOI:10.1016/j.beem.2010.01.003](https://doi.org/10.1016/j.beem.2010.01.003)] [[PMID](#)] [[PMCID](#)]
80. Costa-Guda J, Arnold A. Genetic and epigenetic changes in sporadic endocrine tumors: parathyroid tumors. *Mol Cell Endocrinol.* 2014;386(1-2):46-54. [[DOI:10.1016/j.mce.2013.09.005](https://doi.org/10.1016/j.mce.2013.09.005)] [[PMID](#)] [[PMCID](#)]
81. Vasef MA, Brynes RK, Sturm M, Bromley C, Robinson RA. Expression of cyclin D1 in parathyroid carcinomas, adenomas, and hyperplasias: a paraffin immunohistochemical study. *Mod Pathol.* 1999;12(4):412-6.
82. Cryns VL, Rubio MP, Thor AD, Louis DN, Arnold A. p53 abnormalities in human parathyroid carcinoma. *J Clin Endocrinol Metab.* 1994;78(6):1320-4. [[DOI:10.1210/jcem.78.6.8200932](https://doi.org/10.1210/jcem.78.6.8200932)] [[PMID](#)]
83. Shattuck TM, Kim TS, Costa J, Yandell DW, Imanishi Y, Palanisamy N, et al. Mutational analyses of RB and BRCA2 as candidate tumour suppressor genes in parathyroid carcinoma. *Clin Endocrinol.* 2003;59(2):180-9. [[DOI:10.1046/j.1365-2265.2003.01814.x](https://doi.org/10.1046/j.1365-2265.2003.01814.x)] [[PMID](#)]
84. Cryns VL, Thor A, Xu HJ, Hu SX, Wierman ME, Vickery AL, Jr., et al. loss of the retinoblastoma tumor-suppressor gene in parathyroid carcinoma. *N Engl J Med.* 1994;330(11):757-61. [[DOI:10.1056/NEJM199403173301105](https://doi.org/10.1056/NEJM199403173301105)] [[PMID](#)]
85. Dotzenrath C, Teh BT, Farnebo F, Cupisti K, Svensson A, Toell A, et al. Allelic loss of the retinoblastoma tumor suppressor gene: a marker for aggressive parathyroid tumors? *J Clin Endocrinol Metab.* 1996;81(9):3194-6. [[DOI:10.1210/jcem.81.9.8784068](https://doi.org/10.1210/jcem.81.9.8784068)] [[PMID](#)]
86. Bergero N, De Pompa R, Sacerdote C, Gasparri G, Volante M, Bussolati G, et al. Galectin-3 expression in parathyroid carcinoma: immunohistochemical study of 26 cases. *Hum Pathol.* 2005;36(8):908-14. [[DOI:10.1016/j.humpath.2005.06.020](https://doi.org/10.1016/j.humpath.2005.06.020)] [[PMID](#)]
87. Verdelli C, Forno I, Vaira V, Corbetta S. MicroRNA deregulation in parathyroid tumours suggests an embryonic signature. *J Endocrinol Invest.* 2015;38(4):383-8. [[DOI:10.1007/s40618-014-0234-y](https://doi.org/10.1007/s40618-014-0234-y)] [[PMID](#)]
88. Corbetta S, Vaira V, Guarnieri V, Scillitani A, Eller-Vainicher C, Ferrero S, et al. Differential expression of microRNAs in human parathyroid carcinomas compared with normal parathyroid tissue. *Endocr Relat Cancer.* 2010;17(1):135-46. [[DOI:10.1677/ERC-09-0134](https://doi.org/10.1677/ERC-09-0134)] [[PMID](#)]
89. Westin G, Bjorklund P, Akerstrom G. Molecular genetics of parathyroid disease. *World J Surg.* 2009;33(11):2224-33. [[DOI:10.1007/s00268-009-0022-6](https://doi.org/10.1007/s00268-009-0022-6)] [[PMID](#)]
90. Björklund P, Lindberg D, Åkerström G, Westin G. Stabilizing mutation of CTNNB1/beta-catenin and protein accumulation analyzed in a large series of parathyroid tumors of Swedish patients. *Mol Cancer.* 2008;7(1):53. [[DOI:10.1186/1476-4598-7-53](https://doi.org/10.1186/1476-4598-7-53)] [[PMID](#)] [[PMCID](#)]
91. Björklund P, Åkerström Gr, Westin G. Accumulation of nonphosphorylated β -catenin and c-myc in primary and uremic secondary hyperparathyroid tumors. *J Clin Endocrinol Metab.* 2007;92(1):338-44. [[DOI:10.1210/jc.2006-1197](https://doi.org/10.1210/jc.2006-1197)] [[PMID](#)]
92. Semba S, Kusumi R, Moriya T, Sasano H. Nuclear Accumulation of B-Catenin in Human Endocrine Tumors: Association with Ki-67 (MIB-1) Proliferative Activity. *Endocr Pathol.* 2000;11(3):243-50. [[DOI:10.1385/EP:11:3:243](https://doi.org/10.1385/EP:11:3:243)]
93. Haven CJ, Howell VM, Eilers PH, Dunne R, Takahashi M, van Puijenbroek M, et al. Gene expression of parathyroid tumors: molecular subclassification and identification of the potential malignant phenotype. *Cancer Res.* 2004;64(20):7405-11. [[DOI:10.1158/0008-5472.CAN-04-2063](https://doi.org/10.1158/0008-5472.CAN-04-2063)] [[PMID](#)]
94. DeLellis RA. Parathyroid tumors and related disorders. *Mod Pathol.* 2011;24 Suppl 2(S2):S78-93. [[DOI:10.1038/modpathol.2010.132](https://doi.org/10.1038/modpathol.2010.132)] [[PMID](#)]
95. Cetani F, Pinchera A, Pardi E, Cianferotti L, Vignali E, Picone A, et al. No evidence for mutations in the calcium-sensing receptor gene in sporadic parathyroid adenomas. *J Bone Miner Res.* 1999;14(6):878-82. [[DOI:10.1359/jbmr.1999.14.6.878](https://doi.org/10.1359/jbmr.1999.14.6.878)] [[PMID](#)]
96. Cetani F, Pardi E, Marcocci C. Parathyroid carcinoma. *Parathyroid Disorders.* 51: Karger Publishers; 2019. p. 63-76. [[DOI:10.1159/000491039](https://doi.org/10.1159/000491039)] [[PMID](#)]

97. Tahara H, Smith AP, Gaz RD, Zariwala M, Xiong Y, Arnold A. Parathyroid tumor suppressor on 1p: analysis of the p18 cyclin-dependent kinase inhibitor gene as a candidate. *J Bone Miner Res.* 1997;12(9):1330-4. [DOI:10.1359/jbmr.1997.12.9.1330] [PMID]
98. Carling T, Du Y, Fang W, Correa P, Huang S. Intragenic allelic loss and promoter hypermethylation of the RIZ1 tumor suppressor gene in parathyroid tumors and pheochromocytomas. *Surgery.* 2003;134(6):932-9; discussion 9-40. [DOI:10.1016/S0039-6060(03)00422-7]
99. Sulaiman L, Haglund F, Hashemi J, Obara T, Nordenstrom J, Larsson C, et al. Genome-wide and locus specific alterations in CDC73/HRPT2-mutated parathyroid tumors. *PloS one.* 2012;7(9):e46325. [PMID] [PMCID] [DOI:10.1371/journal.pone.0046325]
100. Agarwal SK, Schrock E, Kester MB, Burns AL, Heffess CS, Ried T, et al. Comparative genomic hybridization analysis of human parathyroid tumors. *Cancer Genet Cytogenet.* 1998;106(1):30-6. [DOI:10.1016/S0165-4608(98)00049-1]
101. Erovic BM, Harris L, Jamali M, Goldstein DP, Irish JC, Asa SL, et al. Biomarkers of parathyroid carcinoma. *Endocr Pathol.* 2012;23(4):221-31. [DOI:10.1007/s12022-012-9222-y] [PMID]
102. Kelly TG, Shattuck TM, Reyes-Mugica M, Stewart AF, Simonds WF, Udelsman R, et al. Surveillance for early detection of aggressive parathyroid disease: carcinoma and atypical adenoma in familial isolated hyperparathyroidism associated with a germline HRPT2 mutation. *J Bone Miner Res.* 2006;21(10):1666-71. [DOI:10.1359/jbmr.060702] [PMID]
103. Schulte KM, Talat N. Diagnosis and management of parathyroid cancer. *Nat Rev Endocrinol.* 2012;8(10):612-22. [DOI:10.1038/nrendo.2012.102] [PMID]
104. Palanisamy N, Imanishi Y, Rao PH, Tahara H, Chaganti RS, Arnold A. Novel chromosomal abnormalities identified by comparative genomic hybridization in parathyroid adenomas. *J Clin Endocrinol Metab.* 1998;83(5):1766-70. [DOI:10.1210/jc.83.5.1766] [PMID]
105. Truran PP, Johnson SJ, Bliss RD, Lennard TW, Aspinall SR. Parafibromin, galectin-3, PGP9. 5, Ki67, and cyclin D1: using an immunohistochemical panel to aid in the diagnosis of parathyroid cancer. *World J Surg.* 2014;38(11):2845-54. [DOI:10.1007/s00268-014-2700-2] [PMID]
106. Vargas MP, Vargas HI, Kleiner DE, Merino MJ. The role of prognostic markers (MiB-1, RB, and bcl-2) in the diagnosis of parathyroid tumors. *Mod Pathol.* 1997;10(1):12-7.
107. Lal G, Padmanabha L, Smith BJ, Nicholson RM, Howe JR, O'Dorisio MS, et al. RIZ1 is epigenetically inactivated by promoter hypermethylation in thyroid carcinoma. *Cancer.* 2006;107(12):2752-9. [DOI:10.1002/cncr.22325] [PMID]
108. Verdelli C, Forno I, Vaira V, Corbetta S. Epigenetic alterations in human parathyroid tumors. *Endocrine.* 2015;49(2):324-32. [DOI:10.1007/s12020-015-0555-4] [PMID]
109. Rahbari R, Holloway AK, He M, Khanafshar E, Clark OH, Kebebew E. Identification of differentially expressed microRNA in parathyroid tumors. *Ann Surg Oncol.* 2011;18(4):1158-65. [DOI:10.1245/s10434-010-1359-7] [PMID] [PMCID]
110. Wielogórska M, Podgórska B, Niemira M, Szelachowska M, Krętowski A, Siewko K. MicroRNA Profile Alterations in Parathyroid Carcinoma: Latest Updates and Perspectives. *Cancers.* 2022;14(4):876. [PMID] [PMCID] [DOI:10.3390/cancers14040876]
111. Vaira V, Elli F, Forno I, Guarnieri V, Verdelli C, Ferrero S, et al. The microRNA cluster C19MC is deregulated in parathyroid tumours. *J Mol Endocrinol.* 2012;49(2):115-24. [DOI:10.1530/JME-11-0189] [PMID]
112. Cromer MK, Starker LF, Choi M, Udelsman R, Nelson-Williams C, Lifton RP, et al. Identification of somatic mutations in parathyroid tumors using whole-exome sequencing. *J Clin Endocrinol Metab.* 2012;97(9):E1774-E81. [DOI:10.1210/jc.2012-1743] [PMID] [PMCID]
113. Svedlund J, Koskinen Edblom S, Marquez VE, Akerstrom G, Bjorklund P, Westin G. Hypermethylated in cancer 1 (HIC1), a tumor suppressor gene epigenetically deregulated in hyperparathyroid tumors by histone H3 lysine modification. *J Clin Endocrinol Metab.* 2012;97(7):E1307-15. [DOI:10.1210/jc.2011-3136] [PMID]
114. Rodríguez-Rodero S, Delgado-Álvarez E, Fernández AF, Fernández-Morera JL, Menéndez-Torre E, Fraga MF. Epigenetic alterations in endocrine-related cancer. *Endocr Relat Cancer.* 2014;21(4):R319-R30. [DOI:10.1530/ERC-13-0070] [PMID]
115. Juhlin CC, Kiss NB, Villablanca A, Haglund F, Nordenstrom J, Hoog A, et al. Frequent promoter hypermethylation of the APC and RASSF1A tumour suppressors in parathyroid tumours. *PloS one.* 2010;5(3):e9472. [PMID] [PMCID] [DOI:10.1371/journal.pone.0009472]
116. Svedlund J, Aurén M, Sundström M, Dralle H, Åkerström G, Björklund P, et al. Aberrant WNT/β-

- catenin signaling in parathyroid carcinoma. *Mol Cancer*. 2010;9(1):1. [[DOI:10.1186/1476-4598-9-294](https://doi.org/10.1186/1476-4598-9-294)] [[PMID](#)] [[PMCID](#)]
117. Dwight T, Nelson AE, Theodosopoulos G, Richardson AL, Learoyd DL, Philips J, et al. Independent genetic events associated with the development of multiple parathyroid tumors in patients with primary hyperparathyroidism. *Am J Pathol*. 2002;161(4):1299-306. [[DOI:10.1016/S0002-9440\(10\)64406-9](https://doi.org/10.1016/S0002-9440(10)64406-9)]
118. Hahn MA, Howell VM, Gill AJ, Clarkson A, Weaire-Buchanan G, Robinson BG, et al. CDC73/HRPT2 CpG island hypermethylation and mutation of 5'-untranslated sequence are uncommon mechanisms of silencing parafibromin in parathyroid tumors. *Endocr Relat Cancer*. 2010;17(1):273-82. [[DOI:10.1677/ERC-09-0291](https://doi.org/10.1677/ERC-09-0291)] [[PMID](#)]
119. Conti de Freitas LC, Castilho RM, Squarize CH. Histone Modification on Parathyroid Tumors: A Review of Epigenetics. *Int J Mol Sci*. 2022;23(10):5378. [[DOI:10.3390/ijms23105378](https://doi.org/10.3390/ijms23105378)] [[PMID](#)] [[PMCID](#)]
120. Svedlund J, Aurén M, Sundström M, Dralle H, Åkerström G, Björklund P, et al. Aberrant WNT/ β -catenin signaling in parathyroid carcinoma. *Molecular cancer*. 2010;9(1):294. [[PMID](#)] [[PMCID](#)] [[DOI:10.1186/1476-4598-9-294](https://doi.org/10.1186/1476-4598-9-294)]
121. Juhlin CC, Haglund F, Villablanca A, Forsberg L, Sandelin K, Branstrom R, et al. loss of expression for the Wnt pathway components adenomatous polyposis coli and glycogen synthase kinase 3-beta in parathyroid carcinomas. *Int J Oncol*. 2009;34(2):481-92.
122. Cetani F, Ambrogini E, Viacava P, Pardi E, Fanelli G, Naccarato AG, et al. Should parafibromin staining replace HRPT2 gene analysis as an additional tool for histologic diagnosis of parathyroid carcinoma? *Eur J Endocrinol*. 2007;156(5):547-54. [[DOI:10.1530/EJE-06-0720](https://doi.org/10.1530/EJE-06-0720)] [[PMID](#)]
123. Duan K, Mete O. Parathyroid Carcinoma: Diagnosis and Clinical Implications. *Turk Patoloji Derg*. 2015;31 Suppl 1:80-97. [[DOI:10.5146/tjpath.2015.01316](https://doi.org/10.5146/tjpath.2015.01316)] [[PMID](#)]
124. Fernandez-Ranvier GG, Khanafshar E, Tacha D, Wong M, Kebebew E, Duh QY, et al. Defining a molecular phenotype for benign and malignant parathyroid tumors. *Cancer*. 2009;115(2):334-44. [[DOI:10.1002/cncr.24037](https://doi.org/10.1002/cncr.24037)] [[PMID](#)]
125. Sharretts JM, Kebebew E, Simonds WF, editors. Parathyroid cancer. *Seminars in oncology*; 2010: Elsevier. [[DOI:10.1053/j.seminoncol.2010.10.013](https://doi.org/10.1053/j.seminoncol.2010.10.013)] [[PMID](#)] [[PMCID](#)]

How to Cite This Article

Miratashi Yazdi S A, Nazar E. Genetic and Epigenetic Alterations in Parathyroid Neoplasms. *Iran J Pathol*. 2022; 17(4): 395-405. doi: 10.30699/ijp.2022.551233.2865