

A Case of Premenopausal Uterine Leiomyoma, Non-cirrhotic Portal Fibrosis, Hepatic Koch's, a PET Gone Astray-Morphology Antidotes a Confounding Concoction

Kavita Gaur¹ , Shailaja Shukla^{1*} , Shinjini Choudhury¹ , Pankaj Raj¹ , Sharda Patra² 

1. Department of Pathology, Lady Hardinge Medical College, Shaheed Bhagat Singh Marg, New Delhi, India
2. Department of Obstetrics and Gynaecology Lady Hardinge Medical College, Shaheed Bhagat Singh Marg, New Delhi, India

KEYWORDS

Fibrosis, Leiomyoma, Liver, Positron emission tomography, Uterus

Scan to discover online



Main Subjects:
Gynecologic Pathology

Received 03 Oct 2021;

Accepted 21 Dec 2022;

Published Online 08 Mar 2022;

[10.30699/IJP.2022.540258.2743](https://doi.org/10.30699/IJP.2022.540258.2743)

ABSTRACT

Uterine leiomyoma with hepatic vasculopathy, specifically non-cirrhotic portal fibrosis (NCPF), has hitherto been undescribed. NCPF is characterized by elevated portal pressure sans cirrhosis and has previously not been described in association with a gynecological pathology. We report the case of a female under evaluation for a heterogeneously enhancing intrauterine mass with multiple hepatic lesions with increased uptake of fluorodeoxyglucose on positron emission analysis. Fibrosan values were increased. Histopathologic evaluations revealed a leiomyoma with liver tissue showing tubercular granulomas, thin wispy fibrotic strands, and rounded portal tracts pointed to NCPF. No evidence of malignancy was seen. Metabolic imaging may be unreliable to distinguish between benign and malignant uterine pathology and granulomatous and malignant hepatic lesions. Elastography may also be ineffective in diagnosing the etiology of liver fibrosis. Histopathological analysis hence remains essential despite noninvasive tests. Further research is required on females afflicted with NCPF to exclude a hormonal link.

Corresponding Information:

Shailaja Shukla, Department of Pathology, Lady Hardinge Medical College, Shaheed Bhagat Singh Marg, New Delhi, India Email: shailajashukla@gmail.com

Copyright © 2022. This is an open-access article distributed under the terms of the Creative Commons Attribution- 4.0 International License which permits Share, copy and redistribution of the material in any medium or format or adapt, remix, transform, and build upon the material for any purpose, even commercially.

Introduction

Uterine leiomyomas are the most frequently occurring female pelvic tumors, often requiring surgical resection (1). The exact incidence or prevalence of liver disease associated with leiomyomas is unknown. Non-cirrhotic portal fibrosis (NCPF), a hepatic vascular disease of obscure etiology with infections and immunological factors, is suggested as a plausible trigger (2). It has previously not been documented in association with a gynecological pathology. We report a case clinically being evaluated for an intrauterine leiomyoma accompanied by splenomegaly and multiple hepatic lesions on routine imaging. F-18 fluorodeoxyglucose (FDG) - positron emission tomography (PET) scan of the hepatic lesions showed an increased metabolite uptake, strengthening the suspicion of malignancy. Histopathological evaluations revealed these as tubercular lesions in a backdrop of NCPF. This is the first documented report of uterine leiomyoma with hepatic tuberculosis and non-cirrhotic portal fibrosis to the best of our knowledge. This report assumes the importance

of clinical scenarios where coexistent infectious diseases may be present.

Case Presentation

A forty-five-year-old female (P4L4) presented with dull aching abdominal pain for one year associated with anorexia and no other complaints or prior treatment or drug history, including consumption of oral contraceptives. There was no family history of malignancy or tuberculosis. The patient was compliant with all scheduled vaccinations and had taken the BCG vaccination at birth. Menstrual and obstetric history was unremarkable. Clinical examination revealed a firm lump in the right lower abdomen extending to the pelvis 9 × 8 cm in size with hepatosplenomegaly. Investigations revealed moderate microcytic hypochromic anemia (Hemoglobin- 8.4 g/dl) and mildly deranged hepatic enzymes (SGOT-42 IU/L, SGPT-44 IU/L). A screening PPD test was also performed, which

showed an induration of 12 mm. Other investigations, including coagulation profile, routine hormone studies, autoimmune, viral, and tumor markers (CA-125 and alpha-fetoprotein) were unremarkable. The abdominal ultrasonogram showed a heterogeneously hyperechoic lesion in the endometrial cavity measuring 9.7 x 8 cm with profuse intra-lesional vascularity. The spleen was enlarged, measuring 12.74 cm with normal echogenicity. Contrast-enhanced computerized tomography (CECT) of the abdomen showed a well-defined heterogeneously enhancing midline mass lesion measuring 11.2 x 9.7 x 7.8 cm within the endometrial cavity, causing widening of the endometrial cavity and extending from L4 to S4, causing displacement of the bowel loops. Multiple ill-defined hypodense lesions were noted in the liver in the background of chronic liver disease. Intrahepatic biliary radicles were not dilated. The common bile duct and portal vein were unremarkable. PET scan showed a heterogeneously enhancing mass lesion within the endometrial cavity showing increased FDG uptake ([Figure 1a](#)) (maximal

standardized uptake value (SUV)-3.6), multiple hypodense hypermetabolic hepatic lesions (SUV-8.2) ([Figure 1b](#)) without ovarian involvement, lymphadenopathy/suspicious bone lesions. This was associated with non-FDG avid fibronodular lesions in both lungs and a non-FDG avid calcified nodule in the right lung lower lobe. Upper gastrointestinal endoscopy revealed grade two esophageal varices. The fibroscan value was elevated (22.0 KPa). A provisional clinical impression was made of the uterine mass lesion (? leiomyosarcoma) with hepatic metastases and chronic liver disease with portal hypertension. Endometrial biopsy showed proliferative endometrium. Subsequently, a total abdominal hysterectomy was performed with bilateral salpingo-oophorectomy with intraoperative hepatic wedge biopsy. Preoperatively, minimal straw-colored fluid was noted, which was taken for analysis from the bilateral paracolic gutters. Ascitic fluid cytology revealed only a few reactive mesothelial cells and occasional lymphocytes, sans evidence of malignancy.

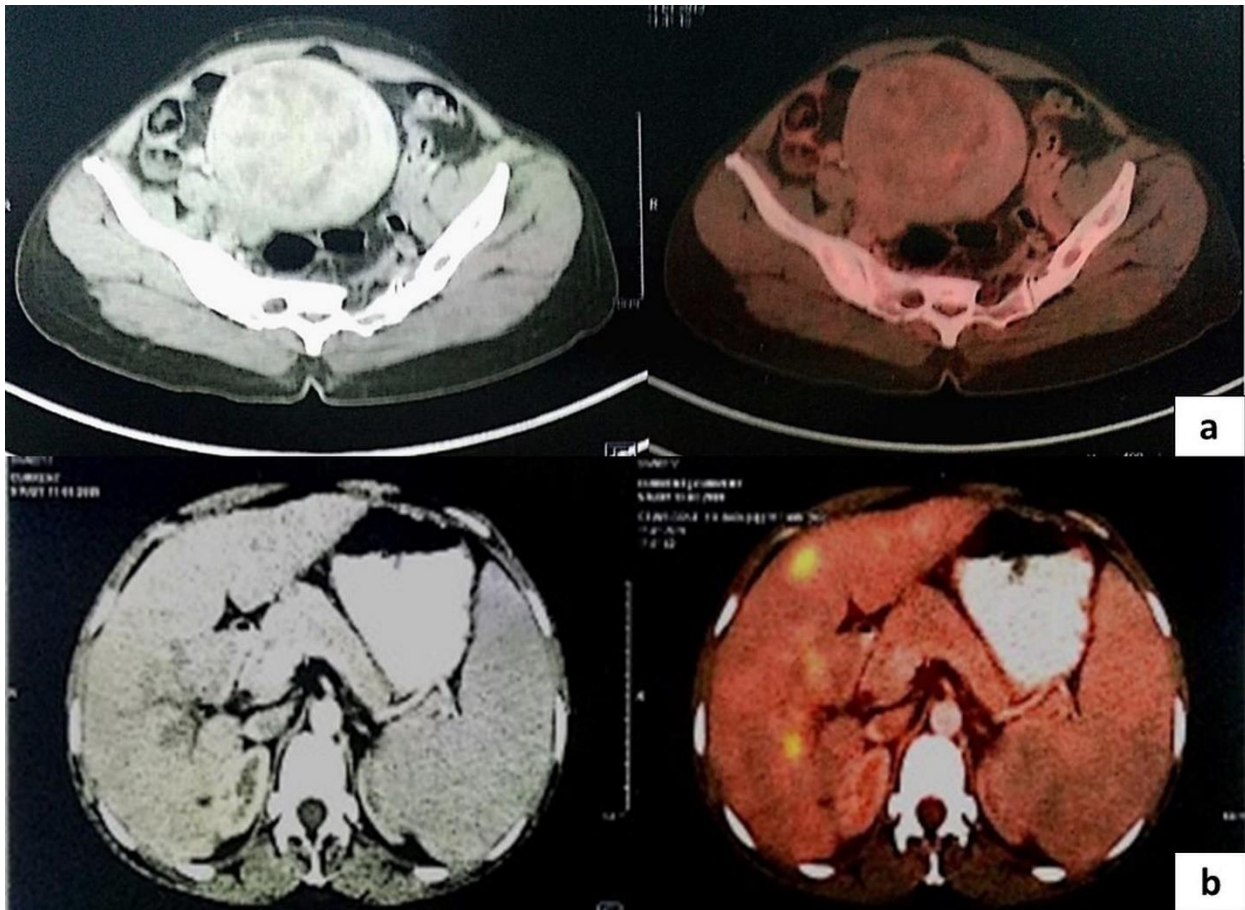


Fig. 1. a :PET scan showing a heterogeneously enhancing lesion in the endometrial cavity showing faint FDG uptake, abdominal computerized tomography (CT) image on the left showing a well- defined midline uterine mass lesion displacing bowel loops **b**: Multiple ill-defined hypodense hepatic lesions were noted on CT, hypermetabolic on PET

Frozen sections from the uterine lesion did not reveal any features suggesting malignancy ([Figure 2a](#)). Likewise, frozen sections from the liver showed unremarkable histology ([Figure 2b](#)). Grossly a grey-

white firm growth measuring 9 × 8 × 5 cm obliterating the endometrial cavity showing whorled areas devoid of any areas of hemorrhage or necrosis. The adnexa was unremarkable grossly, as was the separately sent

omentum. Histology of the uterine lesion demonstrated a large leiomyoma devoid of atypia necrosis /mitotic activity (Figure 2c). Biopsied ureterovesical fold and omental tissue were negative for malignancy (Figure 2d). Liver biopsy showed features of non-cirrhotic portal fibrosis, including venovenous approximation,

aberrant vascular channels, and rounded portal tracts (Figure 2 e-f) with numerous caseating and non-caseating granulomas (Figure 2 g-h), occasional showing positivity on Ziehl- Neelson's stain for acid-fast bacilli (Figure 2 h inset). No evidence of malignancy was noted.

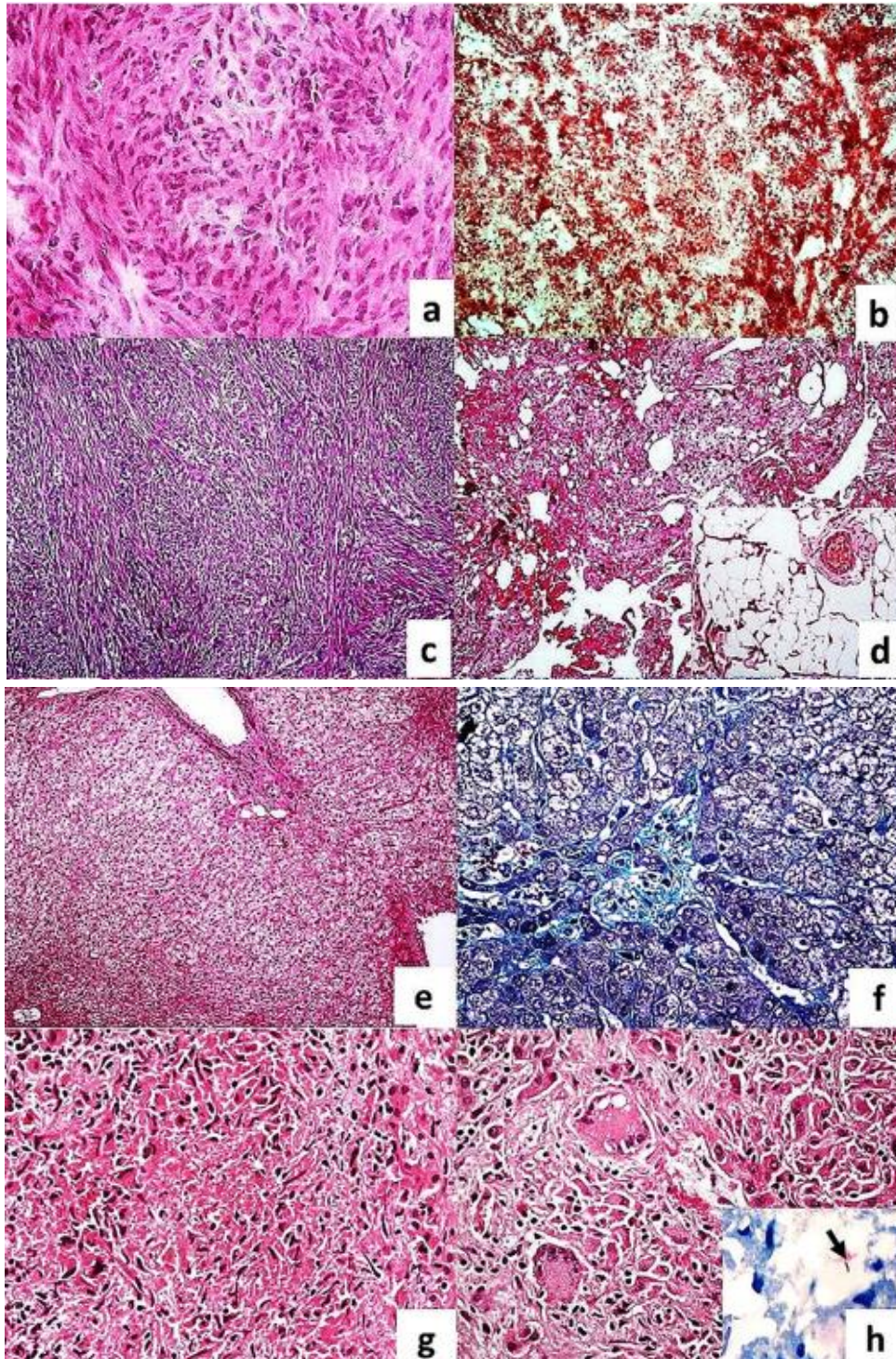


Fig. 2. a: Frozen sections from the uterine mass show a benign spindle cell lesion **b:** liver was free of tumour **c:** Paraffin section of uterus shows a leiomyoma **d:** Uterovesical fold & mesentery negative for malignancy (H&E, 100X). Liver biopsy showed features of non-cirrhotic portal fibrosis including **e:** venovenal approximation (H&E, 40X) and **f:** rounded portal tracts (Masson's trichrome, 400X) **g:** the hepatic parenchyma also showed caseating granulomas (H&E, 40X) with **h:** macrophages and giant cells, inset showing an acid fast bacillus (H & E, 40X; Ziehl-Neelson, 1000X)

Discussion

Leiomyoma of the uterus is a frequently encountered benign tumor in gynecological practice. Various factors have been implicated in its pathogenesis throughout the years, including injury, hypoxia, and inflammation (1). The role of estrogen has often been studied as a possible pathogenetic factor, with recent work examining the role of estrogen receptors and associated signaling pathways in tumorigenesis (3). Interestingly, the human liver, an estrogen sensitive organ, bearing estrogen receptors, has shown an unremarkable association with uterine disease states. An extensive literature search revealed uterine leiomyoma to be seldom associated with liver disease. Previous reports have documented an association with liver cirrhosis, focal nodular hyperplasia, and hepatic adenomas (4-6). The latter two entities, especially hepatic adenomas, have been specifically associated with oral contraceptive usage and represent common benign hepatic tumors. The association of leiomyoma with NCPF, a hepatic vasculopathy as seen herein, has hitherto not been described. NCPF, also referred to as idiopathic portal hypertension in Japan and hepatoportal sclerosis in the United States, is characterized by elevated portal pressure sans cirrhosis and obscure etiopathogenesis, infections, and immunity having presumable roles.

In this case, a PET scan was performed to study the increased intra-lesional vascularity in the intrauterine lesion and multiple hepatic lesions. Increased uptake of FDG led to a suspicion of leiomyosarcoma with hepatic metastases. Frozen sections from the resected uterine lesion revealed a benign spindle cell lesion, while the hepatic sections were unremarkable. Subsequent paraffin sections revealed this to be a benign leiomyoma, associated with multiple hepatic granulomatous lesions in a background of non-cirrhotic portal fibrosis characterized by rounded portal tracts, wispy fibrous spurs, and interrupted fibrous bridges (7). The presence of acid-fast bacilli confirmed the granulomas as tubercular. Granulomatous lesions in the liver are an uncommon cause of NCPF (2). Hepatic Koch's, in addition, is a rare entity, with the reported incidence being a meager 0.5 % of both local and disseminated tuberculosis (8).

In a study by Marks *et al.*, all three cases reported had hepatic adenomas associated with uterine leiomyomas. All patients had a prior history of consuming oral contraceptive pills with the growth of the hepatic lesions even after cessation of hormonal therapy (5). An earlier study by Porter *et al.* examined the presence of estrogen receptors in the normal human liver and found an increased expression in diseased states such as FNH and hepatic adenoma (6). Though we were unable to perform estrogen receptor status in our tissue examined, the absence of OCP intake or venous thrombosis and the histological evidence of tuberculosis in our patient explains the presence of NCPF.

From a clinical standpoint, it is interesting to note that both active tuberculosis and malignancy have a high uptake of FDG on imaging-based metabolic studies (9). This is possibly due to enhanced glycolytic activity of the monocyte-macrophage system seen in tuberculosis (10). Hence, active tuberculosis may masquerade as a malignancy on FDG-PET, as seen in this case. This may potentially delay and even misguide clinical management. Transient elastography (fibrosan) values were elevated, which may be a false positive result. This might be explained by the fibrosis accompanying the granulomas leading to increased hepatic stiffness.

Secondly, Nishizawa *et al.* demonstrated that leiomyomas with focal FDG uptake (SUV>3.0) were seen with a higher incidence in premenopausal women. The authors postulated copious cellularity and hormonal factors behind this (11). As there was no evidence herein to suggest hyperestrinism in our patient, the association of NCPF with the large leiomyomatous lesion noted in our case may be purely incidental. However, it may be worth noting that estrogen inhibits the hepatic stellate cells in animal models, the central player in hepatic fibrosis (12).

An interesting point to note is that data from Japan and the West have pointed to a female predilection for NCPF (13). Though our case is from South East Asia, it would be worthwhile to explore the hormonal status of large cohorts of afflicted females to ascertain if there is any hormonal etiology for the disease. In this context, the present report may be of importance as future research in this direction would essentially be spearheaded by the gynecological pathologist in close collaboration with clinical teams.

Our patient had a non-vegetarian diet, another plausible area for further study to explore, focusing on the link between the effects of dietary phytoestrogens and the causation of leiomyoma with hepatic disease, can be considered. However, leiomyoma is a common entity and can be seen with other pathologies. This article highlights the unusual synchronicity of fibroid with NCPF and tuberculosis that has hitherto not yet been documented.

Conclusion

The association between uterine leiomyoma and non-cirrhotic portal hypertension is infrequent. For the clinician, it is essential to note that metabolic imaging is unreliable to distinguish between malignant and infectious pathology, especially in tuberculosis. Tissue-based diagnosis by the gynecological pathologist is imperative, more so in regions where infectious disease is common, as the actual diagnosis may be different yet be amenable to treatment. Larger cohorts examining the incidence of benign and malignant uterine lesions in cases of NCPF may be

planned to ascertain a hormonal etiology for the same if any.

Statement of Ethics

The present work was performed after taking informed consent from the patient, and a sincere effort has been made to uphold patient confidentiality y.

Acknowledgments

None.

Conflict of Interest

The authors have no conflicts of interest to declare.

References

- Williams AR. Uterine fibroids—what's new?. *F1000Research*. 2017;6. [DOI:10.12688/f1000research.12172.1] [PMID] [PMCID]
- Sarin SK, Philips CA, Khanna R. Noncirrhotic portal hypertension: medical and endoscopic management. *Clin Liver Dis*. 2015;6(5):107. [DOI:10.1002/cl.511] [PMID] [PMCID]
- Borahay MA, Asoglu MR, Mas A, Adam S, Kilic GS, Al-Hendy A. Estrogen receptors and signaling in fibroids: role in pathobiology and therapeutic implications. *Reprod Sci*. 2017;24(9):1235-44. [DOI:10.1177/1933719116678686] [PMID] [PMCID]
- Chawla CD, Chaudhary MS, Joneja GS, Bugga A. Fibroid uterus an unusual presentation: a case report. *Med J Armed Forces India* 1995 ; 51(3):218-19. [DOI:10.1016/S0377-1237(17)30971-1]
- Marks WH, Thompson N, Appleman H. Failure of hepatic adenomas (HCA) to regress after discontinuance of oral contraceptives. An association with focal nodular hyperplasia (FNH) and uterine leiomyoma. *Ann Surg* 1988; 208(2):190-95. [DOI:10.1097/0000658-198808000-00010] [PMID] [PMCID]
- Porter LE, Elm MS, Van Thiel DH, Eagon PK. Hepatic estrogen receptor in human liver disease. *Gastroenterology* 1987; 92(3):735-45. [DOI:10.1016/0016-5085(87)90026-6]
- Gaur K, Ali S, Sakhuja P, Majumdar K, Agarwal A, Puri A. Is non cirrhotic portal fibrosis actually cirrhosis in regression? A histopathological study of the "Hepatic repair complex" in Indian patients. *J Clin Exp Hepatol* 2016; 6:S97. [DOI:10.1016/j.jceh.2016.06.163]
- Meena M, Dixit R, Meena LP, Samaria JK. Primary/local hepatic tuberculosis without dissemination. *BMJ Case Rep* 2015; 2015:bcr2014206974. [DOI:10.1136/bcr-2014-206974] [PMID] [PMCID]
- Heysell SK, Thomas TA, Sifri CD, Rehm PK, Houpt ER. 18-Fluorodeoxyglucose positron emission tomography for tuberculosis diagnosis and management: a case series. *BMC Pulm Med* 2013; 13:14. [DOI:10.1186/1471-2466-13-14] [PMID] [PMCID]
- Choi JY, Jhun BW, Hyun SH, Chung MJ, Koh WJ. 18 FDG positron emission tomography/ computed tomography for assessing treatment of pulmonary multidrug resistant tuberculosis . *J Clin Med* 2018; 7(12):599. [DOI:10.3390/jcm7120559] [PMID] [PMCID]
- Nishizawa S, Inubushi M, Kido A, et al. Incidence and characteristics of uterine leiomyomas with FDG uptake. *Ann Nucl Med* 2008; 22(9):803-10. [DOI:10.1007/s12149-008-0184-6] [PMID]
- Yasuda M , Shimizu I, Shiba M, Ito S. Suppressive effects of estradiol on dimethylnitrosamine-induced fibrosis of the liver in rats. *Hepatology* 1999; 29(3):719-27. [DOI:10.1002/hep.510290307] [PMID]
- Khanna R, Sarin SK. Idiopathic portal hypertension and extrahepatic portal venous obstruction. *Hepatol Int* 2018 ;12(1):148-67. [DOI:10.1007/s12072-018-9844-3] [PMID]

How to Cite This Article

Kavita, G, Shailaja, SH, Shinjini, CH, Pankaj, R, Sharda, P. A Case of Premenopausal Uterine Leiomyoma, Non-cirrhotic Portal Fibrosis, Hepatic Koch's, a PET Gone Astray-Morphology Antidotes a Confounding Concoction. *Iran J Pathol*, 2022; 17(2): 229-3. doi: 10.30699/IJP.2022.540258.2743