

Original Article

Comparative Study of Clinical Staging of Oral Submucous Fibrosis with Qualitative Analysis of Collagen Fibers Under Polarized Microscopy

Neha Modak, Sandhya Tamgadge, Avinash Tamgadge, Sudhir Bhalerao

*Dept. of Oral Pathology and Microbiology, Padm. Dr. D. Y. Patil Dental College and Hospital,
Navi Mumbai, India*

ABSTRACT

Background & Objectives: Oral submucous fibrosis (OSMF) is a condition where excessive deposition of dense collagen fibers occurred in the connective tissue of oral mucosa. An alteration of collagen necessitates an in depth understanding of collagen in oral tissues as no breakthrough studies have been reported. Therefore the aim was to correlate the clinical, functional and histopathological staging and to analyze the polarization colors and thickness of the collagen fibers in different stages of OSMF using picosirius red stain under polarizing microscopy so as to assess the severity of disease.

Methods: The study was conducted in the department of Oral Pathology and Microbiology at Padm. Dr. D. Y Patil Dental and Hospital, Navi Mumbai, India (2012-13). A sample size was of a total 40 subjects, of which 30 patients had OSMF, and 10 were in control group. Clinical, functional and histopathological staging were done depending upon definite criteria. Collagen fibers were analyzed for polarizing colors and thickness. Further clinical, functional and histopathological stages as well as qualitative parameters of collagen fibers were compared.

Results: The correlation between clinical and functional staging was not significant ($P > 0.05$) whereas the comparison of the functional staging with histopathological staging was more reliable ($P < 0.01$) as an indication to the severity of the disease rather than clinical staging. One-way ANOVA analysis showed highly significant correlation between functional staging and polarization colors and thickness of collagen fibers ($P < 0.001$).

Conclusion: The qualitative change in the collagen fibers of OSMF patients using polarized microscopy would help to assess its role in diagnostic evaluation, to determine the prognosis of the disease as well as to provide useful predictive treatment modalities to them.

Keywords: OSMF, Polarization Colors, Collagen Thickness, Picosirius Red Stain, Polarizing Microscope.

Received: 10 Jan 2014

Accepted: 08 Jun 2014

Address Communications to: Dr. Neha Modak, Department of Oral Pathology and Microbiology, Padm. Dr. D. Y. Patil Dental College and Hospital, Navi Mumbai, India

Email: nehamodak32@yahoo.com

Introduction

Oral submucous Fibrosis (OSMF) is considered as a premalignant and crippling condition of oral mucosa (1). Pindborg (1966) defined OSMF as “an insidious, chronic disease affecting any part of oral cavity and sometimes the pharynx. Although occasionally preceded by and / or associated with vesicle formation, it is always associated with a juxta-epithelial inflammatory reaction followed by a fibro-elastic change of the lamina propria, with epithelial atrophy, leading to stiffness of the oral mucosa, causing trismus and inability to eat”(2).

As OSMF is a condition causing fibrosis of the oral mucosa, the connective tissue changes are characterized by deposition of dense collagen fibers in the oral mucosa. An alteration of collagen in this disease necessitates an in depth understanding of various types of collagen in oral tissues and its intimate relationship to other constituents of the connective tissue components. The study of collagen highlights the current knowledge of collagen biosynthesis and degradation, which is a complex mechanism. The direct involvement of collagen in the pathophysiology of diseases has been established in only a limited number of conditions (3).

Varieties of dye materials are available to stain collagen for histological studies, but picosirius red stain was found to be the best than any other types of stains. It stained finer collagen fibers more intensely and improved their birefringence property (4). It was also observed that Sirius red stains are more stable and do not fade easily when compared to other stains (5). Picosirius red staining followed by polarizing microscopy can selectively demonstrate collagen. The differences in polarization colors are caused by fiber thickness as well as by packing of collagen. Examination of collagen fibers of

varying thickness can differentiate procollagen, intermediate collagen and pathological collagen fibers by determining the polarization colors of the collagen (6).

Extensive studies have been done by various workers on epidemiology, etiological factors, clinical parameters and histopathology in OSMF across the globe, but no breakthrough has been reported. Even the correlation between clinical staging of mouth opening and histological grading of fibrosis did not show any statistical significance (7).

Therefore the purpose of the present study is to correlate the clinico-functional staging with the qualitative analysis of the collagen fibers in OSMF to assess the severity of this disease.

Materials and Methods

The study group consisted of 30 patients of clinically and histopathologically diagnosed as Oral submucous fibrosis and 10 healthy controls to study the normal mucosa.

Inclusion criteria: Patients who were using arecanut and arecanut containing products, tobacco in different forms (smoke, smokeless), alcohol for many months to years and who were clinically exhibiting the signs and symptoms of OSMF were included in the study.

Exclusion criteria: Subjects suffering from chronic systemic illness like hypertension and diabetes were excluded from the present study.

Ethical clearance and written informed consent was obtained from both the experimental group and control group.

The patient's personal history was recorded with chewing habits, frequency duration of chewing and the brand used. Symptoms like burning sensation, restricted mouth opening, difficulty in swallowing and speech and their duration was noted.

Clinical and functional staging of OSMF was

recorded according to the guidelines given by Haider S.M., Merchant A.T., et al (2000). (8)

- Clinical staging was recorded according to the presence of palpable fibrous bands in various sites.

I. Faucial bands only

II. Faucial and buccal bands only

III. Faucial, buccal, and labial bands

- Functional staging was recorded measuring the mouth opening with vernier caliper from the mesio-incisal angle of upper central incisor to the lower central incisor.

A – Mouth opening ≥ 20 mm

B – Mouth opening 11 – 19 mm

C – Mouth opening ≤ 10 mm.

Hematoxylin and Eosin sections of 5 μm were used for histological staging of all the cases and were categorized into 4 different stages depending on the severity of the disease.

After the histological staging, the serial sections of the same thickness were stained with picosirius red stain to evaluate polarizing Colors by using polarizing microscope. The polarization Colors were then determined separately for thin and thick fibers based on the different polarization Colors and recorded. All images were then clicked under oil immersion ($\times 100$) and fiber thickness was measured using image analysis software version of Leica research microscope (Model No. DM1000LED).

A total of 5 high power ($\times 100$) fields were selected from the sections. At least 25 fibers, which were well discernible and distinct in each section, were randomly selected from subepithelial region and deep in the connective tissue for evaluation. The same procedure was adopted for the control group. Considering the variable thickness of normal mucosal collagen fibers as 0.8-2.4 μm , the collagen fibre thickness of 0.8 μm and less were considered as thin fibers and those above 0.8 μm

and in between 1.2-2.4 μm were considered as thick fibers. The polarizing Colors and thickness of the collagen fibers in various histopathological stages were determined by two independent observers to minimize the subjectivity. Further statistical analysis was done to derive the results.

Statistical Analysis

Categorical data were analyzed by Chi-square test, multiple group comparisons were made by one way analysis of variance (ANOVA) followed by student's t-test for pair wise comparisons. For all the tests, a *P*-value of 0.05 or less was considered for statistical significance.

Results

In the present study, one of the aims was to correlate clinical findings with histopathological staging. Maximum patients were from the age group of 21-30 years with male predominance and were showing burning sensation and difficulty in mouth opening as a chief complaint due to consumption of either gutkha alone or their combinations. In the study, there was not a definite trend as ($P > 0.05$) shown in with cases having the lesion in faucial fibrous bands (stage1) exhibiting the mild restriction in mouth opening (stage A) and those in stage 3 (faucial, buccal and labial fibrous bands) presenting sever restricted mouth opening (stage C).

Statistical analysis of correlation of clinical and functional staging with Chi square test ($X^2=5.689$, $P= 0.058$) was not significant. The comparison of functional staging with histopathological staging was of importance with significant $P < 0.01$ when compared to clinical staging. When tissues were stained with polarized microscopy, it was observed that, there was considerable decrease in greenish yellow polarization color in thin

collagen fibers (Fig.1) while significant increased in the intensity of orange red-to-red color in thick collagen fibers as the stages advanced (Fig.2). Statistical analysis between groups with Chi-square test also showed high significance with P value < 0.001. Similarly there was decrease in thickness of thin collagen fibers while increase in thickness of thick collagen fibers as stages




Fig. 1: Picrosirius Red Stain showing predominant greenish yellow and few yellow orange color of collagen fibers in very early stage of OSMF ($\times 40$) under polarized microscopy

advanced (Fig.3, Fig.4).

Comparison of clinical staging with the polarization colors as well as thickness of collagen fibers did not show significant statistical analysis (Table1) while highly significant correlation observed between functional staging with polarization color and mean thickness of collagen fibers (Table 2).

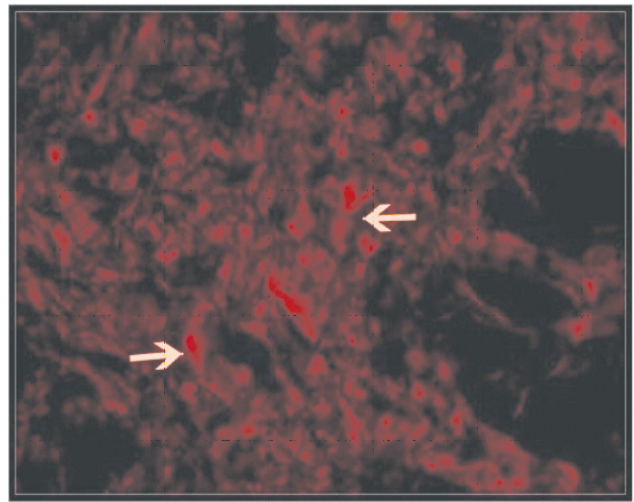


Fig. 2: Picrosirius Red Stain showing predominantly orange red to red polarizing Colors of collagen fibers in advanced Stage of OSMF ($\times 40$) under polarized microscopy

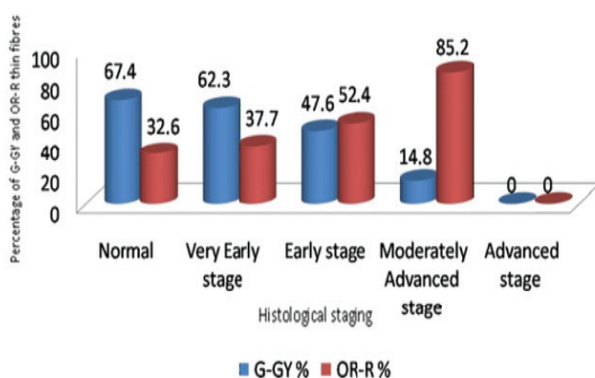


Fig. 3: Percentage wise distribution of Histological staging between G-GY and OR-R thin fibers with chi square $\chi^2 = 29.903$, $P = 0.000$; highly significant. (G- Green; GY- Greenish Yellow; OR- Orange Red, R- Red)

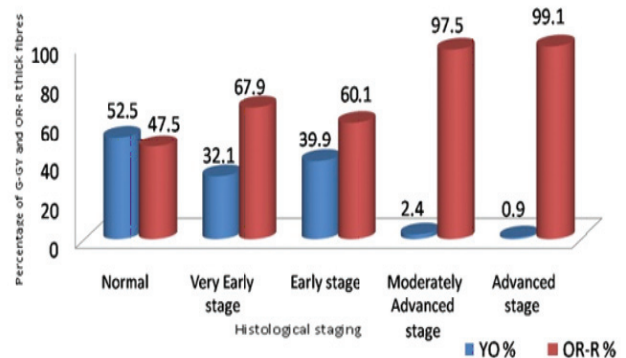


Fig. 4: Percentage wise distribution of Histological staging between YO and OR-R thick fibers with $\chi^2 = 225.721$, $P = 0.000$; highly significant

Table 1- Comparison of clinical staging with polarization Colors and mean thickness of collagen fibers

Clinical Staging	No of cases	Polarization color of collagen fibers				Clinical staging	No of cases	Thickness of collagen fibers in μm	
		Thin fibers		Thick fibers				Thin fibers (mean)	Thick fibers (mean)
		(mean)	(mean)	(mean)	(mean)				
		G-GY	OR-R	YO	OR-R				
I	Nil	Nil	Nil	Nil	Nil	I	Nil	Nil	Nil
II	16	3.6	3.6	4.8	13.0	II	16	0.326	0.962
III	14	3.1	4.0	2.8	15.1	III	14	0.298	1.163
Total	30	6.7	7.6	7.6	28.1	Total	30	0.624	2.125
t-test for Equality of Means		t=0.437 P=0.66	t= 0.315 P=0.755	t= 1.305 P=0.202	t= 0.258 P= 0.799	t-test for Equality of Means		t= 0.443 P=0.661	t=0.443 P=0.661

Not significant

Not significant

Table 2- Comparison of functional staging with polarization colors and thickness of collagen fibers

Functional staging	No of cases	Polarization color of collagen fibers				Functional staging	No of cases	Thickness of collagen fibers	
		Thin fibers		Thick fibers				Thin fibers (mean)	Thick fibers (mean)
		(mean)	(mean)	(mean)	(mean)				
		G-GY	OR-R	YO	OR-R				
Stage A ($\geq 20\text{mm}$)	23	4.3 (52.4%)	3.9 (47.6%)	3.5 (20.7%)	13.3 (79.3%)	Stage A ($\geq 20\text{mm}$)	23	0.315	1.042
Stage B (11-19mm)	6	3.5 (51.2%)	4.2 (48.8%)	5.7 (32.7%)	11.6 (67.3%)	Stage B (11-19mm)	6	0.358	1.060
Stage C ($\leq 10\text{mm}$)	1	0	0	1 (4%)	24 (96%)	Stage C ($\leq 10\text{mm}$)	1	0	1.327
Total	30	7.8	8.1	10.2	48.9	Total	30	0.673	3.429
ANOVA, F*	P-value	F=0.383 P=0.008	F=0.737 P=0.009	F=0.891 P=0.008	F=0.968 P=0.009			F=0.607 P=0.000	F=0.607 P=0.000
Difference Between Groups**		Highly significant						Highly significant	Highly significant

* One way ANOVA

** Student's *t*-test

Discussion

The oral mucous membrane is a unique tissue which is continuously exposed to various stresses such as heat, cold, microorganisms, chemicals and mechanical irritants in the process of food intake. In response to these stresses, both epithelium and connective tissue layers of the oral mucosa also exhibit acute and chronic reactive changes (9). OSMF is multifactorial condition includes areca nut, ingestion of chilies, genetic and immunologic processes, nutritional deficiency in the form of B complex, iron deficiency and malnutrition which

derange the repair of the inflamed oral mucosa, leading to defective healing and resultant scarring (10, 11). Out of them Areca nut considered to be the most important etiological factor in OSMF (12- 14). It was then concluded that once betel nut chewing habit had induced OSMF, reversal of the disease after cessation of the habit could not occur and that all the clinical and histological features remained the same (15). Recently all areca nut products are associated with OSMF, with the risk being greatest for pan masala which is having addictive and psychoactive property (16-19).

The pathogenesis and treatment of oral submucous fibrosis has been a subject of controversy, ever since Schwartz described the condition in 1952 (20). Pathogenesis of OSMF includes the areca alkaloids such as arecoline, arecadine, guvacoline and guvacine, out of which arecoline is the main agent responsible for fibroblast proliferation and causes elevated collagen synthesis by OSMF fibroblasts compared to normal fibroblast (3). Areca flavonoids tannins and catechins can cause increased fibrosis by forming a more stable and non soluble collagen structure by inhibiting collagenase enzyme activity. Elevated vimentin expression stimulated by arecoline in OSMF may be suggestive of transformational changes in buccal fibroblasts of OSMF patients. In OSMF, the reduction of phagocytic activity is inversely dose dependent to levels of arecoline, safrole and nicotine in saliva. The epidemiology of OSMF strongly suggests an individual susceptibility which could be cytokine based, especially as initial feature of OSMF is chronic inflammation accompanied by fibrosis.

Increased collagen synthesis is by:

- Activation of procollagen gene
 - Elevation of procollagen proteinase levels
 - Upregulation of lysyl oxidase activity due to high intake of copper through areca nut chewing
- Decreased collagen degradation is by:

- Activation of TIMPs (tissue inhibitor of matrix proteinases) gene. TIMPs gene inhibits activated collagenase which decreases the collagenase activity.
- Activation of plasminogen activator inhibitor (PAI). PAI prevents conversion of plasminogen to plasmin, which is required for conversion of procollagenase to collagenase.

To date there has been no consensus regarding the effective management of the disease and many types of treatment have been carried out to combat this disease, which affects considerable number of people in India, South East Asia and other parts

of the world (3). Morphologic and morphometric studies of collagen in various diseases have been attempted by many researchers in the medical field. However such studies are indeed rare as far as OSMF is concerned (21).

The advantage of using picosirius red stain and polarizing microscope is that, the property of enhancing the birefringence demonstrated by the fibers could be exploited, the equipments and materials used are less expensive; the technique is relatively easier to perform and is reproducible. Moreover the polarizing Colors itself helps in grading the severity of the disease (22).

As the aim of the present study was to correlate the polarization colors and thickness of collagen fibers with clinical and functional staging, according to literature, all cases of OSMF usually exhibited the presence of one or more of the clinical characteristics like blanching of the buccal mucosa/faucial/labial/perioral mucosa with or without palpable fibrous bands and restricted mouth opening (2). In this study, more than 50% of subjects had fibrous bands on the faucial pillars and buccal mucosa which is comparable to Pindborg (23) in which he stated that the buccal mucosa and faucial pillars are the most frequently affected sites. According to Haider et al. (8), the fibrous tissue in the faucial pillars varies from a slight submucosal accumulation in both pillars to a dense fibrosis extending and involving the tissue around the pterygomandibular raphae, which causes varying degrees of trismus. Therefore, when the comparison of clinical staging with functional staging was done, the location of fibrous bands and the restricted mouth opening did not reveal any significant correlation between them, which was in accordance with previous studies reported by Kiran Kumar et al. (17), Haider et al. (8), Saurab et al. (4).

Study group was also categorized under histological grading as a very early, early, moderately

advanced and advanced stage according to Pindborg et al. (6) criteria. The OSMF cases in present study showed no noteworthy differences to previous studies, when overall histopathological features were considered.

When the correlation of clinical staging with histopathological staging was done, the present study showed no correlation between them as the site of biopsy was from the buccal mucosa which is most accessible for the surgeon, even if thick fibrous bands were present in faucial pillar area. This may be the reason for the shift of some of the patients in clinical stage II to histopathological grade I and of some patients in clinical stage III to histopathological grades I and II and these findings are comparable with studies of Kiran Kumar et al. (17), Haider et al. (8), Saurab et al. (4).

When the correlation of functional staging with histopathological staging was done, a significant correlation was observed between them which could be a remarkable parameter to assess the severity of the diseases because according to literature, as there is always a juxta-epithelial inflammatory reaction followed by progressive hyalinization of the lamina propria in early stages. In advanced stages, subepithelial and submucosal myofibrosis leads to stiffness of the oral mucosa and deeper tissues with progressive limitation in the opening of the mouth. Similar histopathological findings were observed in the present study as the functional stages advanced. Similar findings have been observed in the study by Pindborg et al. (23), Khanna et al. (24).

The above-mentioned clinico-functional parameters were then correlated with polarization Colors and thickness of collagen fibers. The different polarization colors of collagen fibers were observed due to the varied density in the initial fibrosis in early stages and tightly packed collagen fibers in advanced stages. The present study which revealed the fact that the number of greenish yellow fibers decreased from very early stages

to advanced stages while number of orange red to red fibers increased in moderately advanced and advanced stages as compared with very early and early stages of OSMF. It is comparable with studies given by Johnson NW et al. (25), Junqueira et al. (26). Regarding the thickness of collagen fibers, the current data stated that morphologically there is a trend of increased collagen fiber thickness as the severity of the disease increases by Junqueira et al. (26).

When the clinical staging compared with polarization colors of collagen fibers, it was found that, the site of fibrous bands was not correlating with polarization Colors of fibrous bands. According to Haider et al. (8), mild grade of clinical staging with posterior bands shows thin fibers with greenish yellow color whereas advanced grade shows thick fibers with additional anterior involvement with reddish orange to red color under polarized microscopy. However, few cases in study group showed contradictory findings where mild grade of clinical staging with posterior bands showed orange red-to-red colored fibers and advanced grade of clinical staging with anterior involvement showed greenish yellow color fibers. Hence, there was no correlation between clinical stages and polarization colors of collagen fibers as the statistical analysis with paired 't' test was not significant.

The correlation of clinical staging and mean thickness of collagen fibers stated no significant change in the thickness of collagen fibers observed as similarly mentioned in studies given by Shivkumar et al. (27).

When the correlation of functional staging with polarization colors of collagen fibers was done, the mouth opening was strongly correlated with polarization colors of fibrous bands, as the functional stages advanced; it showed decrease in intensity of color of collagen fibers from greenish yellow to increase intensity of orange red-to-red color. The similar findings have been

reported by Haider et al. (8).

A correlation of functional stages with thickness of collagen fibers the statistical analysis with one way ANOVA test was highly significant as in present study, when functional stages were advanced, there was increase in diameter of thin and thick fibers in advancing stages of OSMF as mentioned in the previously stated studies given by Johnson et al. (25), Junqueira et al. (26).

Therefore, future research should focus not only on the collagen fibers but also on the alterations in ground substance if any, along with the role of collagenase enzymes which is responsible for collagen degradation. A more effective management strategy could be derived for this disease, through intense research on large number of cases, since OSMF remains elusive with respect to management protocols.

Conclusion

As there is a paucity of studies, hence a better understanding of the correlation between clinical staging and histopathological grading with polarized microscopy are needed which can provide a good marker for the diagnosis, prognosis and severity of this multifactorial disease of collagenous stroma. The study points towards the need for planning oral health education programme for youngsters and teenagers to refrain them from various betel nut chewing habits particularly gutkha chewing, which is the more prevalent habit in this age group.

Acknowledgement

Besides, we would like to thank the laboratory of D. Y. Patil Dental College and hospital for providing us with a good environment, materials and financial facilities to complete this project. The authors declare that there is no conflict of interests.

References

1. More CB, Gupta S, Joshi J, Varma SN. Classification System for Oral Submucous Fibrosis. *J Indian Aca Oral Med Radio* 2012;24(1):24-9.
2. Rajendran R, Sivapathasundharam B. Shafer's Textbook of Oral Pathology. 6th ed. Noida: Elsevier; 2009.
3. Khan S, Chatra L, Prashanth SK, Veena KM, Rao PK. Pathogenesis of oral submucous fibrosis. *J Can Res Ther* 2012;8(2):199-03.
4. Goel S, Ahmed J, Singh MP, Nahar P. Oral Submucous Fibrosis: A Clinico-Histopathological Comparative Study in Population of Southern Rajasthan. *J Carcinogene Mutagene* 2010;1(2):108-11.
5. Junqueira LCU, Bignolas G, Brentani RR. A simple and sensitive method for the quantitative estimation of collagen. *Anal Biochem* 1979;94(1):96-9.
6. Pindborg JJ, Sirsat SM. Oral submucous fibrosis. *Oral Surg Oral Med Oral Pathol* 1966;22(6):764-79.
7. Rooban T, Saraswathi TR, Al Zainab FH, Devi U, Elizabeth J, Ranganathan K. A light microscopic study of fibrosis involving muscle in oral submucous fibrosis. *Indian J Dent Res* 2005;16(4):131-4.
8. Haider SM, Merchant AT, Fikree FF, Rahbar MH. Clinical and functional staging of OSMF. *Br J Oral Maxillofac Surg* 2000;38(1):12-5.
9. Gupta SC, Yadav YC. MISI an etiologic factor in oral submucous fibrosis. *Ind J Otolaryngol* 1978;30(1):5-6.
10. Cox SC, Walker DM. Oral Submucous fibrosis: A review. *Aust Dent J* 1996;41(5):294-9.
11. Wahi PN, Luthra UK, Kapur VL. Submucous fibrosis of oral cavity- Histomorphological studies. *Br J Cancer* 1966;20(4):676- 87.
12. Pindborg JJ, Bhonsle RB, Murti PR, Gupta PC, Daftary DK, Mehta FS. Incidence and early forms of oral submucous fibrosis. *Oral Surg Oral Med Oral Pathol* 1980;50(1):40- 4.
13. Sinor PN, Gupta PC, Murti PR, Bhonsle RB, Daftary DK, Mehta FS, *et al.* A case-control study of oral submucous fibrosis with special reference to the etiologic role of areca nut. *J Oral Pathol Med* 1990;19(2):94-8.

14. Maher R, Lee AJ, Warnakulasuriya KAAS, Lewis JA, Johnson NW. Role of areca nut in the causation of oral submucous fibrosis: a case control study in Pakistan. *J Oral Pathol Med* 1994;23(2):65-9.
15. Seedat HA, Van Wyk CW. Betel-nut chewing and submucous fibrosis in Durban. *S Afr Med J* 1988;74(12):568-71.
16. Ranganathan K, Devi MU, Joshua E, KiranKumar K, Saraswathi TR. Oral submucous fibrosis: a case-control study in Chennai, South India. *J Oral Pathol Med* 2004;33(5):274-7.
17. KiranKumar K, Saraswathi TR, Ranganathan K, Devi UM, Elizabeth J. Oral submucous fibrosis: A clinico-histopathological study in Chennai. *Indian J Dent Res* 2007;18(3):106-11.
18. Pandya S, Chaudhary AK, Singh M, Singh MN, Mehotra R. Correlation of histopathological diagnosis with habits and clinical findings in oral submucous fibrosis *Head Neck Oncol* 2009;1(1):1-10.
19. Sharma R, Raj SS, Miahra G, Reddy YG, Shenava S, Narang P. Prevalence of Oral Submucous Fibrosis in Patients visiting Dental College in Rural Area of Jaipur, Rajasthan. *J Indian Aca Oral Med Radiol* 2012;24(1):1-4.
20. Shah N, Kumar R, Singh MK. Hematological and Histological studies in Oral Submucous Fibrosis. *JIDA* 1993;64(12):383-8.
21. Singh M, Chaudhary AK, Pandya S, Debnath S, Singh MN, Singh PA, *et al.* Morphometric Analysis in Potentially Malignant Head and Neck Lesion: Oral Submucous Fibrosis. *Asian Pac J Cancer Prev* 2010;11(1):257-60.
22. Junqueira LCU, Bignolas G, Brentani RR. Picrosirius staining plus polarization microscopy, a specific method for collagen detection in tissue section. *Histochem J* 1979;11(4):447-55.
23. Pindborg JJ, Mehta FS, Gupta PC, Daftary DK. Prevalence of oral submucous fibrosis among 59,915 Indian villagers. *Br J Cancer* 1968;22(4):646-54.
24. Khanna JN, Andrade NN. Oral submucous fibrosis: a new concept in surgical management– Report of 100 cases. *Int J Oral MaxillofacSurg* 1995;24(6):433-9.
25. Johnson NW, Maher R, Trivedy C, Warnekulasureiya S. The Clinical Condition and Pathology of Oral Submucous fibrosis. *Oral Dis* 1997;3(4):278-9.
26. Junqueira LCU, Montes GS, Sanchez EM. The influence of tissue section thickness on the study of collagen by the Picrosirius – polarization method. *Histochem* 1982; 74(1):153-6.
27. Shivakumar GC, Sahana S. Clinical Staging of Oral Submucous Fibrosis: A Review. *Int J Oral-Med Sci* 2011;10(3):216-9.