

Case Report

Chronic Granulomatous Disease, Case Report and Review of Literature

Khadije Mahlouji¹, Mitra Mehrazma², Reza Taghipour¹

1. Dept. of Pediatrics, Iran University of Medical Sciences, Tehran, Iran.

2. Dept. of Pathology, Iran University of Medical Sciences, Tehran, Iran.

ABSTRACT

Chronic granulomatous disease (CGD) is a rare inherited disorder characterized by inability of phagocytes to generate oxygen radicals needed for intracellular killing of phagocytic microorganisms. We report a 2.5-year-old Iranian female with multiple liver abscesses. She was admitted in surgical ward because of abdominal pain and fever for one month duration that had no response to conventional antibiotic treatment. The results of laboratory tests were: WBC=17000, Neutrophils=82%, lymph=17%, ESR=100. Other tests except nitroblue tetrazolium (NBT) and dihydrorhodamine (DHR) tests were negative and according to these two tests the final diagnosis was CGD. Supportive care along with recombinant interferon γ and oral trimethoprim-sulfamethoxazole for prophylaxis of infections started. Now after 18 months she is alive and healthy. Any patient with recurrent or unusual lymphadenitis, hepatic abscesses, osteomyelitis at multiple sites, a family history of recurrent infections, or unusual infections with catalase positive organisms, like *S. aureus*, requires evaluation for CGD.

Keywords: Chronic Granulomatous Disease, Hepatic Abscess, Nitrotetrazolium Blue, Iran

Introduction

Chronic Granulomatous Disease (CGD) is a rare inherited disorder with an incidence of four to five per million individuals, characterized by defects in superoxide-generating nicotinamide adenine dinucleotide phosphate (NADPH) oxidase of phagocytes, leading to an impaired ability to kill intracellular microorganisms(1). This disease is due to a mutation in one of the four genes encoding the four subunits of the oxidase enzyme of phagocytes that

may lead to total absence, a decreased amount, or a defective functional protein product. The inheritance is X-linked (most commonly) and autosomal recessive due to mutations involving chromosome locations 16p24, 7q11.23, or 1q25.

In CGD catalase-producing organisms, which destroy cytoplasmic hydrogen peroxide, survive intracellular ingestion, multiply, and cause a granulomatous tissue response. *Staphylococcus aureus* is the most common organism involved. Chronic infections with *Serratia*, *Klebsiella* species, *Burkholderia cepacia*, and *Aspe-*

Received: 27 August 2008

Accepted: 20 January 2008

Address communications to: Dr Mitra Mehrazma, Ali-Asghar children hospital, Tehran, Iran.

Email: mitmehr@yahoo.com

rgillus species are particularly troublesome (1).

Once the significance of superoxide deficiency was defined in this condition, a diagnostic test based on the reduction of nitroblue tetrazolium(NBT) by neutrophils followed. Currently, tests that measure superoxide production are performed with dihydrorhodamine (DHR) flow cytometry which makes possible identification of carriers and AR forms of the disease (2).

Children with immunosuppressive states such as CGD, leukemia and immunosuppression associated with liver transplantation and those who have procedures such as hepaticojejunostomy or choledochojejunostomy for correction of biliary atresia or choledochal cysts are at higher risk for hepatic infection(3).

Case report

We report a 2.5 years old girl from MeshkinShahr, Northwest Iran, 839 Km far from Tehran.

The chief complain of patient was abdominal pain since 1 month before referring to the surgery clinic of Ali-Asghar Hospital in Tehran Iran. In abdominal sonography, liver span was 75 mm and there were two hypoechogenic masses, 30 x 23mm in the left lobe and 29x22 mm without calcification in the right lobe of the liver .Abdominal CT scan with injection of contrast material, demonstrated heterogenic cystic masses with lobulation with marginal enhancement, measuring 20x20mm in the posterior segment of right and left lobes of the liver. In the past history of patient, she was admitted to the hospital because of febrile convulsion at 2 months of age and because of pneumonia at 4 months of age. Now she was admitted in surgical ward because of abdominal pain and fever for 1 month that had no response to conventional antibiotics treatment. The results of primary laboratory tests are demonstrated in Table 1.

Table 1: Results of primary laboratory test

Lab test	Result	Comment
WBC	17000/mm ³	—
WBC differential count	Neut=82%, Lymph=17%	—
Hemoglobin	8gr/dl	—
platelets	82000//mm ³	—
ESR	100-140	—
Blood smear	Target cell and burr cell	—
Blood culture	Negative after 7 days	—
Anti-Echinococcus antibody	Negative	—
Anti-amebic antibody	1/80	Negative
Alfa fetoprotein	1/96	Normal

The patient underwent laparotomy. There were two masses within liver. Two specimens were taken and sent to the pathology department as fresh state for frozen examination, which was reported as inflammatory reaction (negative for malignancy). Another sample was sent to microbiology ward. Microscopic examination of Hematoxylin and eosin stained slides

shows multiple satellite abscesses. The abscesses had a central area of suppuration, with a surrounding palisade of macrophages. Foci of granulomatous inflammation with multinucleated giant cells were also seen (Fig. 1). The diagnosis was multiple liver abscesses, and further studies for determining an underlying disease was recommended.

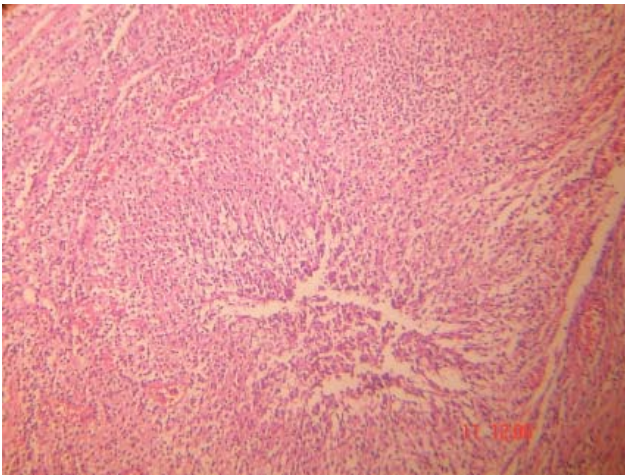


Fig. 1: Hepatic abscess in chronic granulomatous disease, a large granuloma with central necrosis and suppuration

Culture results of the second specimen for aerobic microorganisms were negative.

Treatment with amikacin+ meropenem +metronidazole was started and the results of confirmatory laboratory tests are shown in Table 2.

Table 2: The final laboratory tests for finding the etiology of liver abscesses

Lab test	Result	Comment
Bone Marrow Study For Leishmania	Negative	–
Abscess Culture	Negative	–
Anti Leishmania Antibody	Negative	–
Nitroblue Tetrazolium Test(Nbt)	0% Activity	Abnormal
Dihydrorhodamine (Dhr) Test	Positive	Abnormal

All the tests except NBT and DHR test were negative and the result of NBT activity was 0% . DHR test was positive and the final diagnosis was CGD.

Anemia was a normochromic and normocytic one and confirmatory tests show that it is an anemia of chronic disease.

Supportive care along with recombinant Interferon γ (IFN)- γ and oral trimethoprim-sulfamethoxazole for prophylaxis of infections started. The patient is alive and healthy.

Discussion

Our patient had multiple liver abscesses and the final diagnosis was CGD. The initial presentation of CGD may be that of hepatic abscess. As many as one third of hepatic abscesses in children are complication of CGD. Shahnava *et al.* in a retrospective study in Iranian patients with CGD showed that 42.1% of the patients had been complicated by gastrointestinal manifestations during their course of the disease (3). A variety of types of granulomas and microabscesses are found in the liver parenchyma. Portal tracts are inflamed and there may be fibrosis. A known pigment of ceroid type accumulates in portal macrophages and to a lesser extent in Kupffer cells. The morphology of granulomas may provide a clue to diagnosis. Classification of granulomatous lesions in the liver by histologic pattern is as the following: fibrin ring granuloma, microgranuloma, stellate microabscess with granulomatous inflammation, foamy macrophage aggregates, predominantly suppurative without or with granulomatous inflammation (4). In most hepatic abscesses, polymicrobial infection is present and anaerobes microaerophilic streptococci are more common (5). Because of absence of anaerobic culture facilities in our laboratory, culture result of our patients was negative. Any patient with recurrent or unusual pneumonia, lymphadenitis, hepatic or other abscesses, osteomyelitis at multiple sites, a family history of recurrent infections, or unusual infections with catalase- positive organisms (e.g. *s. aureus*) requires evaluation(6-8). NBT is the classic laboratory method to screen for CGD, but has been replaced in many laboratories by a flow cytometer equivalent; that is better suited to the study of clinical samples. Another screening test for CGD is the measurement of chemiluminescence and superoxide production but these tests are not performed in most laboratories (2). Antibiotic prophylaxis with cotrimoxazole reduces the frequency of bacterial infections with CGD for prophylaxis of infections (9). Cultures must be obtained as soon as infection is suspected. Most abscesses require surgical drainage for therapeutic and diagnostic purposes. Prolonged use of antibiotics is often required. Granulocyte transfusions may be

necessary if antibiotics are ineffective. If fever occurs without an obvious focus, it is advisable to consider the use of radiographs of the chest and skeleton as well as CT scans of liver to determine if pneumonia, osteomyelitis, or liver abscesses are present (10). The ESR may be used to help determine the duration of antibiotic treatment. The overall mortality rate for CGD is about two patient deaths/year/100 cases, with the highest mortality among young children. The development of effective infection prophylactic regimens, close surveillance for signs of infections, and aggressive surgical and medical interventions has improved prognosis (11).

An interesting point in this disease is that although X-linked recessive (XLR) –CGD is worldwide the most common genotype of the disease (about 70%), in one study from Israel, the incidence of autosomal recessive (AR) form of the CGD was higher and about 63% of patients. In our country we have no documented data from inheritance type, but like Israel because of consanguineous marriage, the AR form of the disease may be more common. Severe clinical expression is found in the X LR and AR forms, but in general a milder disease is evident in AR-CGD (12).

An important study showed that CGD was a risk factor for autoimmune disorders, such as antiphospholipid syndrome, recurrent pericardial effusion, juvenile idiopathic arthritis, IgA nephropathy, cutaneous LE and autoimmune pulmonary disease (13) that may be because of presence of reactive oxygen species-deficient monocytes in this disease (14).

Hematopoietic stem cell transplantation is the only known cure for CGD (15). Vigorous supportive care with recombinant interferon γ is used before transplantation, as part supportive care (16), but one large study in Italy showed that long term prophylaxis with IFN γ did not significantly change the rate of total infection per patient-year compared to controls (17).

Allogenic bone marrow transplant can cure CGD, but most patients lack a HLA-matched sibling, and variability in morbidity complicates the choice of which patients should be transplant. Gene therapy is potentially an option (18).

Genetically modified cells have been used successfully in mouse models of CGD and further allogenic stem cell transplantation has been shown to be curative in humans (19).

Conclusion

Any patient with recurrent or unusual lymphadenitis, hepatic abscesses, osteomyelitis at multiple sites, a family history of recurrent infections, or unusual infections with catalase- positive organisms (e.g., *S aureus*) requires evaluation for this disorder (CGD).

References

1. Henry JB. Clinical Diagnosis and Management by Laboratory Methods. 12th ed. Philadelphia: Saunders; 2001.
2. Barness EG .Potter's Pathology of the Fetus, Infant and Child. 2nd ed. Philadelphia: Mosby; 2007.
3. Shahnava N, Aghamohammadi A, Babaei Jandaghi A, Abolmaali K, Rezaei N, Ezzati M, *et al.* Gastrointestinal involvement in Iranian patients with chronic granulomatous disease. *J Allergy Clin Immunol* 2007;119(1):5287.
4. Gershon AA, Hotez PJ, Katz SL. Krugman's Infectious Disease of Children. 11th ed. Philadelphia: Mosby; 2004.
5. Scheuer PJ, Lefkowitz JH. Liver Biopsy Interpretation. 6th ed. Philadelphia: W B Saunders; 2000.
6. Stocker JT, Dehner LP. Pediatric Pathology. 2nded. Philadelphia: Lippincott Williams & Wilkins; 2001.
7. Kliegman RM, Behrman RE, Jenson HB, Stnton BF. Nelson's Textbook of Pediatrics. 17th ed. Philadelphia: W B Saunders; 2003.
8. Tauber AI, Borregaard N, Simons E, Wright J. Chronic granulomatous disease: a syndrome of phagocyte oxidase deficiencies. *Medicine (Baltimore)* 1983;62(5):286-309.
9. Ayatollahi M, Geramizadeh B. Carrier screening and prenatal detection of chronic granulomatous disease in Iran. *Saudi Med J* 2006;27(9):1334-7.
10. Garcia-Eulate R, Hussain N, Heller T, Kleiner D, Malech H, Holland S, *et al.* CT and MRI of hepatic abscess in patients with chronic granulomatous disease. *AJR Am J Roentgenol* 2006;187(2):482-90.
11. Feigin RD, Cherry JD, Demmer GJ, Kaplan SL. Textbook of Pediatric Infectious Disease. 5th ed. Philadelphia: Saunders; 2004.
12. Wolach B, Gavrieli R, de BM, Gottesman G, Ben-

Ari J, Rottem M, *et al.* Chronic granulomatous disease in Israel: clinical, functional and molecular studies of 38 patients. *Clin Immunol* 2008;129(1):103-14.

13. De Ravin SS, Naumann N, Cowen EW, Friend J, Hilligoss D, Marquesen M, *et al.* Chronic granulomatous disease as a risk factor for autoimmune disease. *J Allergy Clin Immunol* 2008;122(6):1097-103.

14. Brown KL, Bylund J, MacDonald KL, Song-Zhao GX, Elliott MR, Falsafi R, *et al.* ROS-deficient monocytes have aberrant gene expression that correlates with inflammatory disorders of chronic granulomatous disease. *Clin Immunol* 2008;129(1):90-102.

15. Kansoy S, Kutukculer N, Aksoylar S, Aksu G, Kantar M, Cetingul N. Successful bone marrow transplantation in an 8-month-old patient with chronic granulomatous disease. *Turk J Pediatr* 2006;48(3):253-5.

16. Stein S, Siler U, Ott MG, Seger R, Grez M. Gene therapy for chronic granulomatous disease. *Curr Opin Mol Ther* 2006;8(5):415-22.

17. Martire B, Rondelli R, Soresina A, Pignata C, Broccoletti T, Finocchi A, *et al.* Clinical features, long-term follow-up and outcome of a large cohort of patients with Chronic Granulomatous Disease: an Italian multicenter study. *Clin Immunol* 2008;126(2):155-64.

18. Malech HL, Linton GF, Theobald W N, Naumann N, DeRavin SS, Choi U, *et al.* Update on gene therapy for chronic granulomatous disease, current studies and future approaches. *Blood Cells Mol Dis* 2008;40(2):274-5.

19. Kang EM, Linton G, Theobald N, O'Brein SA, Hilligoss D, Malech H. Treatment of infections with X-linked chronic granulomatous disease with gene therapy. *Blood Cells Mol Dis* 2008;40(2):270-1.