

Case Report

Lung Carcinoma Metastasis to the Distal Part of Index Finger: A Case Report

Mitra Heidarpour¹, Parvin Rajabi¹, Amin Eftekhari¹, Hamid Reza Ghasemibasir¹

1. Department of Pathology, Isfahan University of Medical Sciences, Isfahan.

ABSTRACT

Although acrometastases are rare but clinically they are considered important. Their etiology is quite different from the metastases to other sites; bronchogenic carcinoma is by far the most frequent case. The prognosis is always similar to metastatic bronchial cancer with an average survival of three months. Treatment may involve distal digital amputation or antalgic radiotherapy. The main differential diagnosis is aggressive digital papillary adenocarcinomas (ADPA) that is a rare sweat gland neoplasm.

A case of bronchogenic carcinoma with metastasis to the index finger is presented. The metastasis was located in the distal phalanx of the left index finger. Although acrometastasis is rare, it should be considered in the differential diagnosis of distal lesions, especially in elderly patients.

Key words: Lung cancer, Finger metastasis

Introduction

One metastases from malignant neoplasms are frequent. However, metastases to extremities are rare, and the hands contribute to about 0.2% of this incidence (1). The etiology is quite different from that of metastasis to other bones; bronchogenic carcinoma is by far the most frequent case (2). Kerin (1987) published the most recent review of hand metastasis in the world literature (3). Out of 163 cases studied, the terminal phalanges were the most frequent site of involvement, followed by the metacarpals and proximal phalanges. Primary lesions were, in order of frequency, lung, kidney, breast, and gastrointestinal cancers. Since then, isolated cases of thumb metastasis from several origins have been described (3-4).

Case Report

A 78-year-old man complained of a 1-month history of an ulcerative nodule on the left index finger. The nodule had enlarged gradually and was accompanied by spontaneous bleeding. The nodule on the tip of the left index finger was about 1 cm in diameter, well demarcated, fleshy, and reddish, with raised ulcerative surface appearance. Radiologic findings show diffused osteoporosis in distal phalanx of 2nd finger of the left hand (Figure 1). Histopathologic findings of the digital nodule revealed neoplastic proliferation of the epithelial cells with tubular feature (Figure 2). These cells had a marked nuclear atypia and pleomorphism with a high nuclei/cytoplasmic ratio, vesicular nuclei, and prominent nucleoli. Immunohistochemical analysis

Received: 15 August 2006

Accepted: 21 October 2006

Address communications to: Dr. Parvin Rajabi, Dept. Pathology, School of medicine, Isfahan university of medical sciences, Isfahan-IRAN

E-mail: p_rajabi@med.muc.ac.ir

showed the following results: TTF1 as positive, CEA as positive in tubular structures, thyroglobulin (TG) as negative, CK7 as positive, CK20 as negative, and S100 as negative (Figure 3).

Because the diagnosis of a metastatic carcinoma and skin appendage tumor was suspected, subsequent systemic examination was considered. Computed tomography revealed segmental alveolar consolidation in postero-basal segment of the left lower lobe (Figure 4). The patient refused lung biopsy; so we did not have any pathologic diagnosis of the lung mass.

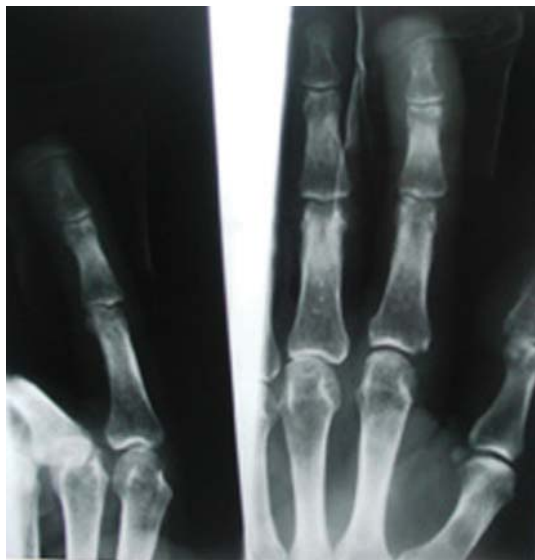

Figure 1: Diffuse osteoporosis in radiographic examination .

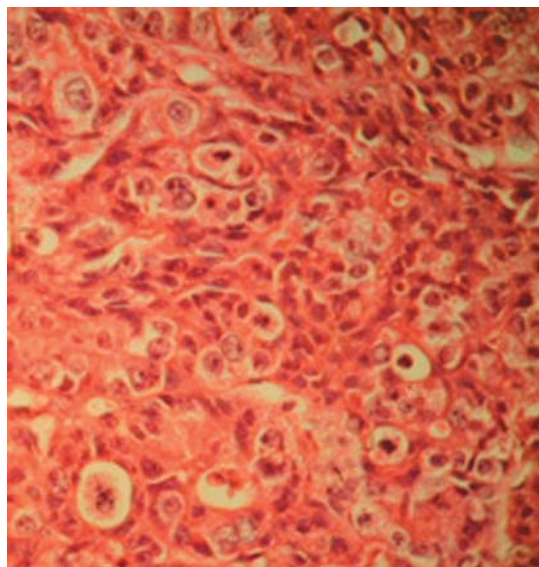


Figure 2: Neoplastic proliferation of the epithelial cells with tubular feature.

One month later, he admitted with confusion and decreased consciousness. The brain CT showed a hypodense lesion in right parietal lobe (Figure 5). The patient refused for any therapy and died some weeks later.

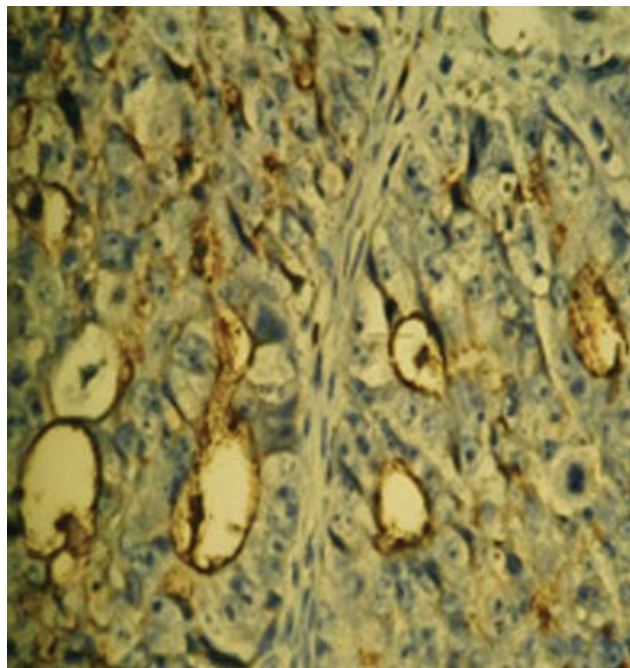


Figure 3: CEA staining show reactivity in tubular structures.

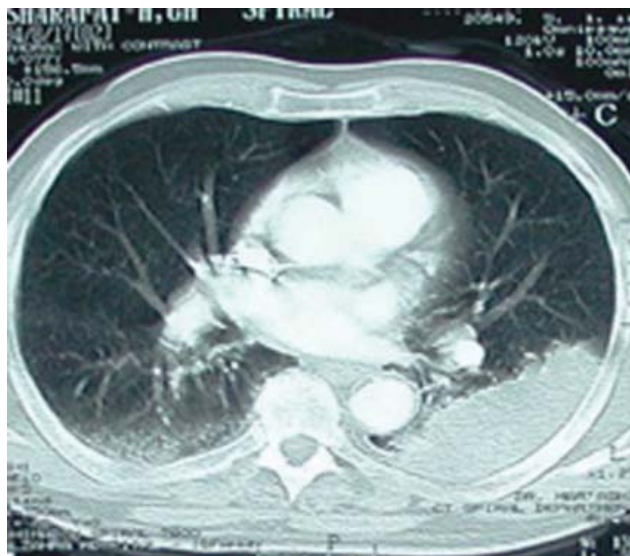


Figure 4: Segmental alveolar consolidation in postero-basal segment.

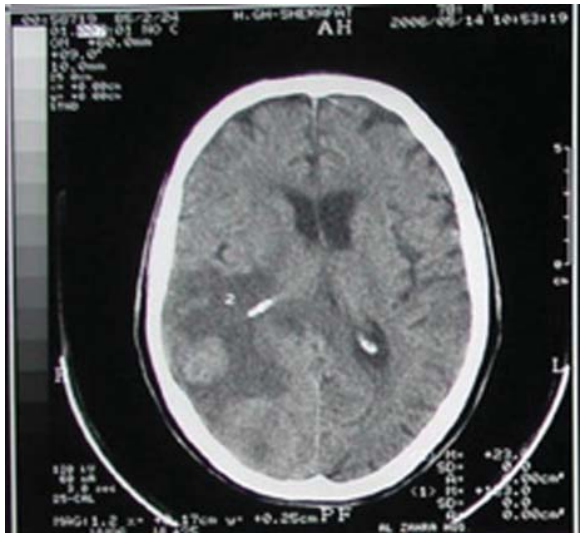


Figure 5: Hypodense lesion in right parietal lobe.

Discussion

In one series of studies, 138 cases of metastasis to digital skin have been reported, however, in only 17 cases have the digital metastases been recognized before the diagnosis of primary cancer (5-6). In this respect, fifty-six out of the 138 cases (39.9%) showed lung cancer as the primary tumor. The age range at presentation was between 33 and 80 years (5-6). In our case, no biopsy was indicated to confirm the exact nature of the lung consolidation. Diagnosis was made based on clinical presentation and radiological findings and the results of immunohistochemical study. One of the most important positive markers in IHC study is thyroid transcription factor-I (TTF-I). TTF-1 which is consistently expressed in the normal pulmonary airways has emerged as one of the most useful markers of epithelial lung tumors (7). It is expressed in about three quarter of the adenocarcinomas and in a smaller percentage of the other lung carcinoma types (8). Therefore, its detection in metastases in brain or other sites is an almost certain indicator that the primary tumor is of lung origin (a positive result in this case) (8). There is only one major proviso: as its name indicates the other tissue in which TTF-I is consistently expressed is the thyroid epithelium (8-9).

For ruling out the metastatic thyroid carcinoma

we performed thyroglobulin (TG) staining and the result was negative. TG is produced by the thyroid follicular cells and serves as the substratum for iodination and hormonogenesis. It is a specific marker of thyroid differentiation and is widely used in the evaluation of thyroid neoplasms. In this regard, it has been found preferable to the search for the thyroid hormones T3 and T4 (9).

Another important tumor in this region is aggressive digital papillary adenocarcinoma (ADPA). ADPA are rare sweat gland neoplasms that were first described by Helwig and later by Kao et al in 1984 (10). Characteristic histologic findings include tubuloalveolar and ductal structures with areas of papillary projections protruding into sometimes cystically dilated lumina. Macropapillae lined by atypical epithelial cells project into microcysts. Because of high specificity of TTF-I in lung and thyroid tissue we ruled out this type of tumor (8).

Carcinoembryonic antigen (CEA) is detectable only in small amounts in normal adult cells and benign tumors but is present in large quantities in carcinomas, particularly in adenocarcinomas of the gastrointestinal tract (including pancreas) and lung and in thyroid medullary carcinoma (11).

The therapy for cutaneous lesions is not well defined. Most patients with metastatic carcinoma to the finger are followed up without special treatment for the lesions but some have undergone radiation or even amputation of the digit with the metastatic tumor (12-13). In our case, amputation of the distal phalanx was performed.

To conclude, it may be possible to increase the survival rate of patients with digital metastases with the use of appropriate treatment.

Conclusion

Therefore, when a digital nodule is encountered, metastatic carcinoma to the skin should always be included in the differential diagnosis, even if the individual has never been diagnosed as having cancer.

Acknowledgment

The authors would like to thank Negin Eeftekhari for her help.

References

1. KUMAR PP. Metastases to the bones of the hand. *J Natl Med Assoc* 1975 67:275-6
2. Galmarini CM. Metastasis of bronchogenic carcinoma to the thumb. *Med Oncol* 1998 15(4):282-5
3. KERIN R . The hand in metastatic disease. *J Hand Surg [Am]* 1987 12A:77-83
4. LEWIN JS, CLEARY KR, EICHER SA . An unusual metastasis to the thumb in a laryngectomized tracheoesophageal speaker. *Arch Otolaryngol Head Neck Surg* 1997 123:1007-9
5. Baran R, Guillot P, Tosti A. Metastasis from carcinoma of the bronchus to the distal aspect of two digits. *Br J Dermatol* 1998 138:708
- 6 Cohen PR. Metastatic tumors to the nail unit; subungual metastases. *Dermatol Surg* 2001 27:280–293
- 7 Suster S, Moran CA, Koss MN. Rhabdomyosarcomas of the anterior mediastinum. Report of four cases unassociated with germ cell, teratomatous, or thymic carcinomatous components. *Hum Pathol* 1994 25: 349-356
8. McLoud TC, Kalisher L, Stark P, Green R. Intrathoracic lymph node metastases from extrathoracic neoplasms. *AJR Am J Roentgenol* 1978 131: 403-407
9. Albores-Saavedra J, Nadji M, Civantos P, Morales AR. Thyroglobulin in carcinoma of the thyroid. *Hum Pathol* 1983 14: 62-66
10. Kao GF, Graham JH, Helwig EB. Aggressive digital papillary and adenocarcinoma [Abstract]. *Arch Dermatol* 1984 120:1612
- 11 Jothy S, Brazinsky SA, Chin-A-Loy M, Haggarty A, Krantz MJ, Cheung M, Fuks A. Characterization of monoclonal antibodies to carcinoembryonic antigen with increased tumor specificity. *Lab Invest* 1986 54:108-117
12. Umebayashi Y. Metastasis of esophageal carcinoma manifesting as whitlow-like lesions. *J Dermatol* 1998 25: 256–259
13. Okada H, Qing J, Ohnishi T, et al. Metastasis of gastric carcinoma to a finger. *Br J Dermatol* 1999 140:776–777