

Original Article

Androgen Receptor Analysis in Relation to Estrogen and Progesterone Receptors as well as Histological Grade for Ductal Carcinoma In Situ of the Breast

Peyman Mohammadi Torbati ¹, Pejman Fard Esfehni ²

1. Department of pathology, Shahid Beheshti University of Medical Sciences.

2. Department of biochemistry, Institute Pasteur, Tehran.

ABSTRACT

Background and Objective: Since the advent of mammography screening, ductal carcinoma in situ (DCIS) of the breast has been diagnosed increasingly. In contrast to the situation in invasive breast carcinoma, there are only a few reports on androgen receptor (AR) status in DCIS and few reports on estrogen (ER) and progesterone (PR) receptors.

Materials and Methods: AR expression was examined in 51 cases of DCIS of the breast and correlated to the degree of differentiation and ER/PR expression status in accordance to immunohistochemical results.

Results: AR immunoreactivity was noted in 17 of the cases, whereas the other 34 cases were negative. There was also no significant association between AR expression and the degree of differentiation of DCIS; two of the 11 well-differentiated DCIS cases, nine of the 17 intermediately differentiated cases, and six of the 23 poorly differentiated cases were AR positive ($p = 0.091$). However, a strong association was shown between the expression of ER ($p < 0.001$) and PR ($p = 0.002$) and the degree of differentiation of DCIS. In addition, no significant association was found between the expression of AR and the expression of ER ($p = 0.37$) or PR ($p = 0.63$) in DCIS of the breast.

Conclusion: Clinically significant number of cases of DCIS of the breast expresses AR, which may affect accurate typing of DCIS. Moreover, the expression of AR (but not ER or PR) in DCIS does not appear to be associated with the degree of differentiation.

Key words: Breast, Ductal carcinoma in situ, Androgen receptor

Introduction

Ductal carcinoma in situ (DCIS) of the breast without invasion has been reported increasingly since the advent of mammography screening, but the natural history of

this lesion remains unclear. DCIS of the breast does not represent a single entity but is a heterogeneous group of lesions with histological and clinical differences (1,2). The histological subtype of DCIS influences its biological behavior, but there are only a few studies correlating the classification with biological markers (3-5).

Received: 20 August 2006

Accepted: 25 September 2006

Address communications to: Dr. Peyman Mohammadi torbati, Department of pathology, Labafinejad Hospital, Boostan 9th, Pasdaran Ave., Tehran-IRAN
E-mail: p2000torbati@yahoo.com

The fact that sex steroid hormones and their receptors act in concert has led some investigators to study the role of the androgen receptor (AR) in patients with breast cancer. AR is expressed in approximately 35–75% of breast cancers (6-8). Variations may be attributable to different methodologies and different fixatives, but a different case mix may also affect these studies. It has been shown that AR values correlate reasonably well with estrogen receptor (ER) values, but more so with those for the progesterone receptor (PR) (6-9). AR positive breast cancer patients have prolonged survival and a better response to hormonal treatment than AR negative patients. Thus, some researchers believe that knowledge of the receptor status of all three receptors may identify more accurately those patients with breast cancer who are most likely to respond to endocrine treatment (7-11). In addition, androgen stimulation has both stimulatory and inhibitory growth effects on some breast cancer cell lines, depending on the status of receptors and other growth factor effects (12,13).

In contrast to the situation in invasive breast carcinoma, there are only few reports on AR status in DCIS and only occasional reports on ER and PR expression in DCIS (4,5, 14-16). Hence, this study was undertaken to investigate AR expression in DCIS and to correlate it with the expression of ER and PR, in addition to the degree of differentiation of cases of DCIS of the breast.

Materials & Methods

Fifty one cases of DCIS were collected from the files of two different pathology laboratories of Golestan and Hedayat hospitals (Tehran, 2004-2006) who underwent an evidence-based study. The age of the patients ranged from 33 to 79 years (mean = 55.0). The cases were classified according to European classification of Holland based mainly on cytonuclear and architectural differentiation into three categories, namely: well differentiated (11 cases), intermediately differentiated (17 cases), and poorly differentiated (23 cases) DCIS.

Formalin fixed, paraffin embedded blocks of DCIS tissue were selected from the files and sectioned at a nominal 3-4 μm at Labafinejad medical center. The standard avidin biotin peroxidase complex method

was used. Heat-induced antigen retrieval using microwave method was applied for all staining. In details, the blocks were deparaffinized and processed as follows: 1) the samples were placed in oven at 37 °C for 48 hr, 2) the samples were rinsed in 100% xylol, ethanol 100%, 85%, 75% , and distilled water, 3) rinsed in PBS (10%) solution, 4) exposure to H₂O₂ 10% and methanol at a ratio of 1:9 for 30 min ,5) rinsed in PBS, 6) placed in citrate buffered solution (pH=6.1) for 14 min at a microwave with power 800, 7) rinsed in PBS (10%), 8) blocking serum was added to slides for 30 min and then dried, 9) addition of androgen receptor antibody (Dako, clone AR441,1/100 dilution), estrogen receptor antibody (Dako, clone ID-5 ,1/50 dilution) and progesterone receptor antibody (Dako, clone PgR; 1/300 dilution) for 30 min at room temperature, 10) rinse in PBS, 11) addition of broad spectrum antibody for 30 min , 12) addition of HRP-streptavidin for 30 min, 13) addition of DAB for 10 min,14) rinsed in PBS (10%) 15) dehydrated in distilled water, alcohols 75%, 85%, 100%, xylol, 16) counterstain with hematoxylin, five dips, 17) cover-slipped and coated. The slides were evaluated under light microscopy. Appropriate positive and negative controls omitting the primary antibodies were included with each slide run. In addition, the normal breast tissue in the samples served as an internal control. Nuclear staining was taken as positive, with cytoplasmic staining being ignored. The Quick Score method (19) was used for semiquantitation of AR, ER, and PR status as follows: 1) intensity of staining. Slides were assessed for the average degree of staining at low power (x10) and the following scores allocated: negative (0), weak (1), moderate (2), or strong (3), 2) the percentage of cells with positive nuclei was counted at high power (x40) and the following scores were allocated: < 25% (1), 25–< 50% (2), 50–< 75% (3), > 75% (4). The scores from (1) and (2) were added together to give a final score ranging from 0 to 7, designated as negative or positive as follows: score of 0–3 as negative and score of 4–7 as positive. All non-specific cytoplasmic staining was ignored. In cases with normal tissue presence, staining of nuclei in normal ducts or lobules was taken as a positive internal control. For statistical

analysis, 2 and Fisher exact tests were applied as appropriate. A p value of < 0.05 was considered to be significant.

Results

This study comprised 51 cases of DCIS, which were classified according to European classification of Holland and colleagues into three categories, namely: well differentiated (11 cases), intermediately differentiated (17 cases), and poorly differentiated (23 cases) DCIS. Table 1 summarizes the results of the three markers tested in the three categories of DCIS studied. Nuclear staining of the tumor cells was counted as positive. Of the 51 DCIS cases studied; 17, 28, and 25 cases were positive for AR (Figure 1), ER (Figure 2), and PR respectively. No association between AR expression and the degree of differentiation of DCIS was identified; two of 11 cases of well differentiated DCIS, 9 of 17 cases of intermediately differentiated DCIS, and six of 23 cases of poorly differentiated DCIS were AR positive (p = 0.091). A strong positive

association between ER and PR expression and the degree of differentiation of DCIS was found. All the 11 cases of well differentiated DCIS, 9 of 17 intermediately differentiated DCIS, and eight of 23 poorly differentiated DCIS cases were positive for ER (p<0.001). Four of the morphologically apocrine cases showed immunopositivity for ER. Ten of the 11 cases of well differentiated DCIS, eight of the 17 intermediately differentiated DCIS,

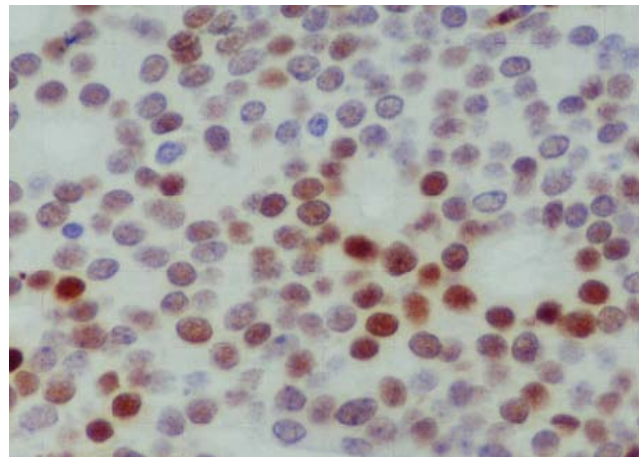


Figure 1: Androgen receptor nuclear staining of well differentiated ductal carcinoma in situ of the breast (Immunoperoxidase staining)

Table 1. Expression of AR, ER, and PR in the three categories of DCIS

Differentiation	AR		ER		PR	
	+	-	+	-	+	-
well differentiated (n=11)	2	9	11	0	10	1
intermediately differentiated (n=17)	9	8	9	8	8	9
poorly differentiated (n=23)	6	17	8	15	7	16
Total (n=51)	17	34	28	23	25	26
p value	0.091		<0.001		<0.002	

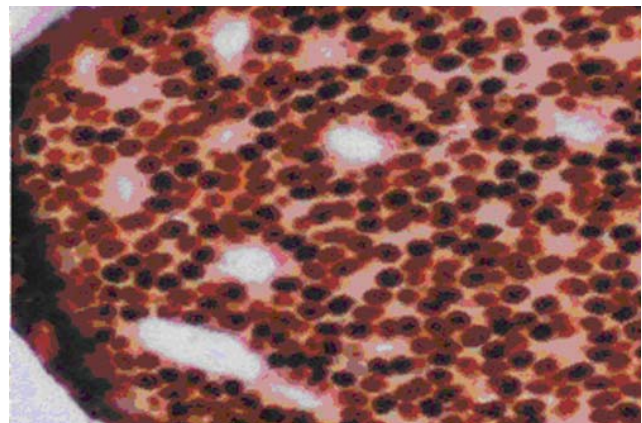


Figure 2: Strong nuclear staining for the estrogen receptor in well differentiated ductal carcinoma in situ of the breast (Immunoperoxidase staining)

Table 2. Association between AR expression and ER and PR expression in DCIS

		AR (+)n=17	AR (-)n=34	p value
ER	+	6	21	0.37
	-	9	13	
PR	+	7	19	0.63
	-	10	15	

and seven of the 23 poorly differentiated DCIS cases were positive for PR (p = 0.002). Table 2 shows no significant association between AR expression and the expression of ER (p = 0.37) or PR (p = 0.63) in cases of DCIS studied.

Discussion

In this study, using the Nottingham modification of European classification of Holland and colleagues to categorize cases into well (grade I), intermediately (grade II), or poorly differentiated (grade III) DCIS, no association was found between immunoreactivity for AR and the degree of differentiation of DCIS. In addition, no association was found between AR expression and the expression of ER or PR. However, Isola (11) found a strong association between AR detected immunohistochemically and histological grade in 76 cases of invasive breast carcinoma using frozen sections. A strong positive association between AR and ER was also found in his study. Ellis et al found no significant association between AR and ER expression in invasive breast carcinoma; however, a strong positive association was found in their study between AR and PR expression (6). The difference in the number and nature of cases studied, in addition to technical differences may explain the disagreement between our study and those of others. A larger series of cases of DCIS would be needed to exclude a weak association of AR with the degree of differentiation.

Our findings indicate that about one third of ductal carcinoma in situ (DCIS) cases are positive for the androgen receptor (AR) but negative for estrogen and progesterone receptors and there was no association between AR expression and the degree of differentiation in DCIS of the breast as well as there was no association between AR expression and the expression of ER and PR in DCIS of the breast. Our findings also agree with those of Bobrow et al (3), Millis et al (5) in that most poorly differentiated DCIS cases were lacking immunoreactivity for ER and PR, and most well differentiated DCIS cases were immunoreactive with ER and PR.

Conclusion

It seems that a clinically significant number of DCIS cases are positive for AR but negative for ER and PR, and this indicates the need for further investigation of AR status, in addition to conventional ER and PR. This could yield

potentially useful information for establishing new therapeutic strategies and evaluating the prognostic outcome in patients with DCIS, and may relate partially to apocrine differentiation of these tumors.

Acknowledgements

The authors wish to thank Mr. Golmohamadzade for technical assistance.

References

1. Lagios MD, Margolin FR, Westdahl PR, et al. Mammographically detected duct carcinoma in situ: frequency of local recurrence following lumpectomy and prognostic effect of nuclear grade on local recurrence. *Cancer* 1989 63:618–24
2. Lenington WJ, Jensen RA, Dalton LW, et al. Ductal carcinoma in situ of the breast: heterogeneity of individual lesions. *Cancer* 1994 73:118–24
3. Bobrow LG, Happerfield LC, Gregory WM, et al. Ductal carcinoma in situ: assessment of necrosis and nuclear morphology and their association with biological markers. *J Pathol* 1995 176:333–41
4. Zafrani B, Leroyer A, Fourquet A, et al. Mammographically detected ductal in situ carcinoma of the breast analysed with a new classification. A study of 127 cases: correlation with estrogen and progesterone receptors, p53 and c-erbB2 proteins and proliferative activity. *Semin Diagn Pathol* 1994 11:208–14
5. Millis RR, Bobrow LG, Barnes DM. Immunohistochemical evaluation of biological markers in mammary carcinoma in situ: correlation with morphological features and recently proposed schemes for histological classification. *Breast* 1996 5:113–22
6. Ellis LM, Wittliff L, Bryant MS, et al. Correlation of estrogen, progesterone and androgen receptors in breast cancer. *Am J Surg* 1989 157:577–81
7. Kuenen-Boumeester V, Van der Kwast TH, van Putten WL, et al. Immunohistochemical determination of androgen receptors in relation to estrogen and progesterone receptors in female breast cancer. *Int J Cancer* 1992 52:581–4
8. Collett K, Maehle BO, Skjarven R, et al. Prognostic role of oestrogen, progesterone and androgen receptor in relation to patient age in patients with breast cancer. *Breast* 1996 5:123–6
9. Langer M, Kubista E, Schemper M, et al. Androgen

receptors, serum androgen levels and survival of breast cancer patients. *Arch Gynecol Obstet* 1990 247:203–9

10. Brentani MM, Franco EL, Oshima CTF, et al. Androgen, estrogen and progesterone receptor levels in malignant and benign breast tumors: a multivariate analysis approach. *Int J Cancer* 1986 38:637–42

11. Isola JJ. Immunohistochemical demonstration of androgen receptor in breast cancer and its relationship to other prognostic factors. *J Pathol* 1993 170:31–5

12. Bocuzzi G, Di Monaco M, Brignardello E, et al. Dehydroepiandrosterone antiestrogenic action through androgen receptor in MCF-7 human breast cancer cell line. *Anticancer Res* 1993 13:2267–72

13. Hackenberg R, Hawighorst T, Filmer A, et al. Medroxyprogesterone acetate inhibits the proliferation of estrogen- and progesterone-receptor negative MFM-223 human mammary cancer cells via the androgen receptor. *Breast Cancer Res Treat* 1993 25:217–24

14. Poller DN, Snead DRJ, Roberts EC, et al. Estrogen receptor assay in carcinoma in situ of the breast: relationship to flow cytometric analysis of DNA and expression of the c-erbB2 oncoprotein. *Br J Cancer* 1993 68:156–61

15. Poller DN, Ellis IO. Ductal carcinoma in situ (DCIS) of the breast. In: *Progress in pathology*, Vol. 2. Edinburgh: Churchill Livingstone, 1995 47–87

16. Hsu S-M, Raine L, Fanger H. Use of avidin–biotin–peroxidase complex (ABC) in immunoperoxidase techniques: a comparison between ABC and unlabelled antibody (PAP) procedures. *J Histochem Cytochem* 1981 29:577–80

17. Norton AJ, Jordan S, Yeomans P. Brief, high temperature heat denaturation (pressure cooking): a simple and effective method of antigen retrieval for routinely processed tissues. *J Pathol* 1994 173:371–9

18. Gatalica Z. Immunohistochemical analysis of apocrine breast lesions. Consistent overexpression of androgen receptor accompanied by the loss of estrogen and progesterone receptors. *Pathol Res Pract* 1997 193:753–8

19. Reiner A, Neumeister B, Spona J, et al. Immunocytochemical localization of estrogen and progesterone receptor and prognosis in human primary breast cancer. *Cancer Res* 1990 50:1057–61

