

Original Article

Morphological Changes in Hippocampal CA1 Area in Diabetic Rats: A Golgi-impregnation Study

Mehrdad Roghani¹, Mohammad Taghi Joghataie², Mohammad Reza Jalali Nadoushan³,
Tourandokht Baluchnejadmojarad⁴, Farshad Roghani Dehkordi⁵

1. Department of Physiology, School of Medicine, Shahed University, Tehran.
2. Department of Anatomy, School of Medicine, Iran University of Medical Sciences and University of Social Welfare and Rehabilitation (USWR), Tehran.
3. Department of Pathology, School of Medicine, Shahed University, Tehran.
4. Department of Physiology, School of Medicine, Iran University of Medical Sciences, Tehran.
5. Department of Internal Medicine, School of Medicine, Shahrekord University of Medical Sciences, Shahrekord.

ABSTRACT

Background and Objective: Although diabetes mellitus is known to be one of the risk factors for dementia but neuropathic changes in the brain of diabetic patients have not been completely revealed. Therefore, this research study was done to evaluate structural changes in pyramidal neurons of hippocampal CA1 area of male diabetic rats using Golgi-impregnation method.

Materials and Methods: Male Wistar rats were randomly divided into control and diabetic groups. For induction of diabetes, streptozotocin (STZ) was injected (i.p.) at a single dose of 60 mg/kg. At the end of 1st and 2nd months, rats were transcardially perfused and Golgi-impregnation method was used to evaluate the changes of dendritic spines in CA1 area.

Results: It was found out that there was a significant reduction in mean density of pyramidal neuron dendritic spines after 1 and 2 months in diabetic group as compared to age-matched controls ($p < 0.05$ and $p < 0.01$ respectively).

Conclusion: Taken together, there is a time-dependent pattern in diabetes-induced modification of dendritic architecture in CA1 area that itself is strongly involved in some aspects of learning and cognitive processes.

Key words: CA1, Pyramidal neuron, Golgi staining, Diabetes mellitus, Rat

Received: 5 August 2006

Accepted: 10 October 2006

Address communications to: Dr. Mehrdad Roghani, Department of Physiology, School of Medicine, Dehkadeh Street, Keshavarz Blvd, P.O.

Box: 14155-7435, Tehran-IRAN

E-mail: mehjour@yahoo.com

Introduction

Although diabetes is known to be one of the risk factors for dementia but neuropathic changes in the brain of diabetic patients have not been completely revealed. Neuropathy is one of the major complications contributing to morbidity in patients with diabetes mellitus. Diabetes leads to a wide range of peripheral neuronal deficits including reduced motor nerve conduction velocity, impaired sciatic nerve regeneration, axonal shrinkage in association with reduced neurofilament delivery, and deficient anterograde axonal transport (1-2). In rats with diabetes experimentally induced by streptozotocin (STZ), the nerve damage observed parallels in many ways the nerve degeneration seen in human diabetic neuropathy (3). In addition, pathological studies have suggested that diabetes is one of the risk factors for senile dementia of Alzheimer type (4). Although, many studies about the relationship between diabetes and peripheral neuropathy have been done to date, but the effects of diabetes on the brain itself have not been studied and no gross abnormality has been found in the central nervous system of patients with diabetic neuropathy (5).

On the other hand, diabetes mellitus is itself accompanied with disturbances in learning, memory, and cognitive skills in the human society and experimental animals (6). Since hippocampus, especially its CA1 area has been implicated in learning and memory processes (7) and recently some noticeable morphological changes in dendritic spines have been reported in cerebral cortex of 4-weeks diabetic rats (5), therefore, this research study was conducted to evaluate morphological changes of pyramidal neurons of hippocampal CA1 area in male diabetic rats using Golgi-impregnation method.

Materials and Methods

The experimental protocol of this research study was conducted at school of medicine, Shahed university, Tehran in 2005. Male albino Wistar rats (Pasteur's institute, Tehran, Iran) weighing 290-320 g (10-12 weeks old) were housed in an air-conditioned colony room on a light/dark cycle (20-22°C and 30-40% humidity) and supplied with

standard pelleted diet and tap water ad libitum.

The animals (n=32) were initially randomly divided into 2 groups: control (n=16) and diabetic (n=16), each subdivided into 2 identical subgroups. Diabetes was induced by a single intraperitoneal injection of streptozotocin (STZ, 60 mg/Kg) dissolved in cold 0.9% saline solution immediately before use. Diabetes was verified by a serum glucose level higher than 250 mg/dl using glucose oxidation method (glucose oxidase kit, Zistchimie, Tehran).

Golgi-impregnation method

At the end of 1st (n = 16) and 2nd (n=16) months, Golgi-impregnation method was used to evaluate the changes of dendritic spines in CA1 region of control and age-matched diabetic rats (8). Briefly, animals were transcardially perfused with a solution of 0.1 M phosphate buffer containing 4% paraformaldehyde (pH 7.4). After removing the brains, they were incubated in 1% potassium dichromate, 1% mercury chloride, 0.8% potassium chromate, and 0.5% potassium tungstate in distilled water at 20 °C for 14-16 days. After rinsing the brains with distilled water, they were incubated in 1% lithium hydroxide and 15% potassium nitrate in distilled water at 20 °C for two other days. Forebrains were cut on a freezing microtome (Leica, Germany) at -10 °C at a thickness of 50 µm (the blocks were soaked in gradient concentrations of 10% and 30% sucrose in phosphate buffer (0.1 M) for an overnight and at least 2 days respectively). The sections were rinsed free floating in double distilled water, dehydrated in a series of ethanols, cleared with xylene, mounted onto gelatinized slides, and then coverslipped under entelane.

Data analysis

Spines were counted on apical dendrites of pyramidal neurons of hippocampal CA1 area. In this respect, spines were readily identifiable at a magnification of 800 using an Olympus light microscope with digitalized photography facility. Pyramidal neurons were defined by the presence of a basilar dendritic tree, a distinct single apical dendrite, and dendritic spines. Spines were identified based on the morphological criteria

for mushroom and thin spines. Meanwhile, only protrusions perpendicular to the dendritic shaft and possessing a clear neck and bulbous head were counted. These spine types make up approximately 80-85% of the spine population. For each animal, spines were counted on 10–15 neurons. For each animal, those cells that exhibited dark and consistent impregnation throughout the cell body and dendritic tree and its relative isolation from neighboring impregnated neurons that else could interfere with analysis were selected for evaluation. For each of the cells selected, the number of spines on at least four segments of the apical dendritic tree was determined. No primary dendrites were analyzed, and all of the segments selected for analysis were located 100–150 μm away from the cell body and not located at the terminal of a dendrite. Computer-assisted tracings were made for each of the dendritic segments, and the length was determined using Image tool analysis software. The data were expressed as mean values of spine densities (number of spines per 100 μm) for each animal.

For statistical analysis, unpaired student's t-test was used for comparing control and diabetic groups. All data were expressed as mean \pm SEM. Meanwhile, statistical significance was considered as $p < 0.05$.

Results

The body weight of the diabetic and normal rats was not different at the beginning of the study. After induction of diabetes, there was a marked significant reduction (as expected) in this parameter in diabetic group after 1 ($p < 0.05$) and 2 months ($p < 0.01$). Regarding serum glucose level, there was no significant difference between control and diabetic groups before the study. In addition, diabetic group showed a significant increase in serum glucose level at the end of months 1 and 2 ($p < 0.001$).

Light microscopic examination of Golgi-impregnated tissue of CA1 area revealed reliable and consistent staining. Tracing of the apical dendrites of pyramidal neurons revealed significant changes in the number of dendritic spines from diabetic rats as compared to age-matched control

group after 2 months (Figure 1). Quantitative analysis of the spine density of these neurons clearly revealed a significant decrease in the number of these spines after 1 and 2 months (Figure 2), suggesting that spine and dendritic morphology may be sensitive to such stressful conditions like diabetes. In addition to changes in the number of spines per selected length of dendrite, the shape of remaining spines appeared to be different between diabetic and intact rats. In this respect, dendritic spines of diabetic rats showed fewer and less pronounced protrusions as compared to intact animals (Figure 1). In contrast, measurement of cell body area did not show a significant difference between diabetic and intact rats.

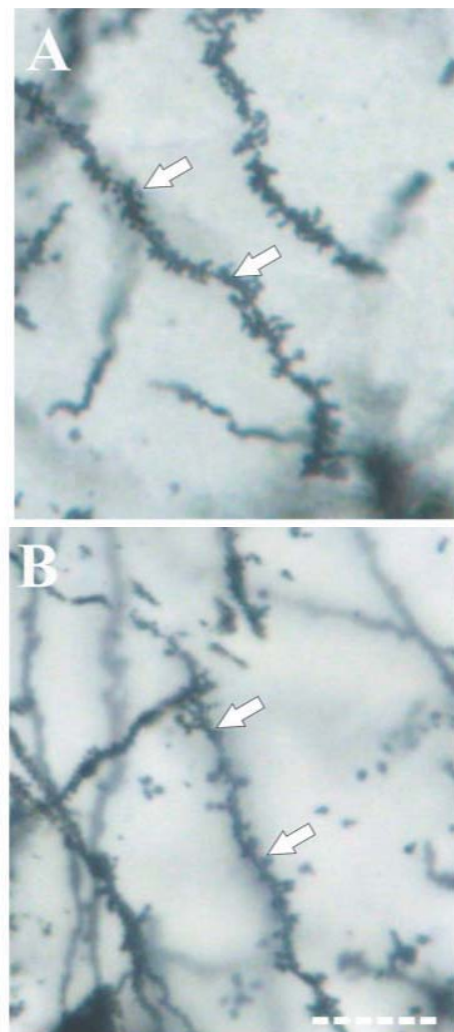


Figure 1: Photomicrograph of Golgi-impregnated dendritic tree and related spines from pyramidal neurons of hippocampal CA1 area in intact (A) and age-matched diabetic (B) rats two months after the study. Scale bar = 10 μm .

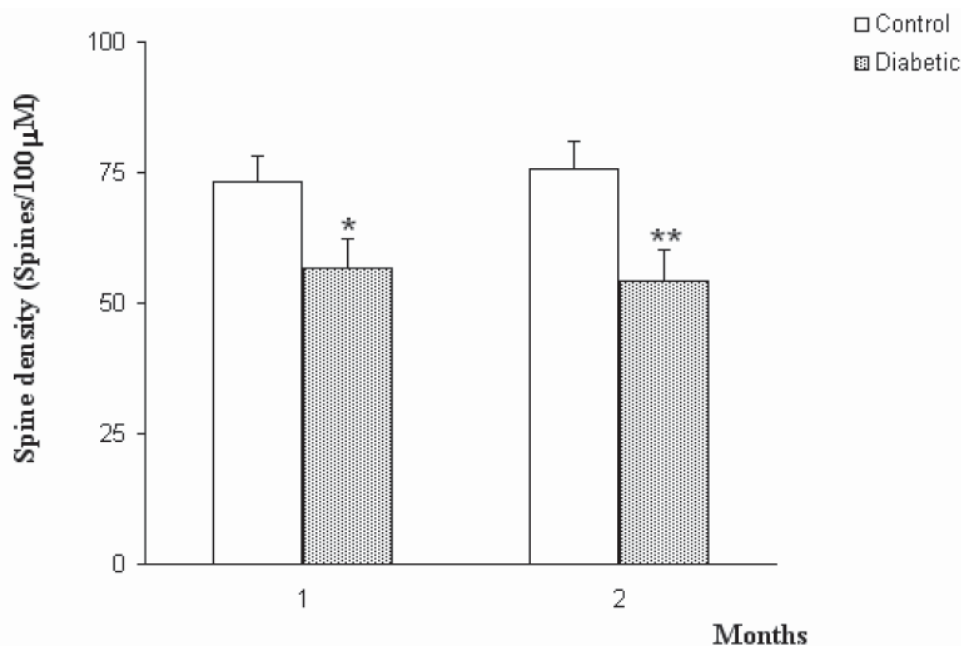


Figure 2: Mean spine density per selected length on the apical dendrites from pyramidal neurons of hippocampal CA1 area of intact and age-matched diabetic rats after one and two months. Vertical bars represent SEM values. Asterisk indicate significant difference relative to untreated controls (* $p < 0.05$; ** $p < 0.01$).

Discussion

Although severe peripheral neuropathy has been reported in diabetic patients, but the diabetic brain has not been studied so much and its possible dysfunctions have remained to be clarified. According to existing data, Alzheimer's patients have a relatively high frequency of diabetes mellitus (9). However, no significant differences between diabetic and control subjects with respect to severity of Alzheimer-type pathologies including both senile plaques and neurofibrillary tangles have been observed (9). In addition, diabetics show impaired cognitive performance relative to age-matched control subjects (6). It seems that diabetes induces impairment of cognitive performance; however, the decrease of learning ability may not be restricted to only Alzheimer's disease (2). In this research study, body weight of diabetic rats was significantly different from those of the control rats. Meanwhile, cell number and possible morphological changes in the brains of the diabetic rats were studied. Previous studies have failed to find any changes in neuronal cell number using Nissl staining (5). In Golgi staining as was used in this study, morphological changes were evident in

hippocampal CA1 area from diabetic rats after one and two months. Similar morphological changes have been observed in the hippocampus at the time of delayed neuronal death induced by the transient global cerebral ischemia in rodents (10). The initiating event that leads to delayed neuronal cell death is possibly neuronal excitation caused by glutamate and subsequent calcium influx into the cell. Abnormal influxes of glutamate and/or calcium might also occur in diabetic brain, because the expressions of calbindin, synaptophysin, and syntaxin were reduced in such brains, which are proteins related to a Ca^{2+} binding protein or synaptic secretions (6). Their level indicates the degree of expression of glutamate, which initiates the release of other neuronal transmitters. Unusual influxes of glutamate and/or calcium might cause the morphological changes in the diabetic brain (11), as observed in this study. The neuronal cell death induced by ischemia is due to a failure of recovery process following excitatory damages to this particular neuronal circuitry (12). Lack of several neurotrophic factors such as BDNF or NGF is also considered to cause the neuronal cell death after ischemia (13).

Conclusion

this present report provides the first evidence that diabetes induces a reduction in the spine density of apical dendrites of hippocampal CA1 area in one- and two-month diabetic rats. Further studies are warranted to investigate the detailed mechanisms that lead to these abnormalities.

Acknowledgement

This research study was supported by a grant from Research Council of University of Social Welfare and Rehabilitation (USWR, Tehran) in 2004. The authors sincerely appreciate the collaboration of Mrs. Maryam Sharayeli and Miss Fariba Ansari (School of Medicine, Shahed University).

References

1. Baydas G, Nedzvetskii VS, Nerush PA, Kirichenko SV, Yoldas T. Altered expression of NCAM in hippocampus and cortex may underlie memory and learning deficits in rats with streptozotocin-induced diabetes mellitus. *Life Sci.* 2003 73:1907-16
2. Sima AA, Li ZG. The effect of C-peptide on cognitive dysfunction and hippocampal apoptosis in type 1 diabetic rats. *Diabetes.* 2005 54:1497-505
3. Reagan LP, McEwen BS. Diabetes, but not stress, reduces neuronal nitric oxide synthase expression in rat hippocampus: implications for hippocampal synaptic plasticity. *Neuroreport.* 2002 13:1801-4
4. Popovic M, Biessels GJ, Isaacson RL, Gispen WH. Learning and memory in streptozotocin-induced diabetic rats in a novel spatial/object discrimination task. *Behav Brain Res.* 2001 122:201-7
5. Nitta A, Murai R, Suzuki N, Ito H, Nomoto H, Katoh G, Furukawa Y, Furukawa S. Diabetic neuropathies in brain are induced by deficiency of BDNF. *Neurotoxicol Teratol.* 2002 24:695-701
6. Parihar MS, Chaudhary M, Shetty R, Hemnani T. Susceptibility of hippocampus and cerebral cortex to oxidative damage in streptozotocin treated mice: prevention by extracts of *Withania somnifera* and *Aloe vera*. *J Clin Neurosci.* 2004 11:397-402
7. Christian A, Heidbredera, Henk J, Groenewegen. The medial prefrontal cortex in the rat: evidence for a dorso-ventral distinction based upon functional and anatomical characteristics. *Neuroscience and Biobehavioral Reviews* 2003 27: 555–579
8. Fujioka T., Sakata Y., Yamaguchi K., Shibasaki T., Katok H., Nakamura S. The effects of prenatal stress on the development of hypothalamic paraventricular neurons in fetal rats. *Neuroscience* 1999 92:1079-1088
9. Harris Y., Gorelick P.B., Freels S., Billingsley M., Brown N., Robinson, D. Neuroepidemiology of vascular and Alzheimer's dementia among African-American women, *J. Natl. Med. Assoc.* 1995 87: 741–745
10. Shigeno T., Mima T., Takakura K., Graham D.I., Kato G., Hashimoto Y., Furukawa S., Amelioration of delayed neuronal death in the hippocampus by nerve growth factor, *J. Neurosci.* 1991 11: 2914– 2919
11. Wisniewski K, Fedosiewicz-Wasiluk M, Holy ZZ, Car H, Grzeda E. Influence of NMDA, a potent agonist of glutamate receptors, on behavioral activity in 4-week streptozotocin-induced diabetic rats. *Pol J Pharmacol.* 2003 55:345-51
12. Artola A, Kamal A, Ramakers GM, Biessels GJ, Gispen WH. Diabetes mellitus concomitantly facilitates the induction of long-term depression and inhibits that of long-term potentiation in hippocampus. *Eur J Neurosci.* 2005 22:169-78
13. Lupien SB, Bluhm EJ, Ishii DN. Systemic insulin-like growth factor-I administration prevents cognitive impairment in diabetic rats, and brain IGF regulates learning/memory in normal adult rats. *J Neurosci Res.* 2003 74:512-23

