

Case Report

Coincidental Hydatid Cyst of Skin and Kidney: A Very Rare Case Report

Bijan Rezakhaniha, Soheila Sirosbakht

Dept. of Urology, Army University of Medical Sciences, Tehran, Iran

ABSTRACT

Human echinococcosis remains a complex problem that affects several organs. Hydatid disease mainly (85%) affects liver as well as lung, and 10% the rest of the body. Renal involvement is about 2% while skin hydatidosis is nearly 1%. Coincidental involvement of kidney and skin is very rare. We report a 51 year-old female patient with renal and skin (chest wall) hydatid lesions that were excised radically and the diagnosis of hydatidosis was confirmed histologically in EMAM REZA Hospital, Tehran in 2007. For treatment albendazol 400 mg BID was chosen, followed by monthly inspection of liver and CBC control up to six months. The case did not show any sign of recurrence in 24 months of following up.

Key words: Hydatid Cyst, Kidney, Skin, Iran

Introduction

Hydatidosis is known since Hippocrates. Echinococcosis or hydatidosis is caused by tapeworm, *Echinococcus granulosus*. The highest prevalence of hydatidosis is in the countries, where the common intermediate hosts, sheep and cattle, are raised (such as Middle East, Central Europe, Australia, and South America). Hydatid disease mainly affects the pulmonary and digestive system, liver 75%, lung 15% and the rest of the body as 10% (1). No part of human anatomy is invulnerable to hydatid cyst. Renal hydatidosis occurs in only about 2% of cases (2) and skin hydatid in 1% (3, 4). Coincidental involvement of kidney and skin is very rare. We have

not encountered any previously reported case in Iran or other countries as we searched the internet. The appearance of kidney can become unusually cystic or occasionally look like a diffuse solid tumor. In this patient ultrasonography and CT report indicated RCC (renal cell carcinoma) and hydatid cyst test was negative, but due to previous history of chest wall hydatid surgery, hydatid involvement of kidney was suspected and the patient underwent surgery by retroperitoneal instead of intraperitoneal excision.

Case Report:

A female, 51 year old, housewife was admitted with nonsymptomatic mass in abdominal ultrasonography

Received: 5/1/2009

Accepted: 9/21/2009

Address communications to: Dr Bijan Rezakhaniha, NO:13, amir elah st, naceri st, Dolat st, Tehran, Iran

Email: Reza.bijan@yahoo.com

in Emam Reza Hospital, Tehran in 2007. She lives in Tehran, Iran. No history of fever and weight loss was given. Investigation revealed that chest X-ray, liver test; urinalysis, BUN, Cr, CBC (WBC 10500, eosinophil 3%) was within normal limits. The first hour sedimentation rate was 30mm. Hemagglutination test for hydatidosis and ELISA were negative. Ultrasonography revealed twelve cm solid mass with central necrosis at middle-lower pole of left kidney (Fig. 1). Computed tomography (CT) demonstrated solid mass with enhancement and renal cell carcinoma diagnosis. CT showed no involvement of liver and others organs (Fig. 2).

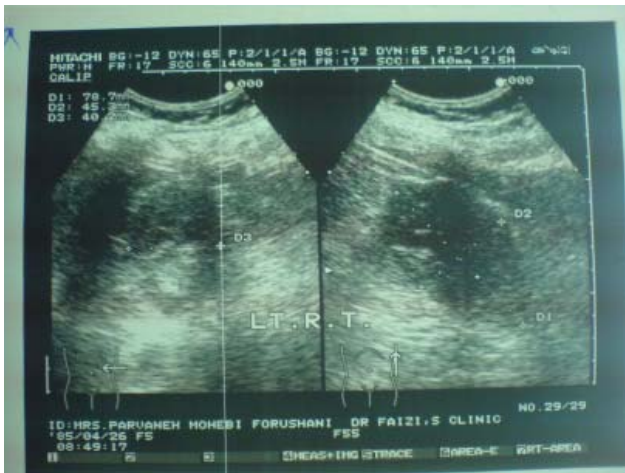

Fig. 1. Sonography shows 12 cm solid mass with central necrosis at middle-lower pole of left kidney

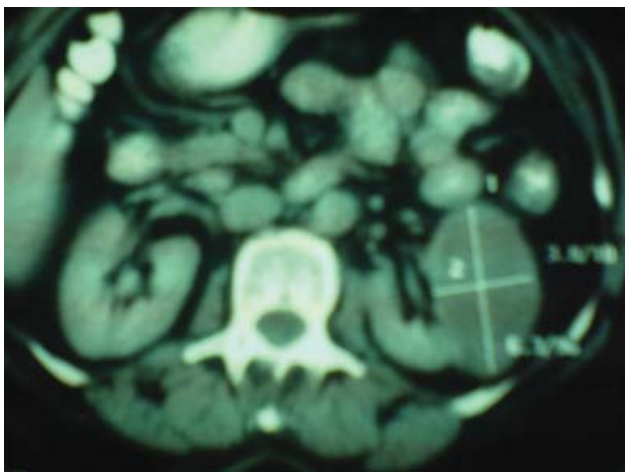


Fig. 2. CT image shows solid mass with enhancement and RCC diagnosis

The patient had history of chest wall's skin surgery two month ago with pathological report of hydatid cyst. The patient had no history of contact with sheep and

dog. With possible diagnosis of renal cell carcinoma, the patient underwent surgery for excision of the kidney but in flank position and retroperitoneal instead of intraperitoneal incision. Solid mass with peripheral adhesion and engorged vessels at mid portion of kidney was seen and radical nephrectomy was done. However, pathological diagnosis was hydatidosis. Macroscopic report showed the specimen consists of kidney measuring 12×10×4cm accompanied by some irregular fragments of adipose tissue. Cut section of the kidney revealed a white-color thin-wall cyst measuring 9cm in greatest diameter near one pole. Wall-thickness of cyst was 0.1cm. Microscopic examination (hematoxylin-eosin, ×40) showed a cyst wall lined by germinal layer composed of flat cells and laminated layer (Fig. 3). Hemorrhagic areas were seen within the periphery of cyst. Albendazol 400 mg twice daily was chosen as the treatment regimen for her. Monthly liver test and CBC was done regularly up to six months. During the follow up period, chest radiology, abdominal ultrasonography, routine blood biochemistry (glucose, ALT, AST, alkaline phosphates, blood urea nitrogen, creatinine) and indirect hemagglutination test were performed. The case did not show any sign of recurrence in 24 months of following up.

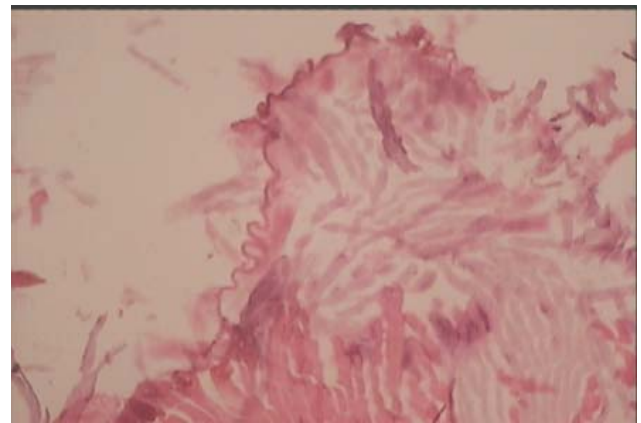


Fig. 3. Photomicrograph shows a cyst wall lined by germinal layer composed of flat cells and laminated layer (H&E staining ×400)

Discussion

Any part of the body is vulnerable to hydatid cyst, but renal hydatid occurs in about 2% and skin 1% (5-7) of cases. In the kidney or other urogenital sites, hydatid cyst evolves by slow, asymptomatic concentric growth over years and may invoke pressure

symptoms or flank pain (8). The most common urologic presentation is chronic dull flank or lower back discomfort from cystic pressure, rarely with microscopic hematuria. The cysts being focal, seldom affect renal function. Diagnosis can be made by ultrasonography or computed tomography (CT) and MRI, which show a thick-walled, fluid-filled spherical cyst, often with a calcify cyst wall. Ultrasonography is the most valuable tool for both the diagnosis and treatment of cystic hydatid disease. Benign renal cyst can be distinguished by the absence of either internal membranes of hydatid sand (9). Other differential diagnosis such as infected cyst, abscess, and solid tumor should be considered (10). Serologic test has proved useful. The diagnosis can be supplemented by specific IgG complement fixation, indirect fluorescent and ELISA tests. ELISA/Western blot serology is 80-100% sensitive and 88-96% specific for liver cyst, but less sensitive for lung (50-56%) or other organ involvement (25-26%) (11). After surgical excision of the cyst reagenic antibody (IgE) titers decrease and become negative after 1-2 years (10, 11). If titers do not decrease, recurrence of hydatidosis should be considered. Hydatid serology is only valuable when it is positive, negative serologic test dose not exclude the diagnosis. Some patients may require surgery owing to the size or location of the lesion. There are other options such as percutaneous treatment of the hydatid cyst with irrigation of 0.9% NaCl and 10% povidone iodine (12); as well as laparoscopic approach on selected patients who refuse open surgical treatment (13). In general, surgery is the treatment of choice in renal hydatid cyst (14, 15). Kidney sparing surgery is possible in most cases (75%) and nephrectomy (25%) must be reserved for destroyed kidney (16). Albendazol 400 mg twice daily for one to six months is recommended as medical therapy. Praziquantel has been recommended preoperatively or in the case of operative spillage of cyst contents. In the 1950 surgery's at 38 medical centers in Tehran-Iran, kidney involvement was 2.56 % and skin 1.02 %, but no simultaneous involvement has been reported (17). Median ages of patients were 25-35 years (17). Coincidental involvement of kidney and skin is very rare and similar to this case has not been reported previously. In our patient, sonography and CT, report were RCC and hydatid cyst test was negative

but because of history of chest wall hydatidosis, hydatid involvement of kidney was considered and retroperitoneal instead of intraperitoneal surgery was elected. This case illustrates that Echinococcus disease should be considered in the differential diagnosis of every cystic mass in any anatomic location, especially in endemic areas. Before surgical excision or biopsy and extirpation of the cyst, diagnosis of the hydatidosis should be excluded. If there is the history of hydatid cyst in any organ, involvement of other organs must be considered, even if specific serologic test and radiographic studies are not confirmatory (18).

Acknowledgment

We especially thank Dr Mostafapour E, MD and Gohari K, MD (Department of Pathology, Army University of Medical Sciences, Hospital 501, Tehran-Iran) for their assistance and surgical pathology report. The authors declare that they have no conflicts of interest.

References

1. Kouskos E, Chatziantoniou J, Chrissafis I, Anitsakis C, Zamtrakis S. Uncommon locations of hydatid cysts. *Singapore Med J* 2007;48(4):e119-e121.
2. Khanna AK, Prasanna GV, Khanna R, Khanna A. Unusual sites of hydatid cysts in India. *Trop Doct* 2005;35(4):233-5.
3. Duttaroy DD, Kacheriwala S, Duttaroy B, Jagtap J, Patel G, Modi N. Giant hepatic hydatid cyst with sub-fascial extension treated by open minimally invasive surgery: a case report. *J Med Case Reports* 2008;28;2:26.
4. Chevalier X, Rhamouni A, Bretagne S, Martigny J, Larget-Piet B. Hydatid cyst of the subcutaneous tissue without other involvement: MR imaging features. *AJR Am J Roentgenol* 1994;163(3):645-6.
5. King HK, Wood L, Steffens Z, Johnson C. Spinal anesthesia for cesarean section: isobaric versus hyperbaric solution. *Acta Anaesthesiol Sin* 1999;37(2):61-4.
6. Orhan Z, Kara H, Tuzuner T, Sencan I, Alper M. Primary subcutaneous cyst hydatid disease in proximal thigh: an unusual localisation: a case report. *BMC Musculoskelet Disord* 2003;7;4:25.:25.
7. varez-Sala R, Gomez de Terreros FJ, Caballero P. Echinococcus cyst as a cause of chest wall tumor. *Ann Thorac Surg* 1987;43(6):689-90.

8. Retic W, Wein V. Campbell's Urology. 8th ed. Philadelphia: Saunders; 2002.
9. Kilciler M, Bedir S, Erdemir F, Coban H, Sahan B, Ozigok Y. Isolated unilocular renal hydatid cyst: a rare diagnostic difficulty with simple cyst. *Urol Int* 2006;77(4):371-4.
10. Saidi F. Surgery of hydatid disease. Philadelphia: Saunders; 1976.
11. Braunwald E, Hauser S, Longo D, Jameson J, Fauci A. Harrison's Principles of Internal Medicine. New York: McGraw-Hill; 1995.
12. Aribas B, Dingi G, Kosar S, Ungul U. Percutaneous treatment in a type 4 renal hydatid cyst. *Eur J Radiol* 2006;57(3):103-7.
13. Demirkesen O, Yavuz N, Citgez S, Onder AU, Kural AR. Case report: laparoscopically-treated giant renal hydatid cyst. *J Endourol* 2008;22(3):529-32.
14. Stead M, Angus K, Holme I, Cohen D, Tait G. Factors influencing European GPs' engagement in smoking cessation: a multi-country literature review. *Br J Gen Pract* 2009;59(566):682-90.
15. Atan A, Col C, Dolapci M, Hokelek M. A case of pure renal hydatid cyst without multiple organ involvement. *Int Urol Nephrol* 1997;29(1):1-4.
16. Zmerli S, Ayed M, Horchani A, Chami I, El OM, Ben Slama MR. Hydatid cyst of the kidney: diagnosis and treatment. *World J Surg* 2001;25(1):68-74.
17. Dalimi A, Motamedi G, Hosseini M, Mohammadian B, Malaki H, Ghamari Z, *et al.* Echinococcosis/hydatidosis in western Iran. *Vet Parasitol* 2002 Apr 30;105(2):161-71.
18. Uras C, Alponat A, Akçal T, Balcisoy U. Retroperitoneal Hydatid Cyst: An Unusual Primary Location. *Dig Surg* 1993;10(1):49-51.