

Case Report

Placental Site Trophoblastic Tumor: Clinical and Pathological Report of Two Cases

Zohreh Yousefi¹, Nourieh Sharifi², Shohreh Saeed¹

1. Dept. of Obstetrics and Gynecology, School of Medicine, Mashhad University of Medical Sciences, Mashhad, Iran

2. Dept. of Pathology, School of Medicine, Mashhad University of Medical Sciences, Mashhad, Iran

ABSTRACT

Placental site trophoblastic tumor (PSTT) is the rare variant of gestational trophoblastic diseases (GTD), which differs histologically and immunologically from GTD. Diagnosis of PSTT is often difficult and delayed. In most cases, diagnosis is not possible until the surgery is performed. The most therapeutic choice is hysterectomy and it is usually successful. Here we report two cases of PSTT.

Keywords: Placental Trophoblastic Tumor, Human Chorionic Gonadotropin, Iran

Introduction

Placental site trophoblastic tumor (PSTT) is a type of gestational trophoblastic diseases (GTD). PSTT has unique microscopic, ultra structural, and immunohistochemical features. This rare tumors arises from the implantation-site intermediate trophoblast. It accounts for about 1% of all GTDs with only 100 cases have been reported so far. The underlying pathology is a proliferation of the intermediate trophoblastic cells (1).

In most cases it is possible to recognize this disorder in tissue-sample (curettage). Diagnosis of PSTT is

often difficult and delayed, because it produces less beta-HCG. It can occur as early as one week or as late as many years after abortion, normal delivery, or molar pregnancy.

In spite of the above mention data the majority of the cases have shown good prognosis. Moreover rapidly metastasizing, and fatal cases have been reported. The overall mortality rate is 25%. The most factors, which might be associated with adverse outcome, are disease extension beyond the uterus. The most common metastatic sites are the lung, liver and vagina (2).

Received: 28 June 2009

Accepted: 28 November 2009

Address communications to: Dr Zohreh Yousefi, Department of Obstetrics and Gynecology, Mashhad University of Medical Sciences, Mashhad, Iran

Email: yousefiz@mums.ac.ir

Since PSTT is less sensitive to chemotherapy than other GTDs, hysterectomy is the mainstay of treatment; however, Mangili reported a case of PSTT with complete response to chemotherapy (3).

These are on the grounds of the reports of the patient's poor response to chemotherapy and today's complete long term remission is reported with combination chemotherapy in some cases of PSTT(4).

According to the rarity of PSTT and complete response in one patient to treatment, despite advanced stages of the disease, we present these cases in this article.

Casereports

Case 1:

A 25-year-old woman (G4 L2 ab1) was admitted for continued vaginal bleeding after two months of the termination of hydatidiform molar pregnancy. (Metastatic work-up before surgery was not able to show any sites of metastases in other organs). She underwent D&C due to the excessive vaginal bleeding; the elevation of β hCG level (which was 257- to 1310 MIU/ML) and finally residual product, which was indicated by ultrasonography. Histopathological report of curettage indicated PSTT (Fig. 1).

We had to consider three factors before final treatment after D&C:

- 1-Continuous vaginal bleeding after curettage
- 2- The possibility of poor response of this disease to chemotherapy
- 3- Lack of patient's tendency to have more pregnancies.

According to these criteria, we decided on a hysterectomy and subsequently performed this operation on the patient. Histopathology of specimen was equivocal to uteri with atypical trophoblast cells containing few cytoplasm and hyperchrom nuclei and high mitotic index which were infiltrated into the uterine wall. The cells infiltrate forward among the smooth muscle fibers which correlated with the term of exaggerated placental-site reaction (Fig. 2). Two months after surgery the patient had normal level of β hCG titer and was recommended to have serial follow-up in feature.

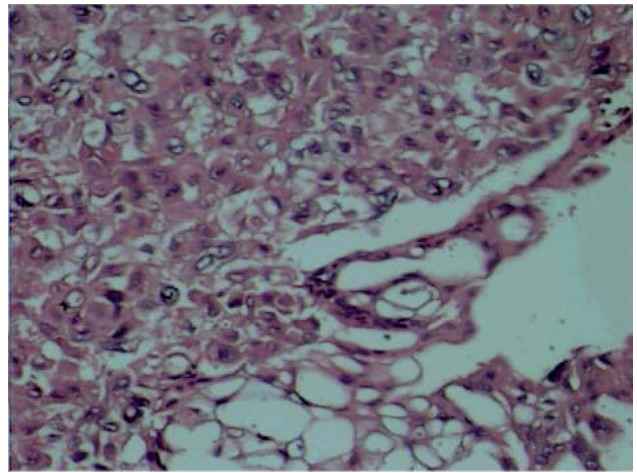


Fig. 1: High magnification of PSTT demonstrates sheets of intermediate trophoblastic cells and few or scattered multinucleated syncytiotrophoblastic cells (H&E staining $\times 400$)

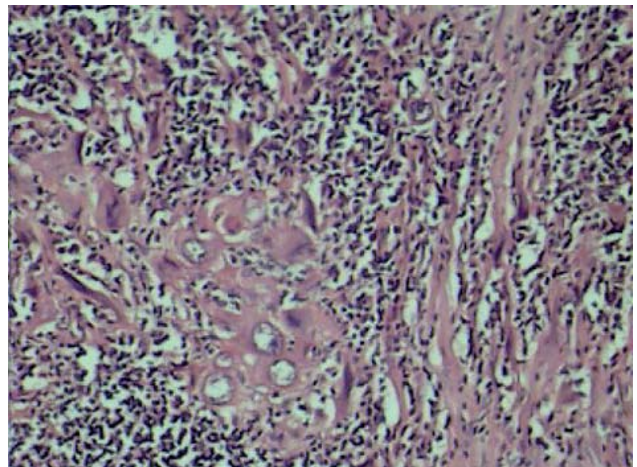


Fig. 2: PSTT showing intermediate trophoblastic cells separating smooth muscle fiber of myometrium (H&E staining $\times 400$)

Case 2:

This 30-year old woman (G3 L1 ab1) was admitted for abdominal distention that happened after one year of her missed period. In personal history, we encountered a molar pregnancy that happened five years ago. She had general edema, ascites, and respiratory distress. In pelvic examination a soft, diffused, and large uterus as big as a ten-week pregnancy was detected. β hCG also proved to be positive. Ultra sonography showed large uterus with echogenic area in the myometrium and peritoneal fluid and Chest X-Ray revealed lung metastasis and plural effusion. She underwent D&C

and histopathology examination showed PSTT (Fig. 3). Because she had one child, chemotherapy with EMA/CO regimen was decided on, but the regimen was not successful because she showed excessive pulmonary distress, and the response to the therapy was also poor, so subsequently she was sent to ICU. When her condition became stable again, she underwent operation (simple hysterectomy). PSTT was detected in histopathology report of specimen (Fig. 4) and after a few weeks of operation she responded completely and now, after five years of serial follow-up she is disease free.

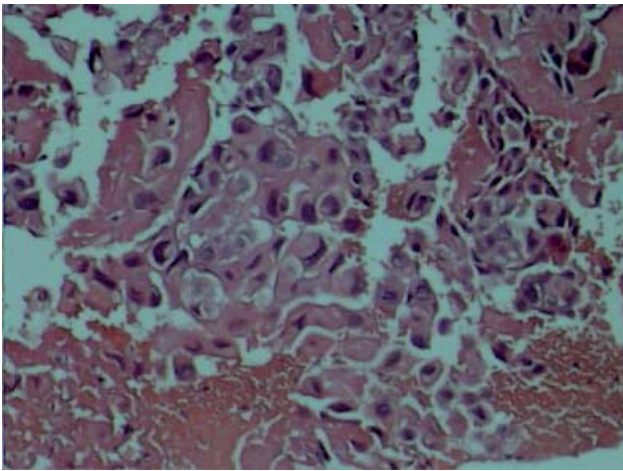


Fig. 3: High magnification of PSTT shows proliferated intermediate trophoblastic cells in fibrinoid material (H&E staining $\times 400$)

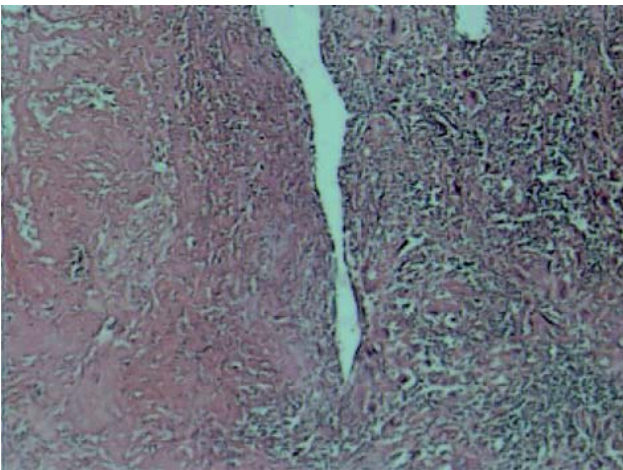


Fig. 4: PSTT showing nests of intermediate trophoblastic cell in hyaline background infiltrating the myometrium (H&E staining $\times 100$)

Discussion

PSTT is rare tumor of the intermediate trophoblastic cells with malignant potential. In 1895, Marchand used the term of atypical choriocarcinoma for PSTT. The present terminology comes from Kurman who described this pathology in 1976 as pseudotumor and regarded it as an exaggerated reaction of placental site. As it became clear, the underlying pathology is a proliferation of the intermediate trophoblastic cells (5). Molecular data support the trophoblastic nature of PSTT. In this article, pathological report of the first case was the exaggerated placental site reaction and the second one PSTT had reported. The first symptom of the disease is usually seen after delivery or abortion and the dominant signs of the clinical picture are vaginal bleeding and enlargement of the uterus. It can be presented with amenorrhea, galactorrhea, nephrotic syndrome or just raised serum HCG level (6). One of our cases had secondary amenorrhea and the other suffered from vaginal bleeding, so the possibility of PSTT should be kept in mind in cases with GTD who HCG levels are elevated but not so high as in other GTDs. The explanation of this moderate elevation of HCG titer is that these cells produce primarily HPL and less HCG (7). This is why it may be difficult at times to establish the diagnosis PSTT preoperatively. In this study, we tried to avoid HPL measurement because this parameter was not accessible. Diagnosis in this disease should rely on intense HPL-positivity as well as the ultrastructural image of the tumor, and immunologic markers. In addition to histologic criteria, P57 (KIP2) immunohistochemistry might be helpful (8). Any above mentioned markers can not be used for diagnosis in our cases.

Pathologic features of PSTT has a highly varied gross appearance which usually circumscribed but, some tumors are poorly demarcated, many projected into the uterine cavity or many gross predominantly into the myometrium. Microscopically PSTT is characterized by proliferated large polygonal intermediate trophoblastic cells extension, deposition of fibrinoid material can also be detected (9).

Differentially diagnosed PSTT must be from hydatidiform mole, hydropic abortion, placental mesenchymal dysplasia, non villous forms of GTD, choriocarcinoma, placental site nodule and epithelioid trophoblastic tumor (10).

Therapy of the PSTT is primarily surgery. Hysterectomy is considered to be sufficient in most of the cases. In this research both patients had been treated with surgery and showed complete response in spite of lung metastasis in one case. Chemotherapy is still used as an adjuvant, although the most suitable chemotherapy scheme for PSTT has not been established. It is believed that the EMA/EP and EMA/CO regimens are the most effective as a first line (11).

In Feltmate's 17-year-old experience in PSTT, it is illustrated that two factors are very significant survival indicators in adverse prognosis of PSTT, which are as follows: The length of the interval from last pregnancy to diagnosis and the microscopic findings of high mitotic count (12).

Nievesl *et al.* from East Carolina treated lung metastasis in PSTT patients thorough surgical resection (13).

Aoki *et al.* reported another metastatic PSTT case, which was treated with chemotherapy (14). In our case lung metastases is cured after hysterectomy.

Nowadays chemotherapy methods are available for metastatic and relapsing PSTT. We must notice that combined surgery and chemotherapy is a reasonable option in properly counseled with this disorder (15). The response of our presented patient to chemotherapy was not ideal, so she was treated with surgery. In literature review definitive treatment of these types of lesions is not known and it needs further evaluation.

Finally the process of treatment of all PSTT cases, both clinical and biological behaviors should be considered and meticulously taken care of, due to the difficult nature of them.

References

- Piura B, Shaco-Levy R. Placental site trophoblastic tumor. *Harefuah* 2007; 146(1):62-7, 77.
- Kunz J, Bannwart F. Placental site trophoblastic tumor: case report and review of literature. *Praxis (Bern 1994)*. 2008 Apr 2;97(7):387-94.
- Horn LC, Einkenkel J, Vogel M. Histopathology of gestational trophoblastic disease. An update. *Pathologie* 2009; 30(4):313-23.
- Piura B, Rabinovich A, Meirovitz M, Shaco-Levy R. Placental site trophoblastic tumor: report of four cases and review of literature. *Int J Gynecol Cancer* 2007; 17(1):258-62.
- Li BZ, Zhu L, Duan W. Clinicopathologic study of tumors of intermediate trophoblasts. *Zhonghua Bing Li Xue Za Zhi* 2006; 35(12):722-6.
- Pongsaranantakul S, Kietpeerakool C. Hysterectomy in gestational trophoblastic neoplasia: Chiang Mai University Hospital's experience. *Asian Pac J Cancer Prev* 2009; 10(2):311-4.
- Numnum TM, Kilgore LC, Conner MG, Straughn JM, Jr. Fertility sparing therapy in a patient with placental site trophoblastic tumor: a case report. *Gynecol Oncol* 2006; 103(3):1141-3.
- Kohorn EI. Long-term outcome of placental-site trophoblastic tumours. *Lancet* 2009; 374(9683):6-7.
- Piura B. Placental site trophoblastic tumor--a challenging rare entity. *Eur J Gynaecol Oncol* 2006; 27(6):545-51.
- Kelly T, Alvis C, Abedalthagafi M, Barnes W. Diagnostic evaluation of metastatic placental site trophoblastic tumor. *Obstet Gynecol* 2009; 114(2 Pt 2):465-8.
- Savelli L, Pollastri P, Mabrouk M, Seracchioli R, Venturoli S. Placental site trophoblastic tumor diagnosed on transvaginal sonography. *Ultrasound Obstet Gynecol* 2009; 34(2):235-6.
- Feltmate CM, Genest DR, Wise L, Bernstein MR, Goldstein DP, Berkowitz RS. Placental site trophoblastic tumor: a 17-year experience at the New England Trophoblastic Disease Center. *Gynecol Oncol* 2001; 82(3):415-9.
- Nieves L, Hoffman J, Allen G, Currie J, Sorosky JI. Placental-site trophoblastic tumor with PET scan-detected surgically treated lung metastasis. *Int J Clin Oncol* 2008; 13(3):263-5.
- Aoki Y, Kase H, Kashima K, Yahata T, Tanaka K. Placental site trophoblastic tumor presenting as subaponeurotic metastasis. *Int J Gynecol Cancer* 2005; 15(2):385-8.
- Schmid P, Nagai Y, Agarwal R, Hancock B, Savage PM, Sebire NJ, *et al.* Prognostic markers and long-term outcome of placental-site trophoblastic tumors: a retrospective observational study. *Lancet* 2009; 374(9683):48-55.