

Case Report

Primary Fibrosarcoma of Breast: A Case Report and Review of Literature

Nishat Afroz¹, Sufian Zaheer¹, Nazoora Khan¹, M Amanullah Khan²

1. Dept. of Pathology, J N Medical College, Aligarh Aligarh, UP India

2. Dept. of General surgery, J N Medical College, Aligarh Muslim University, Aligarh, UP India

ABSTRACT

While carcinoma of breast is common condition, stromal sarcomas are rare tumors of breast, amongst which fibrosarcoma accounts for 16% of cases. Only a few case reports are available in the international literature. We report a case of fibrosarcoma of breast, which presented as an un-encapsulated mass in the right breast of a 60-year-old female. This case was diagnosed after exclusion of all possible differential diagnoses namely metaplastic carcinoma, cystosarcoma phylloides and other sarcomas of breast owing to its different histogenesis and prognostic behavior, in the light of detailed histopathological examination and immunohistochemical profile.

Key words: Fibrosarcoma, Breasts, Case Report

Introduction

Primary soft tissue sarcomas (STS) of the breast are malignant tumors arising from the mesenchymal tissue of the breast. By definition, these sarcomas are formed within the breast tissue and sarcomas arising from the skin, muscle and adjacent bones are excluded. Primary breast sarcoma is a rare entity occurring in 0.5% women with breast malignancy (1,2). Like the breast carcinoma, delay in its diagnosis has important clinical and treatment

implications. Stromal sarcomas of the breast in itself have been described as a group of rather homogenous tumours with, “fibrous, myxoid, and fatty patterns” as seen by light microscopy (3). Fibrosarcoma is one of the histological variants of the stromal sarcoma of the breast described in literature accounting for only 16% of all the breast stromal sarcomas (4). Other types include malignant fibrous histiocytoma (44%), liposarcoma (24%), clear cell sarcoma, neurogenic sarcoma, leiomyosarcoma, and alveolar soft part sarcoma each accounting for 4% (4). Taghian *et al.*

Received: 19 January 2010

Accepted: 5 April 2010

Address communications to: Dr.Nishat Afroz, Department of pathology, J N Medical college amu aligarh, UP India.

Email: nishat_ehsaan@yahoo.com

reported 11 soft tissue sarcomas (all histologies) in a review of 7620 breast cancer patients treated with surgery and radiotherapy (5). The rarity of the “primary” sarcoma of breast limits most studies to a few international retrospective case reviews and case reports (6).

The rarity of this condition and its important differential diagnoses having variable clinical outcome prompted us to present this case of primary fibrosarcoma of breast diagnosed in a 60-year-old female. The case is discussed with inclusion of brief review of literature.

Case Report

A 60 years female presented with a lump in right breast of 6 months duration. She had been in menopause for 12 years. On examination, a firm unilateral well-circumscribed lump of 7 cm x 5 cm in size was found in upper lateral quadrant of the right breast. It was free from the deeper tissue and from overlying skin. There was no obvious change in nipple and areola. Routine hematological investigations were within normal limits. Mammographic findings were nonspecific and there were no foci of microcalcification. The whole body scan was normal and there was no evidence of lung or distant metastasis. The smears prepared from the fine needle aspiration of the lump were suggestive of cystosarcoma phylloides. Simple mastectomy was performed. The resultant skin defect was covered with a free split skin graft. The post-operative course was uneventful.

The mastectomy specimen showed an unencapsulated, but well circumscribed nodular tumor of 6x 5 cm size (Fig. 1). The cut surface was firm, homogenous, and gray with punctate areas of necrosis or hemorrhage. No lymph node was received. Eight blocks were taken from the different areas of tumor mass, sections were also taken from the surgical margins, nipple and areola apart from the tumor mass. The paraffin-embedded sections were stained with Hematoxylin and Eosin (H&E), reticulin and Van Gieson stains. Special emphasis was given to tumor architecture, differentiation, cellular atypia, mitotic figures, and areas of necrosis. Immunostaining to rule out epithelial, muscle (smooth and skeletal), osteoid, chondroid and neural differentiation etc. was carried out.

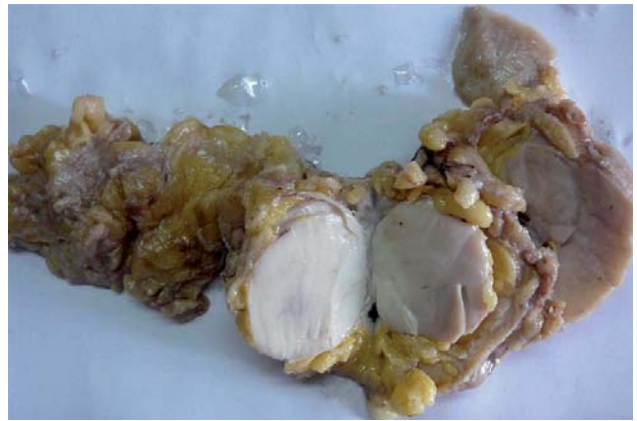

Fig. 1: Shows well circumscribed nodular tumor of 6x 5 cm size with cut surface firm, homogenous, and gray with tiny areas of necrosis or hemorrhage.

Microscopy of sections from tumor area showed a very cellular tumor, exhibiting sheets and fascicles of spindle cells, at places forming storiform and “Herring” bone pattern with mild to moderate nuclear pleomorphism, (Fig. 2). Mitoses were frequent (average 2-3/ 10 high power fields, HPF). Van Geison stain showed large areas of collagen fibers arranged in intertwining whorled bundles and which also surrounded individual cells (Fig. 3). Tumor necrosis was seen occupying less than 20 percent of tumor areas. The fat surrounding the tumour showed strands of normal breast tissue. On careful examination of multiple histological sections, ductular or epithelial components were not seen thereby excluding the possibility of cystosarcoma phylloides or carcinoma morphologically. Neither chondroid osteoid, nor muscle as well as neural differentiation was seen. All the surgical margins were free of tumor infiltrate. Considering the clinical, radiological, and histopathological features a diagnosis of “primary fibrosarcoma of the breast (low grade- stage Ib)” was made.

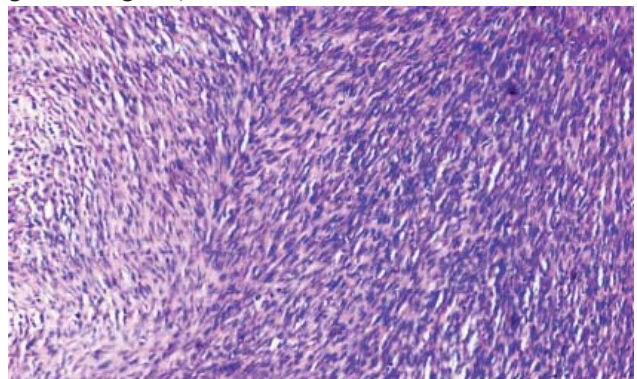


Fig. 2: Sheets of malignant spindle cells forming Herring bone pattern and showing frequent mitosis. (H&E × 200)

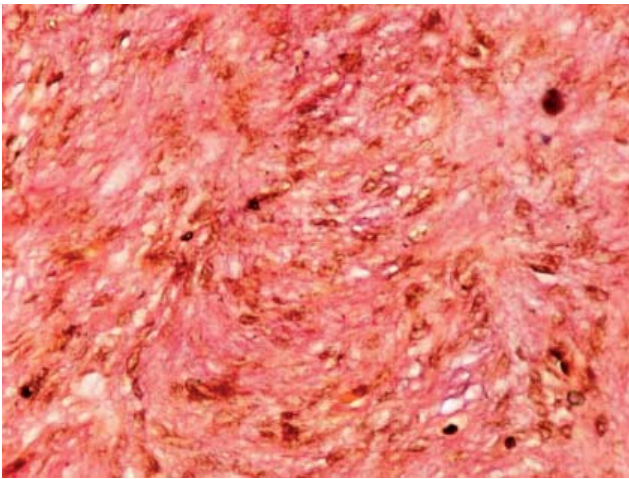


Fig. 3: Abundant collagen around individual spindle cells (Van Gieson $\times 400$)

To exclude other possible diagnoses (e.g. metaplastic carcinoma, other sarcomas etc.), following antibody panels were employed. Dako – mouse monoclonal anti-vimentin (clone 3B4), mouse monoclonal antihuman cytokeratin (clone 34 β E12, 35 β H11 and MNF 116), muscle actin (clone HHF 35), Desmin (clone D33), epithelial membrane antigen (clone E29), neurofilament protein (clone 2F11), glial fibrillary acidic protein (clone 6F2) and S100 polyclonal rabbit anti S100 (N1519 RTU).

None of the immunomarkers gave positive staining reaction except for vimentin which was diffusely positive (Fig. 4) thus excluding all other possible diagnoses of metastatic carcinoma and other sarcomas and thus confirming the histological diagnosis of primary fibrosarcoma of the breast.

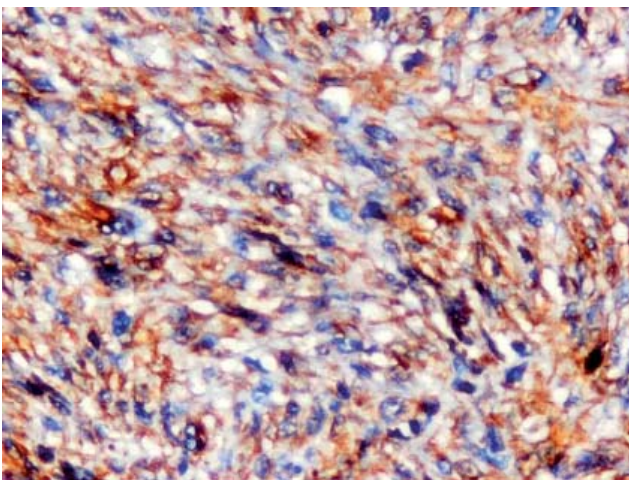


Fig. 4: Immunohistochemistry showing tumor cells exhibiting diffuse vimentin Positivity.

Discussion

Primary soft tissue sarcomas of the breast are composed of a heterogeneous array of histological subtypes that may vary in etiology, natural history, and response to various therapies (7). Fibrosarcoma is a type of malignant stromal sarcoma that rarely occurs in the breast. Among different sarcomas of breast, fibroblastic differentiation is more common than other forms and it originates from mammary fibroblastic tissue (8, 9). As stromal sarcoma of the breast constitutes a specific clinicopathological entity, it is very important that it should be differentiated from malignant cystosarcoma phylloides and metaplastic carcinoma. Moreover, the result could be disastrous when a well-differentiated fibrosarcoma is misdiagnosed as breast fibromatosis and patient develops lung metastasis (3). Biphase tumor with leaf like architecture and accompanying epithelial component helps in the diagnosis of cystosarcoma phylloides, while it is very important to do extensive sampling of the tumor tissue to look for epithelial components in predominantly metaplastic carcinoma, this can be done both by light microscopy and by documenting cytokeratin positivity of the metaplastic cells (10). Absence of any epithelial component and negative staining of a panel of immunomarkers helped the diagnosis of fibrosarcoma to be made, after excluding other possibilities. Deodhar et al and Biswas *et al.* reported a single case of fibrosarcoma of breast, both of which occurred in a 50 year postmenopausal women who presented with a unilateral breast lump of 5cm x 4cm and 9cm x 8cm size respectively without any axillary lymphnode involvement (11, 12).

The peak incidence of primary STS of the breast occurs in patients in their fifth and sixth decades of life, but it has been reported in postmenopausal as well as premenstrual females. The typical clinical presentation of primary breast STS is a unilateral breast mass that grows in size more rapidly than an epithelial breast cancer. The size of these tumors is variable, ranging from less than 1cm to larger than 40 cm. The average size of primary tumor is 5 cm in the largest diameter (13) Tumors that grow rapidly may be painful. The skin overlying the tumor may be discolored. As with STS of the other sites, metastases from primary STS of the breast typically occurs hematogenously, involving the lungs, bone marrow, and liver. Axillary or other lymph node involvement is rare and is generally a harbinger systemic disease.

¹⁵ The mainstay of treatment is surgery. Adjuvant

radiotherapy is considered for select subgroups. Chemotherapy has been disappointing in treatment of breast sarcoma (14).

As with STS of other sites, survival rates, vary widely and are determined by several prognostic features. The reported 5-year survival rates for patient with primary breast sarcoma ranges from 14% to 91% (13). The prognosis rests upon the number of mitotic figures per HPF as well as cellular atypia and tumor size (2). Tumor size less than 5cm and low histologic grade have been associated with improved survival rates (15). The tumors having less than 5 mitotic figures/ HPF have a better prognosis than those with 8-10 mitotic figures/ HPF (12). The tumor grows rapidly and local recurrence after excision is common. Metastasis is commonly seen in the lung, but may occur in the brain, kidney, and the bone but lymphatic spread is rare.

Thus, primary fibrosarcoma of breast is a diagnosis of exclusion and is a rare and unusual tumor. It is important to differentiate this entity from similar looking tumors as they differ histogenetically as well as in biological behavior highlighting the need of thorough sampling and the use of immunostain to arrive at conclusive diagnosis.

References

- Hassan S, Adari G. Primary breast sarcoma: case report. *East Afr Med J* 2004,81(7):375-7.
- Ingle A, Bindu R, Hayatnagarkar N, Bhople K. Fibrosarcoma of breast. *Indian J Pathol Microbiol* 2004,47(2):228-9.
- Payan HM, England DM. Fibrosarcoma mimicking breast fibromatosis. *Am J Med Genet Suppl* 1987,3:257-62.
- Pollard SG, Marks PV, Temple LN, Thompson HH. Breast sarcoma. A clinicopathologic review of 25 cases. *Cancer* 1990,66(5):941-4.
- Taghian A, de VF, Terrier P, Le M, Auquier A, Mouriessse H, *et al.* Long-term risk of sarcoma following radiation treatment for breast cancer. *Int J Radiat Oncol Biol Phys* 1991,21(2):361-7.
- Trent II JC, Benjamin RS, Valero V. Primary soft tissue sarcoma of the breast. *Curr Treat Options Oncol* 2001,2(2):169-76.
- Moore MP, Kinne DW. Breast sarcoma. *Surg Clin North Am* 1996,76(2):383-92.
- Kissaine J. *Anderson's Pathology*. 9 ed. St Louis: The CV Mosby company, 1990.
- Homes Rs, Leis HP, Jr. Liposarcoma of the female breast. Review of the literature and report of a case. *J Am Geriatr Soc* 1962,10:455-9.
- Adem C, Reynolds C, Ingle JN, Nascimento AG. Primary breast sarcoma: clinicopathologic series from the Mayo Clinic and review of the literature. *Br J Cancer* 2004, 91(2):237-41.
- Deodhar SD, Khope S, Kinare SG. Fibrosarcoma of the breast (a case report). *J Postgrad Med* 1983,29(2):122B, 123-122B, 124.
- Biswas S, Chakraborty J, Biswas RK, Rahman QM, Sanyal S, Pal G, *et al.* Primary breast sarcomas-report of two cases. *Indian J Pathol Microbiol* 2002,45(1):93-7.
- Christensen L, Schiodt T, Blichert-Toft M, Hansen JP, Hansen OH. Sarcomas of the breast: a clinico-pathological study of 67 patients with long term follow-up. *Eur J Surg Oncol* 1988,14(3):241-7.
- Harris J, Lippman M, Morrow M, Hellnan S. *Diseases of Breast*. Philadelphia: Lippincott Raven, 1996.
- Gutman H, Pollock RE, Ross MI, Benjamin RS, Johnston DA, Janjan NA, *et al.* Sarcoma of the breast: implications for extent of therapy. The M. D. Anderson experience. *Surgery* 1994,116(3):505-9.