

Case Report

Granulocytic Sarcoma Presenting as Subconjunctival Mass

Fahimeh Asadi Amoli¹, Masoumeh Mohebbi², Amir Hossein Sina¹

1. Dept. of Pathology, School of Medicine, Tehran University of Medical Sciences, Tehran, Iran

2. Dept. of Ophthalmology, School of Medicine, Tehran University of Medical Sciences, Tehran, Iran

ABSTRACT

Chloroma or granulocytic sarcoma (GS) is a malignant neoplasm of myeloid lineage that occur in a variety of anatomic sites other than the bone marrow including soft tissue, bone, lymph node, nasal fossa, skin and sometime in the orbit. In the subconjunctiva it is rarely reported. A 4-year-old girl with a history of treated acute myelogenous leukemia was referred to Farabi Eye Hospital, Tehran, Iran for the evaluation of subconjunctival mass that was appeared since one month ago. Cell blood count (CBC) of the patient was normal except for Hb=7gm/dl. General physical examination was normal except for the signs of anemia. Histopathological evaluation of subconjunctival mass showed a malignant large round cell neoplasm. Immunohistochemical studies confirmed granulocytic sarcoma. When confronting a large cell or undifferentiated round cell neoplasm, the possibility of myeloid sarcoma should be investigated. Myeloperoxidase (MPO), cluster designation (CD) molecules such as CD34, CD45, CD15, CD68 and lysozyme positivity or Leder staining are useful in this regard.

Keywords: Granulocytic Sarcoma, Conjunctivas, Tumor, Iran

Introduction

The term myeloid sarcoma or extramedullary myeloid cell tumor was first introduced by Davey and associates to designate malignant neoplasms of myeloid lineage that occur in a variety of anatomic

sites other than the bone marrow, although chloroma and granulocytic sarcoma are better known synonyms for these neoplasms (1). It may develop prior to, concurrently with or following the onset of classic AML, CML, idiopathic myelofibrosis, hypereosinophilic syndrome & polycythemia vera. In those

Received: 14 December 2010

Accepted: 27 March 2011

Address communications to: Dr Fahimeh Asadi Amoli, Department of Pathology, Tehran University of Medical Sciences, Tehran, Iran

Email: path1383@yahoo.com

with an AML, this presentation may be the only evidence of relapse and in CML, it may show blast crisis phase (2).

The tumor may occur anywhere in the body with peritoneum, soft tissue, bone, lymph node, nasal fossa and skin as the most common sites. Presentation of granulocytic sarcoma in the other organs is rare and there are a few reports of these cases in testis(3,4) cervix (5), breast (6), pancreas (7). In the eye region the most reports of GS are from orbital soft tissue, lacrimal sac, lacrimal gland and epibulbar tissues (1,8-11). Conjunctival GS, especially in bulbar region such as our report, is very rare (12-15). The myeloid sarcoma is more frequent in children than adult is.

Several clues may help to distinguish this entity from other orbital lesions. The lesion seems to mold to the globe and orbital walls on CT and MRI studies, similar to lymphoma. A lateral orbital predilection in contrast to superior or superomedial location of rhabdomyosarcoma is seen (1). A lack of osteolysis speaks against histiocytic and metastatic lesions.

Bilaterality rules out lacrimal epithelial malignancy as well as rhabdomyosarcoma, pointing instead toward leukemia, lymphoproliferative, histiocytic, metastatic or inflammatory entities. MRI may further help make the diagnosis of granulocytic sarcoma, which appears hypointense in T1-weighted images and intermediately intense in T2-weight in contradistinction to peripheral nerve sheath tumor which are more hyperintense in T2-weighting (1).

It is extremely important to diagnose granulocytic sarcoma accurately. A panel of immunohistochemistry is helpful to diagnose GS including, MPO, lysozyme, Leder staining, HLA-DR, MAC373, CD15, CD68, CD34, CD43, LCA, CD3, CD20, EMA, S-100 protein, myogenin, MIC2 etc (16).

Overt leukemia will supervene with 2 to 12 months. Cure is possible if appropriate chemotherapy is introduced before peripheral blood disease occurs (1,2).

Case history

A 4-year-old girl referred to Farabi Hospital, Tehran, Iran- the referral center for eye diseases – with a right eye subconjunctival mass. Her clinical review showed that she had acute myeloid leukemia since 1 year ago for which she underwent chemotherapy. Her follow-up showed no residual disease and she felt good till her subconjunctival mass began to grow since about a month before her referral. Bone marrow study before her referral was unremarkable but her Hb was 7g/dl. Eye examination showed a subconjunctival 1.5 cm cystic mass with prominent vasculature (Fig.1). No other abnormal physical finding was found.

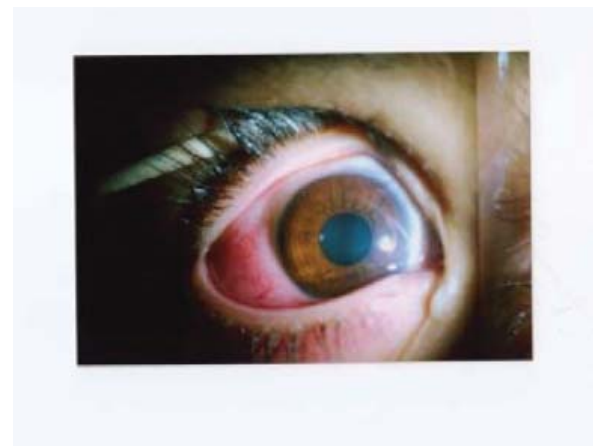

Fig. 1- Patient's eye, a subconjunctival mass with prominent vasculature

An excisional biopsy was done. The gross examination of the sample which was received freshly showed a piece of tan-gray tissue with homogenous cut sections measuring 1.2 cm in maximal diameter. Touch imprint slides were prepared and stained with Wright which showed numerous

cells with high nucleocytoplasmic ratio and open chromatin pattern with no granule or vacuole but some showing multiple nucleoli (Fig. 2). Histopathological sections of the tissue showed a neoplasm beneath stratified squamoid epithelium of conjunctiva with diffuse pattern of growth with a relatively prominent vasculature with no area of necrosis. The neoplastic cells are rather uniform with ill-defined cell margins, round nuclei and prominent multiple nucleoli with high N/C ratio (Fig. 3 & Fig. 4).

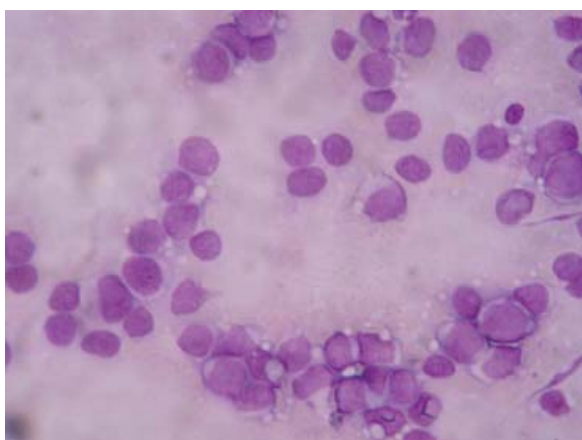


Fig. 2- Cytological smear of granulocytic sarcoma of subconjunctiva, neoplastic cells are discohesive and show round to irregular contours high N/C ratio, Giemsa stain

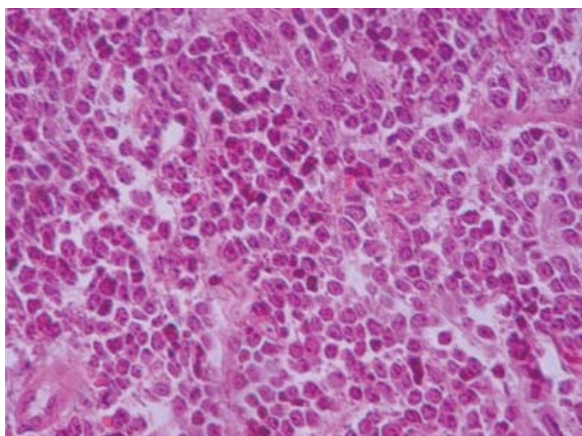


Fig. 3- Conjunctival tissue with subepithelial infiltration of neoplastic cells (×100 H& E stain)

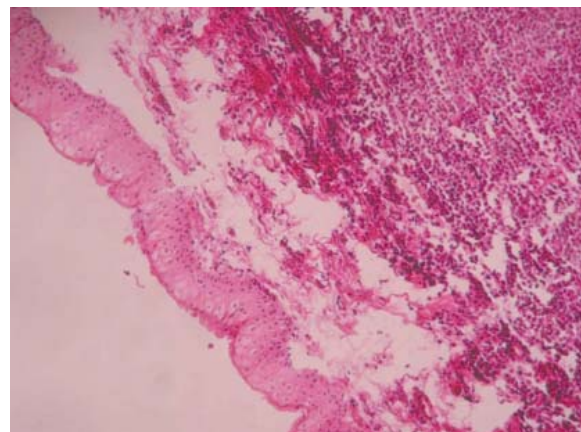


Fig. 4- Histology of granulocytic sarcoma of subconjunctiva, neoplastic cells are rather uniform with round nuclei and prominent nucleoli (×400 H& E stain)

Immunohistochemical staining for myeloperoxidase, lysozyme, CD43, CD68 was diffusely positive. Actin, myogenin, LCA, CD20, CD3, CD45 RO, EMA, S-100protein, vimentin, CD56 and MIC2 showed negative reaction.

Discussion

G.S is a relatively uncommon presentation for acute nonlymphoblastic leukemia and may be presented simultaneously with or prior to bone marrow involvement (16).

Rarely, the first sign of granulocytic leukemia relapse or initially presentation of AML is ocular adnexal involvement. orbital myeloid sarcoma is quit rare among the orbital tumors of childhood, accounting for only 1 of 250 cases (17). There are a few reports of granulocytic sarcoma presenting as conjunctival mass (12-15).

Histopathologically, the tumor has been classified into 1) well differentiated, when numerous eosinophilic myelocytes are seen 2) poorly differentiated when only occasional eosinophilic myelocytes are seen and 3) blastic, if there is no evidence of granulocytic differentiation. This case was blastic form

with lack of any granulocytic differentiation. In regard to past history of patient, (patient had been made a diagnosis of AML 1 years ago) and routine histopathological findings, for definite diagnosis of GS and ruled out differential diagnoses a panel of immunohistochemistry including, myeloperoxidase (MPO), lysozyme, leder staining, CD34, CD43, CD68, LCA, CD3, CD45 RO, CD20, EMA,S-100protein, actin, myogenin, vimentin, CD56, neuron specific enolase (NSE) and MIC2 was done. IHC staining for myeloperoxidase, lysozyme, leder staining, CD43, CD68 was diffusely positive. The myeloid nature of the tumor was identified (16).

Differential diagnosis of a diffuse infiltration of large round cells or undifferentiated round cells neoplasm in view of this location (subconjunctiva) and patient's age, respectively are rhabdomyosarcoma, non-hodgkin's lymphoma, primitive neuroectodermal tumor (PNET) or neuroblastoma. Rhabdomyosarcoma affects children around age 7 years The round cells of rhabdomyosarcoma are more eosinophilic, whereas in leukemic cells the cytoplasm is indistinct except for the rare presence of azurophilic granules. The lack of desmin and myogenin in IHC examination ruled out rhabdomyosarcoma(18).

Extranodal marginal-zone B cell lymphoma of mucosa-associated lymphoma constitutes about 83% of all lymphoma involving the ocular adnexa. It has been reported in a childhood. Although rarely found in the conjunctiva, T-cell prolymphocytic leukemia, a rare and very aggressive hematological neoplasm has presented with bilateral perilimbal conjunctival infiltrate accompanied uveal, palpebral and orbital invasion ((18). Negative reaction for CD20, CD3 & CD45 RO ruled out B-cell and T-cell lymphoma(16).

PNETs are a group of soft tissue tumors of

presumed neural crest origin outside the central and sympathetic nervous system, in eye region it is seen more in the orbit. Histologically consist of a malignant round cells arranged in cellular sheets separated by septae, cell nuclei exhibited uniform chromatin. IHC panel of this tumor showed negative reaction for MIC2, vimentin and CD56, this markers are positive in PNET's cells.

Myeloid sarcoma (extramedullary myeloid cell tumor = EMCT) is more frequently observed in cases with M2 (associated with t(8;21) M4Eo(inv(16) or t(16;16) and M4 or M5 (associated with chromosome 11q23 abnormalities) (2).

When confronting a large cell or undifferentiated round cell neoplasm, in conjunctiva, the possibility of myeloid sarcoma should be investigated

Acknowledgements

The authors declare that there is no conflict of interests.

References

1. William S. Spencer Ophthalmic Pathology. 4th ed. New York: W.B Saunders; 1996.
2. Silverberg S. Principles and Practice of Surgical Pathology and Cytopathology. 4th ed. New York: Churchill Livingstone; 2006.
3. Eggener SE, Abrahams A, Keeler TC. Granulocytic sarcoma of the testis. Urology 2004;63(3):584-5.
4. Lagerveld BW, Wauters CA, Karthaus HF. Testicular granulocytic sarcoma without systemic leukemia. Urol Int 2005;75(1):94-6.
5. Pathak B, Bruchim I, Brisson ML, Hammouda W, Bloom C, Gotlieb WH. Granulocytic sarcoma presenting as tumors of the cervix. Gynecol Oncol 2005;98(3):493-7.
6. Shea B, Reddy V, Abbitt P, Benda R, Douglas V, Wingard J. Granulocytic sarcoma (chloroma) of the breast: a diagnostic dilemma and review of

the literature. *Breast J* 2004;10(1):48-53.

7. Rong Y, Wang D, Lou W, Kuang T, Jin D. Granulocytic sarcoma of the pancreas: a case report and review of the literatures. *BMC Gastroenterol* 2010;10:80.:80.

8. Isik P, Tavit B, Tunc B, Yarali N, Demir A, Cetin M. Extramedullary orbital granulocytic sarcoma without bone marrow involvement: a report of two cases. *Pediatr Hematol Oncol* 2011;28(1):65-70.

9. Thomas SA, Durairaj VD. Isolated myeloid sarcoma presenting in all four eyelids. *Ophthal Plast Reconstr Surg* 2007;23(4):336-8.

10. Kim H, Je B, Lee Y, Kim B. Sino-orbital Granulocytic Sarcoma Causing Bilateral Proptosis As an Initial Manifestation of Acute Myelogenous Leukemia (AML): A Case Report. *J Korean Soc Magn Reson Med*;14(1):74-7.

11. Rajput D, Naval R, Yadav K, Tungaria A, Behari S. Bilateral proptosis and bitemporal swelling: A rare manifestation of acute myeloid leukemia. *J Pediatr Neurosci* 2010;5(1):68-71.

12. Lee DA, Su WP. Acute myelomonocytic leukemia cutis presenting as a conjunctival lesion. *Int J Dermatol* 1985;24(6):369-70.

13. Hon C, Shek TW, Liang R. Conjunctival chloroma (granulocytic sarcoma). *Lancet* 2002 ;359(9325):2247.

14. Rosenberg C, Finger PT, Furlan L, Iacob CE. Bilateral epibulbar granulocytic sarcomas: a case of an 8-year-old girl with acute myeloid leukaemia. *Graefes Arch Clin Exp Ophthalmol* 2007;245(1):170-2.

15. Nau JA, Shields CL, Shields JA, Eagle RC, Rice E. Clinicopathologic reports, case reports, and small case series: acute myeloid leukemia manifesting initially as a conjunctival mass in a patient with acquired immunodeficiency syndrome. *Arch Ophthalmol* 2002;120(12):1741-2.

16. Feng X, Ying J, Li L, Shi S. The Diagnosis and Differential Diagnosis of Granulocytic Sarcoma. *Chinese-German Journal Of Clinical Oncology* 2008;7(10):603-7.

17. Kariogla Z. *Orbital Tumors Diagnosis and Treatment* . New York: Springer; 2009.

18. Yanoff M. *Ocular Pathology* . 6th ed. New York: Mosby; 2009.