

## Original Article

### Quick Score and H-Score Assessment of P504s (AMACR) Expression in Renal Cell Carcinoma (RCC) and Relation with Histologic Grade

Mahmoud Reza Kalantari<sup>1</sup>, Tayyebah Nazeran <sup>1</sup>, Fatemeh Varshoei Tabrizi<sup>2</sup>

1. Dept. of Pathology, School of Medicine, Mashhad University of Medical Science, Mashhad, Iran

2. Dept. of Radiation Oncology, School of Medicine, Mashhad University of Medical Science,  
Mashhad, Iran

#### ABSTRACT

**Background and Aims:** P504S (AMACR) is a mitochondrial enzyme expressed in renal cell carcinoma. Some of immunohistochemical markers in renal cell tumors are independent prognostic factor and show relation with histologic grading. AMACR expression increases with higher histological grading in different tumors; however, in RCC it is not obvious. In this study, we tried to investigate if any relation existed between nuclear grading in renal cell carcinoma and P504S.

**Materials & Methods:** Fort five cases of formalin fixed paraffin embedded tissue of renal cell carcinoma with different nuclear grades were selected and immunostained using primary antibody to P504s and quantified with H-Score, multiplicative (Mqs) and Additive quick score (Aqs).

**Results:** P504S was positive in 37 out of 45 (82%) cases. (Mean  $\pm$  SD) of H-Score: grade I =182 $\pm$ 44, II=218 $\pm$ 161, III=215 $\pm$ 55, IV=190. Mean  $\pm$  SD of Add quick score: grade I= 6.6 $\pm$  1.8, II= 7.24 $\pm$ 1.4, III= 7.78 $\pm$ 1.2, IV= 8. Mean  $\pm$  SD of Multi quick score: grade I= 9 $\pm$  5.6, II= 11.38 $\pm$ 5, III =12.89 $\pm$ 4.7, IV= 12. (Aqs Vs H- Score:  $r = 0.701$ ,  $P < 0.007$ ), (Mqs Vs H-Score:  $r = 0.808$ ,  $P < 0.001$ )

**Conclusion:** P504S is one of the important immunohistochemical markers in primary and metastatic RCC. Our results show that there is no statistically correlation between histological grade of RCC and AMACR staining in semi – quantitative measurement. We suggest AMACR staining to be used as a diagnostic immunohistochemical marker in conjunction with other markers in differential diagnosis of metastatic renal papillary and even clear cell carcinoma.

**Keyword:** AMACR Protein, Renal Cell Carcinoma, Grade

---

Received: 17 August 2011

Accepted: 04 Jan 2012

Address communications to: Dr Fatemeh Varshoei Tabrizi, Department of radiation oncology, Reza radiation oncology center, Mashhad University of Medical Science, Mashhad, Iran

Email: varshoeef@mums.ac.ir

## Introduction

Renal cell carcinoma accounts for approximately 2% of all adult cancers. Its incidence varies among countries, with the highest rates being in North America and Scandinavia. The majority of renal cell carcinomas are of epithelial origin and malignant (1).

The primary treatment of renal cell carcinoma is surgical excision (2). However, one third of renal cell carcinomas are found to invade perinephric fat and/or regional lymph nodes at the time of operation (2).

Some features like tumor stage or nuclear grading in histological findings are related to prognosis (1, 2). Immunohistochemically (IHC), renal cell carcinoma shows reactivity for epithelial markers such as Keratin, EMA, and CEA. Other antigens detected in RCC are CD10 and P504s. P504S is an alpha-methylacyl-coA racemase (AMACR) that plays a role in the beta-oxidation of branched-chain fatty acid and fatty acid derivatives (2).

This marker identified as a molecular marker for prostate and recently kidney cancer and other epithelial tumors (3).

Some of the immunohistochemical markers correlate with nuclear grade and tumor progression. P53 over expression in renal cell carcinoma is associated with metastatic disease and poor survival in patients with early stage disease (2).

The expression of CD44S (the standard isomorph of CD44) demonstrated immunohistochemically correlates with progression and recurrence of renal cell carcinoma. MUC1 expression has been found to correlate with nuclear grade and tumor progression (2). Previous studies revealed renal tubular cells and RCC expressed P504S. In this study, we tried to investigate if any relation existed between nuclear grading in renal cell carcinoma and P504S staining.

## Materials and Methods

### Subjects

We studied 45 paraffin-embedded blocks of renal cell carcinoma diagnosed previously in Ghaem Hospital, Department of Pathology, Mashhad University of Medical Sciences, between March 2008 and April 2010, were included in the study after reevaluation of each case to confirm the diagnosis by two pathologists. We excluded slides with necrosis and hemorrhage.

Nuclear grading was determined according to description by Fuhrman *et al.* by the same observers, with light microscope (Olympus CX30; Olympus optical CO, LTd, Tokyo, Japan) and X100 and X400 objective magnifications.

### Immunostaining for P504s

Multiple 5-µm-thick sections of representative formalin-fixed, paraffin-embedded tissues were cut for immunohistochemical studies. A Polymer-Based (EnVision™) immunohistochemical method was used for the detection of P504s (monoclonal rabbit-AntiHuman-Clone13H4, Dako, Denmark) (Fig. 1&2). Normal gallbladder tissue was used as the positive control (3). Immunostaining without adding antibody was used as the negative control. In some sections, proximal tubular cells of renal tissue were considered as an internal positive control.

### Report

All immunostained sections were examined by the same two observers with a x40 objective and 10×10 eyepiece under the light microscope (Olympus CH30, Olympus Optical Co, LTd, Tokyo Japan) for evaluating of P504s expression. P504s staining was granular and cytoplasmic. Protein expression was scored as negative, weak = faint cytoplasmic or granular apical staining, moderate = diffuse granular cytoplasmic stain and strong = diffuse intense cytoplasmic stain (4). Mild, moderate, and strong staining was considered as positive.

The immunostaining was quantified as H-score

and quick score, a scoring system that has been validated in IHC staining specially in breast cancer (5).

The H- score system was based on the proportion and intensity of brown staining cells. The quick score categories also were based on both the intensity (category B) and the proportion of malignant cells staining positively throughout the section (Category A).

H-Score = (% of cells stained at intensity 1×1) + (% of cells stained at intensity 2×2) + (% of cells stained at intensity 3×3).

H-score between 0 and 300 was obtained where 300 was equal to 100% of tumor cells stained strongly.

Quick Score Categories:

Category A: The proportion of malignant cells staining positively throughout the section.

Category A was assigned score from 1 to 6 (1= 0-4%, 2=5-19%, 3=20-39%, 4=40-59%, 5= 60-79% and 6=80-100%)

Category B: The intensity of the stain was graded as: 0=negative, 1= Weak intensity, 2= Intermediate intensity and 3= Strong intensity

Category A was added to category B (A+B) to form an additive quick score and recorded in parallel with the product (A×B) as a multiplicative quick score.

The product of A+B gives additive quick score between 1-9 and A×B gives a multiplicative quick score between 0-18(5).

For P504s H-score of >20 in 10 fields at ×400 magnification (6) and additive and multiplicative quick scores ≥3 were considered positive (5).

### Statistical analysis

Description of Data was carried out by statistical scatters and tables. Statistical analysis was performed by *t*-test, Anova and their similar parametric. Statistical significance was determined at *P* value < 0.05.

### Results

Forty-five cases including 36 conventional (clear cell), five papillary, one mucinous tubular and spindle cell, two sarcomatoid, one chromophobe renal cell carcinoma were studied.

According to Fuhrman nuclear grading system most of the tumors were nuclear grade II (n=25). There were nine cases of grade III, eight cases of grade I, and three cases of grade IV.

The eight negative cases included six conventional (clear cell), one sarcomatoid variant of RCC and one chromophobe. They were in different nuclear grading. There was no grade III. Three of them were grade I, 4/8 grade II and one out of 8 was grade IV.

Determinations of nuclear grading in tumors were positive for P504 showed that most of them were grade II and III (Table 1).

**Table 1-** Distribution of RCC\* types and grade based on AMACR\*\* positivity

Grade \ Type	I	II	III	IV	Total
Clear cell	5	17	7	1	30
Papillary	0	3	2	0	5
Mucinous tubular	0	1	0	0	1
Sarcomatoid	0	0	0	1	1

\*Renal cell Carcinoma

\*\* AMACR

P504S immunostaining was quantified as H-score and quick score (additive and multiplicative).

The mean of H score, additive and multiplicative quick scores were determined in all of positive P504S sections (Table 2) and in two separate groups as clear all (conventional) and papillary renal cell carcinoma (Table 3).

**Table 2-** Mean of H score, additive and multiplicative quick score (AQS and MQS) according to grade of RCC

Variable	Mean $\pm$ Std Deviation				P value
	GI*	GII	GIII	GIV	
H score	182 $\pm$ 44	218 $\pm$ 61	215 $\pm$ 55	190	0.583
AQS **	6.6 $\pm$ 1.8	7.2 $\pm$ 1.4	7.78 $\pm$ 1.2	8	0.444
MQS ***	9 $\pm$ 5.6	11.38 $\pm$ 5	12.89 $\pm$ 4.7	12	0.577

\* GI

\*\* Additive Quick Score

\*\*\* Multiplicative Quick Score

According to variance analysis no statistically significant correlation was found between mean of H score, additive and multiplicative quick score and nuclear grade of tumor ( $P=0.583$ ,  $P=0.444$ ,  $P=0.577$ ).

Table 3 reveals a comparison of the spearman rank correlation coefficient. There was no significant correlation between histological grade and our parameters (H score, additive and multiplicative quick score) ( $P=0.69$ ,  $P=0.16$ ,  $P=0.145$ )

**Table 3-** Spearman rank correlation coefficient for relationship between H score, Additive and multi quick score and nuclear grade of RCC \*

Variable	Grade	
	Coefficient correlation	P value
H-Score	0.067	0.692
AQS **	0.236	0.16
MQS ***	0.244	0.145

\* Renal Cell Carcinoma

\*\* Additive Quick Score

\*\*\* Multiplicative Quick Score

Table 4 shows that a significant statistically relationship is between mean of H-score, additive and multiplicative quick score, and type of renal cell carcinoma (clear cell versus papillary RCC)

**Table 4-** Mean of H-score, add and multi quick score in clear cell and papillary RCC\*

Variable	Clear cell Mean $\pm$ SD	Papillary Mean $\pm$ SD	P value
H-score	195.83 $\pm$ 48	292 $\pm$ 8.36	< 0.001
AQS**	6.97 $\pm$ 1.32	9	0.001 <sup>a</sup>
MQS***	10.13 $\pm$ 4.36	18	< 0.001

\* Renal Cell Carcinoma

\*\* Additive Quick Score

\*\*\* Multiplicative Quick Score

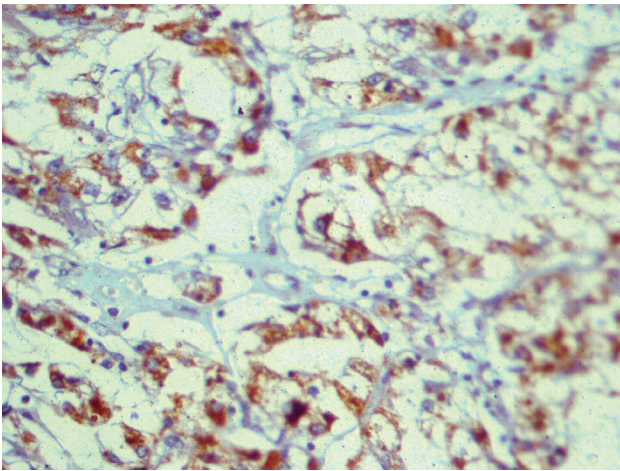
Spearman rank correlation for additive and multiplicative quick score with H-score of P504s in renal cell carcinoma showed a high significant correlation (Table 5).

**Table 5-** Spearman rank correlation coefficients for comparison of various quantitative methods of P504s expression in RCC\*

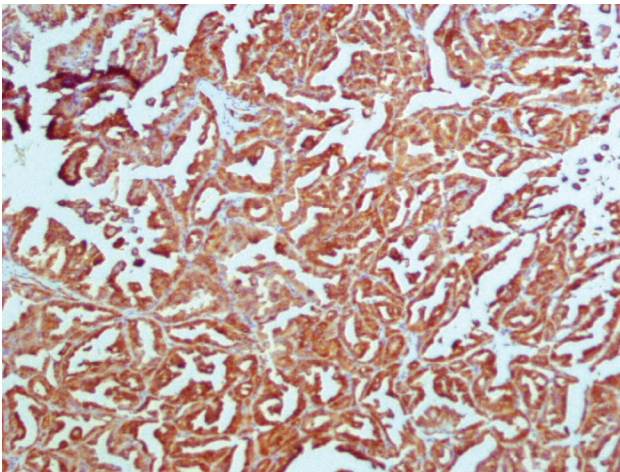
Comparison of methods of measurement	R	P value
Add quick score versus H-score	0.701	< 0.001
Multi quick score versus H-score	0.808	< 0.001

\* Renal Cell Carcinoma





**Fig. 1-** Granular AMCR staining in clear cell RCC ( $\times 400$ )



**Fig. 2-** Strong immunostaining of AMCR in almost 100% of tumoral cells in papillary RCC ( $\times 100$ )

## Discussion

Alpha-methylacyl-coenzyme A racemase (P504s) is a mitochondrial and peroxisomal enzyme which is responsible in the metabolism of branched-chain fatty acid and bile acid intermediates (7). AMACR is expressed in the proximal convoluted tubular epithelium in normal renal parenchyma and its strong immunostaining is present in proximal tubules adjacent to the renal neoplasm (8). Therefore it is possible that some of tumors, which are derived from these structures, express AMACR (9).

Jiang *et al.* showed P504S expression in different normal and tumoral tissues. In normal tissue, high expression of AMACR mRNA was identified in liver, kidney and salivary gland, while AMACR protein was detected in liver (hepatocytes), kidney (tubular epithelial cells), lung (only bronchial epithelial cells), and gallbladder (only mucosal epithelial cells). High expression of AMACR mRNA was found in prostate, liver, and kidney cancers but rarely in stomach and bladder cancers. A high percent of adenocarcinomas arising from these organs express AMACR, including 17 of 21 (81%) of hepatocellular carcinomas and 18 of 24 (75%) of renal cell carcinomas. In addition, they revealed the carcinomas arising from tissues normally not expressing AMACR were also positive for the antigen, including 17 of 18 (94%) prostate carcinomas, 9 of 29 (31%) of urothelial carcinomas, and 4 of 15 (27%) of gastric adenocarcinomas (10).

Predominant AMACR expression in tumors such as adenocarcinoma of the prostate (72%), hepatocellular carcinoma (77%), papillary renal cell carcinoma (70%) and colorectal adenocarcinoma (71%), is revealed by microarray analysis (11). AMACR as an immunohistochemical marker exhibits different expressions in tumors according to their histological grades and stages.

Gunia *et al.* exhibited a correlation between P504S expression and histopathologic grading in non-invasive bladder carcinoma. They investigated AMACR expression in 163 noninvasive bladder cancers. Fifty-two (31.9%) of the cases were AMACR positive. They found a significant positive correlation between AMACR expression and higher tumor grades. They concluded these novel findings clearly allow including high-grade noninvasive bladder carcinomas in the group of AMACR-positive neoplasms (12).

Langer *et al.* in their series evaluated the detection of P504s in upper urinary tract urothelial carcinomas. They could explore a relation with high tumor grade among 83 out of 124 (66.9%)

of high-grade urothelial carcinomas. They also showed that AMACR expression was associated with the presence of tumor necrosis and marked stromal desmoplasia. In conclusion, they suggested increased AMACR expression might be related to hypoxia-induced changes in cancer cell metabolism, such as increased dependence on fatty acid oxidation for energy generation (13).

Rain kuefer *et al.* suggested a hypothesis about AMACR expression in poorly differentiated tumors. They believe that as tumors become dedifferentiated, they no longer require beta-oxidation of fatty acids (AMACR pathway) and may be they take over other pathways so these dedifferentiated tumors no longer express P504 protein (14).

AMACR is a sensitive and specific immunohistochemical marker of prostatic malignancies. Murphy AJ *et al.* showed heterogeneous expression in prostatic cancer in high Gleason score. In their study, 38% of tumors showed less than 75% tumor cells staining. This was significantly correlated with increased Gleason score (15). P504S levels in prostatic cancer were not associated with Gleason score, tumor stage and tumor size (16). Therefore, P504S can be a good predictor of high histological grading in some tumors. In current study, we tried to investigate its expression in different grades of RCC.

We investigated 45 cases of renal cell carcinoma with different subtypes and grades. Thirty-seven out of 45 demonstrated AMACR expression. 5/5 papillary and 1/1 mucinous tubular and spindle cell RCC expressed alpha-methylacyl coA racemase with strong granular cytoplasmic staining and H- score  $\geq 280$ , additive quick score (AQS) =9 and multiplicative quick score (MQS)=18. These findings are the same as previous studies introduced P504s as a key immunohistochemical stains for Papillary and mucinous, tubular and spindle cell RCC (17).

All sarcomatoid variants of RCC (0.15) were negative for AMACR (18). However, in current

experiment, among two sarcomatoid variants of RCC AMACR expression was detected in one case with moderate intensity (H-score=190, AQS=8, MQS=12). Although in current study there was few cases of sarcomatoid variant of RCC, AMACR expression in this type showed that renal cell carcinoma with sarcomatoid change can demonstrate p504s staining.

Molinie *et al.* demonstrated AMACR expression in 64 out of 110 renal tumors. They did not consider tumor histologic grade (9). One chromophobe RCC was totally negative, as reported in previous studies (9).

AMACR expression in RCC is investigated in different series but correlation with nuclear grading has been considered in few series. Grade is one of the most prognostic factors in patients with renal cell carcinoma. Ficarra *et al.* studied prognostic value of renal cell nuclear grading in 333 cases as a multivariate analysis. They showed that nuclear grading is related to medium tumor size, cancer pathologic stage, vascular invasion, lymphnodes involvement and distant metastases, like Fuhrman study (19).

Lin *et al.* investigated 115 renal neoplasm and 28 metastatic renal cell carcinoma. Their results demonstrated that a granular, cytoplasmic staining pattern for P504S was observed in 63 out of 115 primary renal tumors and 23 out of 28 metastatic renal cell tumors. Lin *et al.* assessed P504s expression among 70 cases of clear cell RCC and P504s detection was seen in 40%, 71%, 94%, and 75% of RCCs with Fuhrman nuclear grade I, II, III, IV respectively (20). They just mentioned their observations and they did not conclude any relation between grading and AMACR staining. They just have mentioned that positivity of P504s in higher grades could be helpful in diagnosing RCC with granular cytoplasm presenting with intermediate to high-grade nuclear features (20).

This study examines AMACR expression in RCC in different histological nuclear grades. Although we could not find any significant statistically

correlation between histological grading and P504s staining, based on our data, among 45 cases of renal cell carcinoma, positivity of P504s was seen in 60%, 88%, 100%, 66% of cases with Fuhrman nuclear grade I, II, III, IV. Mean of H-score increased from grade I to II ( $182 \pm 44$  to  $218 \pm 61$ ) and mean of additive and multiplicative quick score increased from grade I to II and grade II to III. Mean of AQS I to II ( $6.6 \pm 1.8$  to  $7.24 \pm 1.4$ ) II to III ( $7.24 \pm 1.4$  to  $7.78 \pm 1.2$ ) and mean of MQS I to II ( $9 \pm 5.6$  to  $11.38 \pm 5$ ) II to III ( $11.38 \pm 5$  to  $12.89 \pm 4.7$ ). There are similarities between our results and Lin *et al.* study.

Tretiakova *et al.* showed AMACR expression in 41 of 41 papillary renal cell carcinoma. They showed that the extent and intensity of P504S expression did not correlate with nuclear grade of tumors in papillary RCC (18). In our investigation, all of papillary RCC demonstrated AMACR staining with high H-score and Quick score independent of nuclear grading. Researchers' showed AMACR as a useful marker in metastatic carcinomas (21).

AMACR was negative in 47 out of 51 papillary carcinomas from different organs like thyroid, lung, breast, pancreas, endometrium, and ovary (18). The authors suggested P504S as a valuable marker in differential diagnosis of a metastatic papillary carcinoma.

Lin *et al.* study exhibited immunoreactivity for P504s in 82% of metastatic RCC with more than 50% immunopositive tumor cells. They recommended this marker to have diagnostic value in a small biopsy of metastatic tumor (20). Stolicu S *et al.* have reported a 73-year old female with a left ovarian tumor mass that was strongly positive for CD10 and AMACR and negative for CK7. This confirmed the renal origin of this ovarian tumor (22). To the best of our knowledge correlation of P504s expression with histological grade in RCC and diagnostic utility of this marker in metastatic RCC has not been evaluated in large series to date.

In conclusion, in our opinion, it seems that there

is no statistically correlation between AMACR expression and histological grade of RCC. Since few studies have been done in this subject, we recommend more studies with more cases of different histologic grades to investigate this probability.

A high significant correlation was found between H-score and quick score for this marker. (Aqs Vs H- Score:  $r = 0.701$ ,  $P < 0.007$ ), (Mqs Vs H- Score:  $r = 0.808$ ,  $P < 0.001$ ) (Table 4- 6). As a result, we can use quick score in evaluation of P504s staining instead of H-score.

According to review of articles, it is obvious that AMACR can be used as a diagnostic immunohistochemical marker in differential diagnosis of metastatic papillary and even clear cell tumors.

## Conclusion

P504S is one of the important immunohistochemical markers in primary and metastatic RCC. Our results show that there is no statistically correlation between histological grade of RCC and AMACR staining in semi – quantitative measurement. We suggest AMACR staining to be used as a diagnostic immunohistochemical marker in conjunction with other markers in differential diagnosis of metastatic renal papillary and even clear cell carcinoma.

## Acknowledgement

We have special thanks to research assistance of Mashhad University of Medical Science to support our study. The authors declare that there is no conflict of interests.

## References

1. Mills SE, Carter D, Reuter VE, Greenson JK, Stoler MH, Oberman HA. Sternberg's diagnostic surgical pathology. 4<sup>th</sup> ed. Philadelphia: Lippincott Williams and Wilkins; 2004.
2. Rosai J. Rosai And Ackerman's surgical pathology.



10<sup>th</sup> ed. Philadelphia: Elsevier;2011.

3. Dabbs DJ. Diagnostic Immunohistochemistry. 2<sup>nd</sup> ed. Philadelphia: Elsevier;2006.

4. Nessar A, Amin MB, Sexton DG, Cohen C. Utility of alpha-methylacyl coenzyme A racemase (P504s antibody) as a diagnostic immunohistochemical marker for cancer. *Appl Immunohistochem Mol Morphol* 2005;13(3): 252-5.

5. Detre S, Jotti GS, Dowsett M. A "quick score" method for immunohistochemical semiquantitation: validation for estrogen receptor in breast carcinomas. *J Clin pathol* 1995;48(9):876-8.

6. Sharifi N, Ayatollahi H, Ghaffarzadegan K, Ghiasi MT, Farhmand MJ, Jafarian AH. Quickscore assessment in Bcl-2 and Bax protein expression in invasive ductal carcinoma of breast and relation with other molecular markers. *Virchow Archiv* 2008;452(Suppl):S131-S132.

7. Kim H, Cho NH, Kim DS, Kwon YM, Kim EK, Rha SH, *et al.* Renal cell carcinoma in south korea: A multicenteric study. *Hum Pathol* 2004;35(12): 1556-63.

8. P504s. 2007. Available at: [www. e-immunohistochemistry. Info/web /P504s. htm](http://www.e-immunohistochemistry.info/web/P504s.htm) 2009.

9 . Molinie V, Balaton A, Rotman S, Mansouri D, De Pinieux I, Homsy T, *et al.* Alpha-Methyl-CoA racemase expression in renal cell carcinomas. *Hum Pathol* 2006;37(6):698-703.

10. Jiang Z, Fanger GR, Woda BA, Banner BF, Algate P, Dresser K, *et al.* Expression of alpha-methylacyl-CoA racemase (P504s) in various malignant neoplasms and normal tissue : a study of 761 cases. *Hum Pathol* 2003;34(8): 792-6.

11. Went PT, Sauter G, Oberholzer M, Bubendorf L. Abundant expression of AMACR in many distinct tumor types. *Pathology* 2006;38(5):426-32.

12. Gunia S, May M, Scholmann K, Storkel S, Hoschke B, Koch S, *et al.* Expression of alpha-methylacyl-CoA racemase correlates with histopathologic grading in noninvasive bladder cancer. *Virchows Arch* 2008;453(2):165-70.

13. Langner C, Rupar G, Leib S, Hutterer G, Chromecki T, Rehak P, *et al.* Alpha-methylacyl-CoA racemase (AMACR/P504s) protein expression in urothelial

carcinoma of the upper urinary tract correlates with tumour progression. *Virchows Arch* 2006;448(3):325-30.

14. Kuefer R, Varambally S, Zhou M, Lucas PC, Loeffler M, Wolter H , *et al.* Alpha-methylacyl-CoA racemase: Expression levels of this novel cancer biomarker depend on tumor differentiation. *Am J Pathol* 2002;161:841-8.

15. Murphy AJ, Hughes CA, Lannigan G, Sheils O, O'Leary J, Loftus B. Heterogenous expression of alpha-methylacyl-CoA racemase in prostatic cancer correlates with gleason score. *Histopathology* 2007;50(2):243-51.

16. Rubin MA, Zhou M, Dhanasekaran SM, Varambally S, Barrette TR, Sanda MG, *et al.* Alpha-methylcoenzyme A racemase as a tissue biomarker for prostate cancer. *JAMA* 2002;287:1662-70.

17. Paner GP, Srigley JR, Radhakrishnan A, Cohen C, Skinnider BF, Tickoo SK, *et al.* Immunohistochemical analysis of mucinous tubular and spindle cell carcinoma and papillary renal cell carcinoma of the kidney: significant immunophenotypic overlap warrants diagnostic caution. *Am J Surg Pathol* 2006;30(1):13-9.

18. Tretiakova MS, Sahoo S, Takahashi M, Turkyilmaz M, Volgelzang NI, Lin F, *et al.* Expression of alpha-methylacyl-CoA racemase in papillary renal cell carcinoma. *Am J Surg Pathol* 2004;28(1):69-76.

19. Ficarra V, Righetti R, Martignoni G, D'Amico A, Piloni S, Rabilotta E, *et al.* Prognostic value of renal cell carcinoma nuclear grading: multivariate analysis of 333 cases. *Urol Int* 2001;67(2):130-4

20. Lin F, Brown RE, Shen T, Yang XJ, Schuerch C. Immunohistochemical detection of P504s in primary and metastatic renal cell carcinoma. *Appl Immunohistochem Mol Morphol* 2004;12(2):153-9.

21. Logani S, Oliva E, Arnell PM, Amin MB, Young RH. Use of novel immunohistochemical markers expressed in colonic adenocarcinoma to distinguish primary ovarian tumors from metastatic colorectal carcinoma. *Mod Pathol* 2005;18(1):19-25.

22. Stolnicu S, Borda A, Radulescu D, Puscasiu L, Berger N, Nogales FF. Metastasis from Papillary renal cell carcinoma masquerading as primary ovarian clear cell tumor. *Pathol Res Pract* 2007;203(11):819-22.