

Case Report

Endometrial Ossification Following Repeated Spontaneous Abortions

Sabina Khan¹, Mohammad Jaseem Hassan¹, Sujata Jetley¹,
Zeeba S Jairajpuri¹, Ayesha Ahmad²

1. Dept. of Pathology, Hamdard Institute of Medical Sciences and Research (HIMSR),
Jamia Hamdard, New Delhi, India

2. Dept. of Obstetrics & Gynecology, Hamdard Institute of Medical Sciences and Research
(HIMSR), Jamia Hamdard, New Delhi, India

ABSTRACT

Endometrial calcification along with ossification is an uncommon clinical entity. Most of the cases are asymptomatic or present with secondary infertility. Endometrial ossification associated with repeated abortions has been reported very infrequently. Here we report a case of endometrial calcification with ossification due to retained fetal bony tissue in a 38 year old symptomatic female having previous history of two abortions. This case highlights the importance of detailed clinical history, ultrasonographic and endometrial evaluation along with histopathological examination in a patient having repeated abortions. It also emphasizes the need to consider endometrial tuberculosis in the differential diagnosis of endometrial calcification and subsequent ossification especially in areas where tuberculosis is rampant.

Keywords: Endometrium, Pathologic Ossification, Spontaneous Abortion

Introduction

The presence of mature bony tissue in the endometrium is a rare entity. Staid in 1928 was the first to describe the presence of a bone in the endometrium of an adult female

(1). Nearly 80 cases have been reported in the world literature including around 10 cases from India (2). Most of the cases have a history of abortion, either spontaneous or therapeutic (3). They usually present with secondary infertility and very rarely are symptomatic. Etiology and

Received: 20 April 2012

Accepted: 25 September 2012

Address communications to: Dr. Mohammad Jaseem Hassan, Department of Pathology, HIMSR, Jamia Hamdard, New Delhi, 110062, India

Email: jaseemamu@gmail.com

pathogenesis of endometrial ossification remains controversial with various theories reported in the literature (4). However, no uniform theory exists to explain all the cases of endometrial ossification.

Here we report a case of endometrial calcification with ossification in a 38 year old female with previous history of two abortions. She presented with abnormal menstrual bleeding, pelvic pain and dysmenorrhea after second abortion 3 years back. Development of symptoms following second abortion at 12 weeks of estimated gestational age (EGA) as well as the histological features of the lesion suggests the possibility of retained fetal bone. This case is being reported because of rarity of endometrial ossification, its association with spontaneous abortions and to emphasize the importance of routine endometrial evaluation in females with history of spontaneous abortions or termination of pregnancy.

Case Report

A 38 year old female, gravida six, parity four and abortus two, presented with pain in the lower abdomen, abnormal vaginal bleeding and dysmenorrhea for the past 3 years. She had experienced two consecutive spontaneous abortions at 10 and 12 weeks of EGA, 5 years and 3 years ago respectively. After the first abortion she underwent Dilatation and Curettage (D&C). However, she did not recall any complaints following the procedure. Four normal full term pregnancies had occurred prior to these two abortions. Her last full term pregnancy was 13 years back with a normal delivery. Since then she had regular menstrual cycles with adequate flow and duration. Patient was not using intrauterine contraceptive device or any other method of contraception. There was no history of urinary calculi, excessive milk or vitamin D intake. However, since past three years she developed pain in lower abdomen, dysmenorrhea and irregular bleeding off and on. She consulted

various medical centres but her symptoms did not subside. She then presented in our hospital where her gynaecological examination was normal except for forniceal tenderness. Her urine pregnancy test was negative. Laboratory investigations were within normal limits. Her serum calcium was 9.5 mg%, phosphorus 2.8 mg% and alkaline phosphatase was 6 KA. Serologic tests for syphilis, anti-phospholipid and antinuclear antibodies were negative. Her Pap smear showed moderate degree of inflammation. An ultrasound was then advised which showed a hyperechoic area in the endometrial cavity measuring approximately 19 mm suggestive of calcified endometrium (Fig. 1).

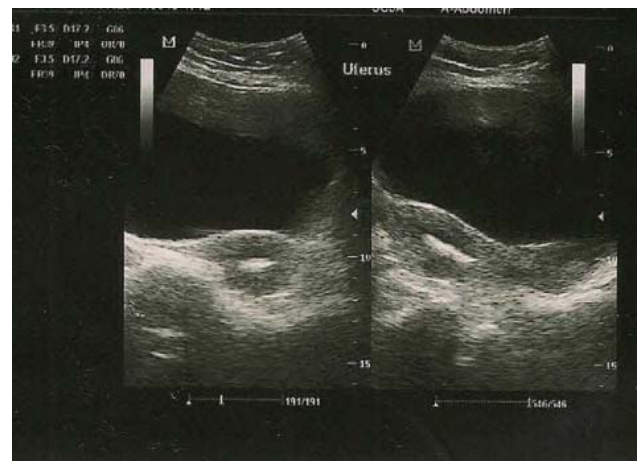


Fig. 1- Ultrasound image showing hyperechoic area in the endometrium.

Patient gave history of contact with tuberculosis patient as her husband was a known case of pulmonary Koch's. Initially tubercular endometritis was suspected in view of positive family history and USG findings. However her Montoux test, ESR and X-ray chest were normal. PCR for tuberculosis was negative. D&C was done and curettage was sent for histopathology. Grossly, one of the tissue bit was bony hard measuring 0.7 cm along with multiple grayish-brown soft tissue pieces aggregate measuring 1.2 cm. Bony hard tissue was decalcified in 5% hydrochloric acid. Microscopic examination revealed fragmented endometrium with glands in proliferative phase

foci of calcification in the endometrial stroma (Fig. 2) along with spicules of mature bone were seen (Fig. 3). Endometrial stroma showed infiltration by plasma cells, eosinophils and lymphocytes with occasional multinucleated giant cells. A histopathological diagnosis of chronic endometritis with endometrial ossification was made.

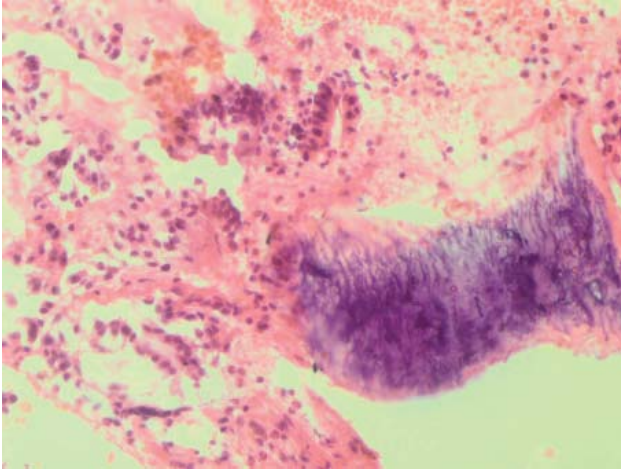


Fig. 2 - Photomicrograph showing foci of calcification in the endometrial stroma (H&E ×400).

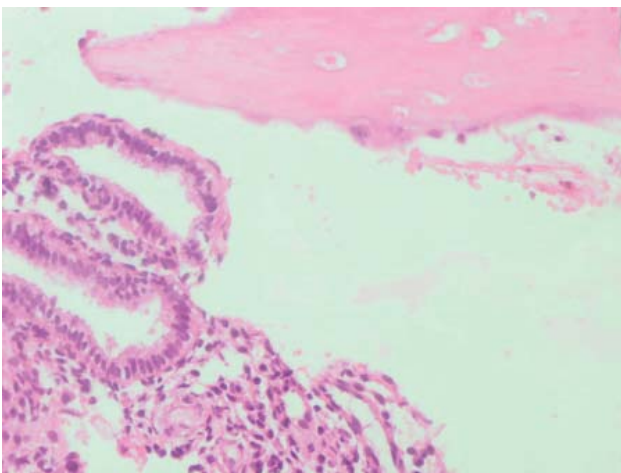


Fig. 3 - Photomicrograph showing endometrial glands and stroma with spicules of mature bone (H&E ×400).

On follow up, the patient showed significant symptomatic improvement after removal of the fragments by curettage. Repeat ultrasonography was also done which showed no evidence of endometrial calcification.

Discussion

Endometrial calcification with ossification is a rare finding usually seen after abortion (5). Various plausible theories have been suggested; most cited being retention of fetal bones after abortion or following termination of pregnancy (6). In our case also there was history of repeated abortions three & five years back. Moreover, the presence of surrounding tissue reaction around endometrial bony tissue along with history of mid trimester abortion suggests the possibility of retained bony tissue. It has been postulated that fetal bones might serve as a source of calcium for ossification. However, this may be valid only for second trimester abortions when ossification of fetal skeleton has reached a certain level. Another possibility is metaplasia of mature endometrial cells into cartilage or bony tissue as a result of chronic inflammation or trauma likely to be present after repeated spontaneous or therapeutic abortion (7). Various other possibilities include dystrophic calcification and ossification of post abortive endometritis, metastatic calcification, hypervitaminosis D and prolonged estrogenic therapy after abortion.

Very few case reports describe an association between endometrial ossification and repeated spontaneous abortions (8). The time lag between the discovery of the endometrial ossification and preceding abortion varies between 8 weeks to 14 years (9,10). In our case it was 3 years after the second abortion. In a study fetal bone had been retained in the endometrium for 8 years following termination, causing only subfertility (11). In majority of the reported cases of endometrial ossification, history of previous abortion is present. Most of them do not make any distinction between intrauterine retention of fetal bones and heterotopic bone formation as their histories and symptoms are almost similar. However, irrespective of the etiology of endometrial bone, its presence has a well documented causal relationship with repeated abortions and infertility. Usually the patients of endometrial ossification present with infertility.

The ectopic bone tissue may act as intrauterine contraceptive device and this possibly explains how intrauterine bony tissue is more frequently associated with infertility than with recurrent abortions (12).

The diagnosis of retained fetal bone or endometrial ossification can be made by visualizing an endometrial hyperechogenic area on ultrasound, a filling defect in the hysterosalpingography or a gritty feel to the endometrium on D&C (13). Primary treatment options are D&C and hysteroscopy. Restoration of complete fertility is reported after complete curettage of bone in the endometrium (8). In our case also marked symptomatic improvement was seen after D&C. In India endometrial tuberculosis should be considered in the differential diagnosis as it can cause infertility as well as calcification and subsequent ossification (14). Initially possibility of tuberculosis was considered. However, her PCR was negative. Another differential to be considered is mixed mullerian tumor of the uterus which may also be associated with heterotopic cartilage formation and stromal ossification. Endometrial ossification or retention of fetal bone is a rare but treatable entity. It needs to be considered in symptomatic females having history of abortions along with endometrial hyperechoic areas on ultrasound. In a country like India where tuberculosis is very common endometrial tuberculosis should also be kept in mind in a patient having endometrial ossification.

Acknowledgements

The authors declare that there is no conflict of interest.

References

1. Wetzels LCG, Essed GGM, deHaan J, van de Kar AJF, Willebrand D. Endometrial ossification: unilateral manifestation in a septate uterus. *Gynecol Obstet Invest* 1982; 14:47-5.
2. T Umashankar, Patted S, Handigund RS. Endometrial osseous metaplasia: Clinicopathological study of a case and literature review. *J Hum Reprod Sci* 2010; 3(2):102-4.
3. Bhatia NN, Hoshiko MG. Uterine osseous metaplasia. *Obstet Gynecol* 1982;60:256-9.
4. Rosa-e-Silva JC, Barcelos ID, Navarro PA, Rosa-e-Silva ACJ, Nogueira AA, Ferriani RA. Osseous metaplasia of the endometrium associated with infertility: a case report and review of the literature. *J Med Case Rep* 2009;3:7427.
5. Bahceci M, Demirel LC. Osseous metaplasia of the endometrium: a rare cause of infertility and its hysteroscopic management. *Human Reprod* 1996;11(11):2537-9.
6. Moon HS, Park YH, Kwon HY, Hong SH, Kim SK. Iatrogenic secondary infertility caused by residual intrauterine fetal bone after midtrimester abortion. *Am J Obstet Gynecol* 1997;176:369.
7. Acharya U, Pinion SB, Parkin DE, Hamilton MP. Osseous metaplasia of the endometrium treated by hysteroscopic resection. *Br J Obstet Gynaecol* 1993;100:391-2.
8. Degani S, Gonen R, deVries K, Shar M. Case report. Endometrial ossification associated with repeated abortions. *Acta Obstet Gynecol Scand* 1983;62:280-1.
9. Waxman M, Moussouris HF. Endometrial ossification following an abortion. *Am J Obstet Gynecol* 1978;130:587-8.
10. Ceccacci L, Clancy G. Endometrial ossification report of an additional case. *Am J Obstet Gynecol* 1981;141:103-4.
11. Al-Shawaf T, Brown J, Keegan C. Retention of fetal bones 8 years following termination of pregnancy. *Ultrasound Obstet Gynecol* 1992;2:61-63.
12. Dajani YF, Khalaf SM. Intrauterine bone contraceptive device: an accident of nature. *Fertil Steril* 1985;3:149.
13. Ghaffari F, Tehraninejad ES, Kiani K. Retained Fetal Bone in Infertile Patients: Two Case Reports. *Royan Institute Int J of Fertil and Steril* 2009;3(3):153-4.
14. Shroff CP, Kudterkar NG, Badhwar VR. Endometrial ossification- report of three cases with literature review. *Indian J Pathol Microbiol* 1985;28:71-4.