

Orthotopic Liver Transplantation for Etanercept-induced Acute Hepatic Failure: A Case Report

Dorsay Sadeghian^{1*}, Farid Azmoudeh-Ardalan¹, Simin Dashti-Khavidaki², Nasir Fakhar³

1. Department of Pathology, Tehran University of Medical Sciences, Tehran, Iran
2. Department of Clinical Pharmacy, Faculty of Pharmacy, Tehran University of Medical Sciences, Tehran, Iran
3. Liver Transplantation Research Center, Tehran University of Medical Sciences, Tehran, Iran

KEYWORDS

Autoimmunity, Etanercept, Hepatitis, Hepatic failure, Liver transplantation

Scan to discover online



Main Subjects:
Hepatopathology

Received 09 Nov 2019;

Accepted 10 April 2020;

Published Online 16 July 2020;

 [10.30699/ijp.2020.117000.2269](https://doi.org/10.30699/ijp.2020.117000.2269)

ABSTRACT

Occurrence of hepatotoxicity following prescription of etanercept, a tumor necrosis factor-alpha (TNF- α) antagonist, is a relatively well-known issue. On the other hand, acute hepatic failure which could lead to liver transplantation is extremely rare to the best of our knowledge, and there is no previously published case in the literature. In this article, we presented a case of acute liver failure followed by liver transplantation, in a 32-year old man with a previous history of ankylosing spondylitis after etanercept usage. On pathologic examination of the explanted liver of the patient, extensive confluent necrosis in all liver segments with prominent infiltration of a mixed population of inflammatory cells in portal tracts was noticed. In conclusion, close follow-up of patients who are receiving etanercept is crucial, since its liver complications could be severe enough to subject the patients for liver transplantation.

Corresponding Information:

Dorsay Sadeghian, Pathology Department, Cancer Institute Tehran University of Medical Sciences, Tehran, Iran.
Email: Dorsay.sadeghian@gmail.com

Copyright © 2020. This is an open-access article distributed under the terms of the Creative Commons Attribution- 4.0 International License which permits Share, copy and redistribution of the material in any medium or format or adapt, remix, transform, and build upon the material for any purpose, even commercially.

Introduction

From 1998 to 2009, tumor necrosis factor-alpha (TNF- α) antagonists including infliximab, etanercept, adalimumab, certolizumab, and golimumab were approved for treating several inflammatory diseases. Although drug-induced liver injury (DILI) was not reported during phase III clinical trials, post-marketing surveillance showed DILI by all TNF- α antagonists (1). It seems that among older and more widely used TNF- α antagonists (infliximab, Etanercept, and adalimumab), the most DILI cases have been reported by infliximab although not more commonly used than Etanercept and adalimumab (1-4). Some reported cases proposed no cross hepatotoxicity between infliximab and etanercept (5,6) or between adalimumab and etanercept (7) showing that a "class effect" is not universal among anti-TNF- α agents (1).

While all types of liver damage including hepatocellular and cholestatic types have been reported, the most reported types of hepatotoxicity by TNF- α antagonists is hepatocellular injury with features of autoimmunity as shown by histopathology of liver biopsy and serologic findings of high titers of anti-nuclear antibodies (ANA), anti-smooth muscle antibodies (ASMA), and/or elevated immunoglobulin G (1,8). The median times from initiation of anti-TNF- α agents and DILI development differ from 14

to 18 weeks with time ranges of DILI happening from 2 to 104 weeks in different reviews of reported cases (2-4).

Although several cases of Etanercept-induced hepatotoxicity have been reported, to our knowledge, a case of Etanercept-induced acute hepatic failure which necessitates liver transplantation, has not been reported in the literature.

Case Report

Our patient was a 32-year-old man, known case of ankylosing spondylitis with positive HLA-B27, diagnosed on September, 2016. He initially was treated with corticosteroids, sulfasalazine, and indomethacin, for several months. Due to the incomplete therapeutic response, after complete routine laboratory tests, latent tuberculosis and viral infections work-up, his regimen was changed to anti-TNF- α (Etanercept) with a dosage of 25 mg weekly and after that increased to 50 mg per week from September 15th, 2016. After a month his symptoms were significantly improved. Five months later, on February 12th, 2017, the patient presented with raised liver transaminases (AST:300 IU/L and ALT:100 IU/L) and poly gammopathy, which were detected in his routine

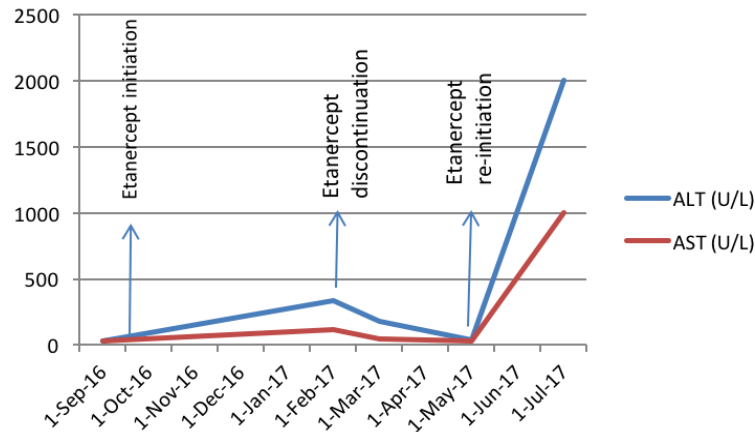


Fig. 1. Patient's serum transaminases level during Etanercept treatment

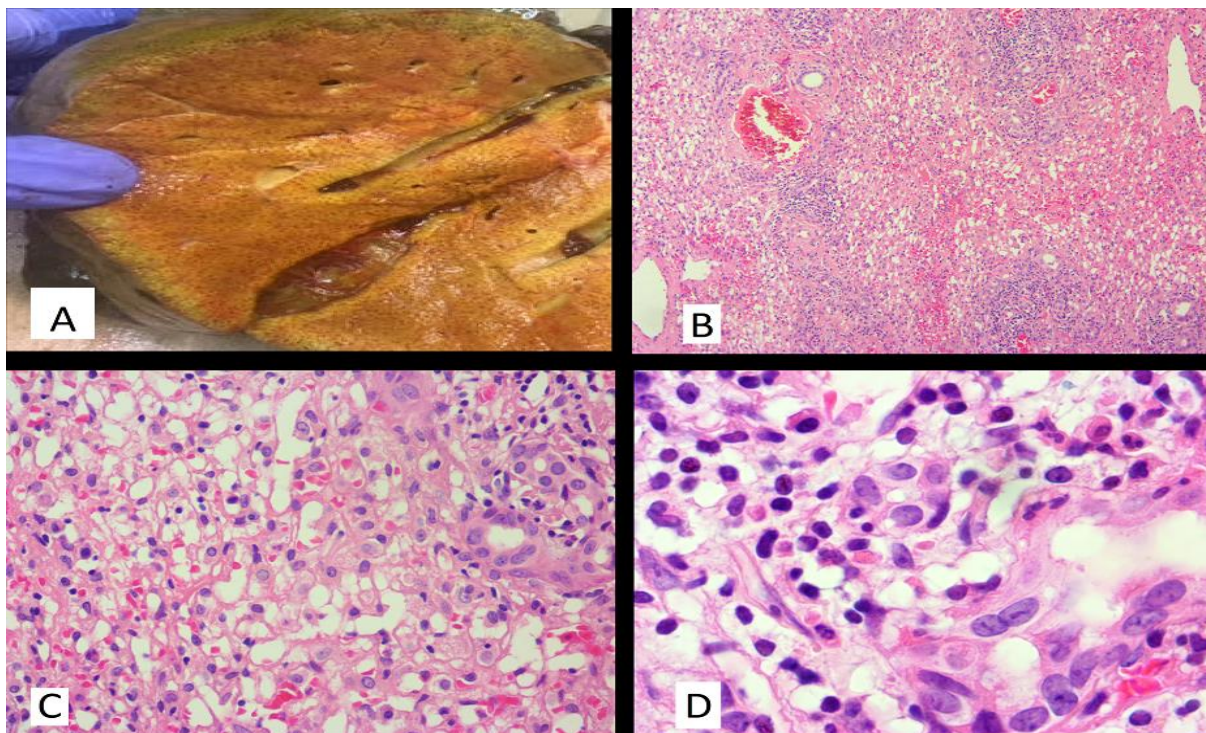


Fig 2. A. Mottled cut surface of the liver in gross examination. B. Confluent necrosis in the liver parenchyma (x100). C. Mild cholangiolar reaction as well as infiltration of mixed population inflammatory cells is noted in portal tracts (x400). D. Prominent eosinophilic infiltration in the portal tracts (x1000).

follow-up laboratory tests without any obvious clinical symptoms. Abdominal and pelvic ultrasounds had normal findings. He also used prednisolone, silymarin, alendronate and calcium, and vitamin D supplements. In this setting, etanercept was discontinued for the patient. After 2 months, his liver enzymes returned to the normal level, so the anti-TNF- α regimen started again with the same dosage as the beginning on May 13th, 2017. After 2 months in July 2017, the patient was admitted to the emergency department of Tehran Imam-Khomeini Hospital Complex with icterus, fatigue, and weakness. He was completely alert initially. His laboratory tests showed AST: 2579 IU/L, ALT:2854 IU/L, ALP:648 IU/L, INR:5.9, Bilirubin total: 15.4 mg/dl and direct: 10.5 mg/dl.

Figure 1 shows his serum transaminases during etanercept treatment and discontinuation phases. His serologic markers had negative results for hepatitis B, hepatitis C, human immunodeficiency viruses or cytomegalovirus infections. He was not a smoker and denied alcohol use. The patient weight was 76 Kg (BMI=25.39kg/m²). In the next two weeks, his liver enzymes did not change significantly, also his level of consciousness dramatically decreased and after 15 days on July 27th, 2017, a grade II liver encephalopathy occurred. Therefore, he received emergent liver transplantation from a deceased donor with the clinical impression of fulminant hepatitis.

Etanercept induced DILI was highly probable (score 10) according to Council for International Organization Medical

Sciences/Roussel Uclaf Causality Assessment Method (CIOMS/RUCAM) scale (9) and certainly according to the World Health Organization-Uppsala Monitoring Center (WHO-UMC) causality assessment (10) in this patient.

Pathologic Findings:

The explanted liver of the patient was received in the pathology department. The specimen was composed of a total liver with an attached gallbladder, weighing 950g and measuring 20 x14 x 8 cm. Cut sections through the liver parenchyma showed a mottled surface with no obvious prominent nodule or mass lesion (Figure 2A). Tissue samples were obtained from all 8 liver segments. The microscopic examination of prepared sections showed extensive confluent necrosis in all liver segments. In portal tracts, prominent infiltration of a mixed population of inflammatory cells composed of lymphoplasmic cells, eosinophils and neutrophils were noticed. Also, a moderate to severe cholangiolar reaction was prominent (Figure 2B-D). No significant fibrosis was identified on trichrome staining.

Discussion

Hepatotoxicity has been reported by all TNF- α antagonists including etanercept (1-4). The most common type of etanercept-induced DILI is the hepatocellular pattern of injury, sometimes with features of autoimmune hepatitis (1,11). Increase in serum ALT is usually mild (11). A case of granulomatous hepatitis has been reported with etanercept in a patient with rheumatoid arthritis (12). In these cases, liver enzymes returned to normal range 2-11 weeks after etanercept discontinuation in different cases (12,13). In some cases, etanercept treatment reinitiated with lower doses (12-15) without an increase in liver enzymes and few cases were treated with changing to another TNF- α antagonist (16).

Van Denderen *et al.* reported a possible or probable etanercept-induced liver dysfunction in 9 of 105 (approximately 9%) patients with ankylosing spondylitis (17) that is higher than the incidence of 1-1.1% reported in patients with rheumatoid arthritis (18). In all but one case reported by Van Denderen *et al.* liver enzymes increased 1 to 3 months after etanercept initiation. In one patient hepatotoxicity happened after 6 months. No differences in age, sex or alcohol consumption were reported between etanercept treated patients with and without hepatotoxicity. Patients with a higher body mass index had a higher risk of etanercept induced hepatotoxicity ($P<0.001$) (17). Some authors suggested the possibility of more frequency of anti-TNF alpha-induced autoimmune hepatitis in patients with ankylosing spondylitis compared to patients with rheumatoid arthritis because of less immunosuppression therapy in these patients (19). Our patient had ankylosing spondylitis as well but did not have a high body mass index. He showed hepatocellular liver injury based on the patterns of changes in serum enzymes and histopathological study of the explanted liver. He also had some features of autoimmunity such as positive serum anti-nuclear antibody (ANA) and

polygammopathy. He underwent a liver transplantation because of life-threatening liver failure and hepatic encephalopathy.

Conclusion

Although a severe hepatic failure, liver transplantation, and death have been reported by infliximab, to our knowledge, the presented case is the first case of etanercept-induced severe hepatic damage that indicates a liver transplantation. In conclusion, a careful monitor is necessary for those patients who are candidate for etanercept treatment.

Acknowledgements

The authors would like to thank the Tehran Imam Khomeini hospital complex Liver Transplantation Research Center as well as the Cancer Institute staff for all their helps and supports for gathering the information needed for this manuscript.

Conflict of Interest

The authors confirm that there are no known conflicts of interest associated with this publication, and there has been no significant financial support for this work that could have influenced its outcome.

References

1. French JB, Bonacini M, Ghabril M, Foureau D, Bonkovsky HL. Hepatotoxicity associated with the use of anti-TNF- α agents. *Drug Safety*. 2016;39(3):199-208. [DOI:10.1007/s40264-015-0366-9] [PMID] [PMCID]
2. Björnsson ES, Gunnarsson BI, Gröndal G, Jonasson JG, Einarsdóttir R, Ludvíksson BR, et al. Risk of drug-induced liver injury from tumor necrosis factor antagonists. *Clin Gastroenterol Hepatol*. 2015;13(3):602-8. [DOI:10.1016/j.cgh.2014.07.062] [PMID]
3. Shelton E, Chaudrey K, Sauk J, Khalili H, Masia R, Nguyen D, et al. New onset idiosyncratic liver enzyme elevations with biological therapy in inflammatory bowel disease. *Aliment Pharmacol Therapeut*. 2015;41(10):972-9. [DOI:10.1111/apt.13159] [PMID]
4. Ghabril M, Bonkovsky HL, Kum C, Davern T, Hayashi PH, Kleiner DE, et al. Liver injury from tumor necrosis factor- α antagonists: analysis of thirty-four cases. *Clin Gastroenterol Hepatol*. 2013;11(5):558-64. e3. [DOI:10.1016/j.cgh.2012.12.025] [PMID] [PMCID]
5. Aparicio AMG, Rey JR, Sanz AH, Alvarez JS. Successful treatment with etanercept in a patient with hepatotoxicity closely related to infliximab. *Clin Rheumatol*. 2007;26(5):811-3. [DOI:10.1007/s10067-006-0253-y] [PMID]
6. Thiéfin G, Morelet A, Heurgué A, Diebold M-D, Eschard J-P. Infliximab-induced hepatitis: absence of cross-toxicity with etanercept. *Joint Bone Spine*. 2008;75(6):737-9. [DOI:10.1016/j.jbspin.2007.12.009] [PMID]
7. Massarotti M, Marasini B. Successful treatment with etanercept of a patient with psoriatic arthritis after adalimumab-related hepatotoxicity. *Int J Immunopathol Pharmacol*. 2009;22(2):547-9. [DOI:10.1177/039463200902200234] [PMID]

8. De Rycke L, Baeten D, Kruithof E, Van den Bosch F, Veys E, De Keyser F. The effect of TNF α blockade on the antinuclear antibody profile in patients with chronic arthritis: biological and clinical implications. *Lupus*. 2005;14(12):931-7. [DOI:10.1191/0961203305lu2240tr] [PMID]
9. Danan G, Benichou C. Causality assessment of adverse reactions to drugs-I. A novel method based on the conclusions of international consensus meetings: application to drug-induced liver injuries. *J Clin Epidemiol*. 1993;46(11):1323-30. [DOI:10.1016/0895-4356(93)90101-6]
10. Organization WH. The use of the WHO-UMC system for standardized case causality assessment. Uppsala: The Uppsala Monitoring Centre. 2005:2-7.
11. Van Lümig P, Driessen R, Roelofs-Thijssen M, Boezeman J, Van de Kerkhof P, De Jong E. Relevance of laboratory investigations in monitoring patients with psoriasis on etanercept or adalimumab. *Br J Dermatol*. 2011;165(2):375-82. [DOI:10.1111/j.1365-2133.2011.10329.x] [PMID]
12. Farah M, Al Rashidi A, Owen DA, Yoshida EM, Reid GD. Granulomatous hepatitis associated with etanercept therapy. *J Rheumatol*. 2008;35(2):349-51.
13. Leak AM, Rincon-Aznar B. Hepatotoxicity associated with etanercept in psoriatic arthritis. *J Rheumatol*. 2008;35(11):2286-8. [DOI:10.3899/jrheum.080521] [PMID]
14. Li Z, Xiao S, Ren J, Zhang Y, Tu C, Ji F. Hepatotoxicity due to etanercept abated after dose reduction in a patient with pustular psoriasis and without compromised efficacy. *Revista espanola de enfermedades digestivas: organo oficial de la Sociedad Espanola de Patologia Digestiva*. 2014;106(7):492-3.
15. Iwamoto M, Minota S. Successful treatment with very low-dose etanercept in a patient with etanercept-induced liver dysfunction. *Rheumatol Int*. 2011;31(4):561-2. [DOI:10.1007/s00296-010-1456-8] [PMID]
16. Titos AJ, Hallal H, Robles M, Andrade RJ. Recurrent hepatotoxicity associated with etanercept and adalimumab but not with infliximab in a patient with rheumatoid arthritis. *Revista española de enfermedades digestivas: organo oficial de la Sociedad Española de Patología Digestiva*. 2012;104(5):282. [DOI:10.4321/S1130-01082012000500014] [PMID]
17. Van Denderen J, Blom G, Van der Horst-Bruinsma I, Dijkmans B, Nurmohamed M. Elevated liver enzymes in patients with ankylosing spondylitis treated with etanercept. *Clin Rheumatol*. 2012;31(12):1677-82. [DOI:10.1007/s10067-012-2072-7] [PMID]
18. Sokolove J, Strand V, Greenberg JD, Curtis JR, Kavanaugh A, Kremer JM, et al. Risk of elevated liver enzymes associated with TNF inhibitor utilisation in patients with rheumatoid arthritis. *Ann Rheumat Dis*. 2010;69(9):1612-7. [DOI:10.1136/ard.2009.112136] [PMID]
19. Ozorio G, McGarity B, Bak H, Jordan AS, Lau H, Marshall C. Autoimmune hepatitis following infliximab therapy for ankylosing spondylitis. *The Medical Journal of Australia*. 2007;187(9):524-6. [DOI:10.5694/j.1326-5377.2007.tb01396.x] [PMID]

How to Cite This Article

Sadeghian, D., Azmoudeh-Ardalan, F., Dashti-Khavidaki, S., Fakhari, N. Orthotopic Liver Transplantation for Etanercept-Induced Acute Hepatic Failure; a case report. *Iranian Journal of Pathology*, 2020; 15(4): 338-341. doi: 10.30699/ijp.2020.117000.2269