

Solitary Fibrous Tumor of the Prostate: A Diagnostic Challenge: A Case ReportNilay Nishith^{1*}, Monika Gupta¹, Nidhi Kaushik¹, Rajeev Sen¹*1. Department of Pathology, Pt. B. D. Sharma, PGIMS, Rohtak, Haryana, India*

Scan to discover online

**Main Subjects:**
Uropathology

Received 04 Mar 2019;

Accepted 26 Nov 2019;

Published Online 26 Dec 2019;

10.30699/IJP.2019.104669.2069

PMCID: PMC6995682

PMID: [32095149](https://pubmed.ncbi.nlm.nih.gov/32095149/)**ABSTRACT**

Solitary fibrous tumor (SFT) of prostate is an unusual type of mesenchymal neoplasm that can elicit a benign or malignant phenotype. It represents a diagnostic challenge as it can simulate poorly differentiated adenocarcinoma and various mesenchymal neoplasms of prostate. We report a case of prostate SFT in a 54-year-old patient, which was clinically misdiagnosed as nodular hyperplasia of prostate with cystitis. However, on follow-up, he was not relieved by the designated treatment. Furthermore, he complained of exacerbation of symptoms and consequently, had to undergo open prostatectomy. Based on histopathological and immunohistochemical (IHC) assessment, a diagnosis of SFT of the prostate was rendered. Additionally, we have discussed the histological mimics of SFT and the diagnostic and prognostic importance of IHC while evaluating such lesions.

KEYWORDS: Diagnosis, Immunohistochemistry, Prognosis, Prostate, Solitary fibrous tumor

Corresponding Information:

Nilay Nishith, Department of Pathology, Pt. B. D. Sharma, PGIMS, Rohtak, Haryana, India
Email: drnilaynishith@gmail.com

Copyright © 2020. This is an open-access article distributed under the terms of the Creative Commons Attribution- 4.0 International License which permits Share, copy and redistribution of the material in any medium or format or adapt, remix, transform, and build upon the material for any purpose, even commercially.

Introduction

Solitary fibrous tumor (SFT) is an uncommon myofibroblastic tumor, generally affecting the pleura (1). Interestingly, the number of extrapleural SFT has significantly increased in the last decade. Nonetheless, the solitary fibrous tumor of the prostate remains exceptionally rare, with merely 30 cases described in literature worldwide (2). Further, its diagnosis becomes challenging as it can simulate poorly differentiated adenocarcinoma and various mesenchymal neoplasms of the prostate (3). Here we report an additional case of prostate SFT in a 54-year-old patient, which was clinically misdiagnosed as nodular hyperplasia of prostate with cystitis.

Case Report

A 54-year-old diabetic male patient referred to surgical outpatient department with complaints of urinary urgency and increased frequency. Serum prostate-specific antigen (PSA) level was mildly elevated, while other haematological and biochemical parameters were within normal limits. Digital rectal examination and pelvic ultrasound revealed gross prostatic enlargement, measuring approximately 195.6 gm by weight with median lobe projecting into the base of the bladder. Based on clinico-radiological findings, he was first diagnosed as benign prostatic hyperplasia with cystitis and was treated with tablet Tamsulosin and antibiotics for almost one month. However, on follow-up, no improvement of symptoms was

observed. Further, the patient complained of exacerbation of symptoms and supplementary radiological investigations stated progressive increase in prostate size. Therefore, in suspicion of malignancy, open prostatectomy was undertaken and a large prostatic mass was excised, which was sent for histopathological analysis.

On gross examination, the specimen was composed of three nodular masses, each measuring 5x4x3 cm, 4x4x3 cm, and 4x3x2 cm respectively. External surface was unremarkable. Cut section showed solid grey-white whorled areas with no necrosis or haemorrhage ([Figure 1](#)). Microscopic examination reveals a benign neoplasm composed of unencapsulated and circumscribed nodules; comprising of haphazardly arranged ovoid and spindle cells with indistinct cell borders and relatively uniform nuclei, embedded in a fibrocollagenous stroma with peripherally compressed benign prostatic glands ([Figure 2](#)). Multiple hemangiopericytoma-like/staghorn blood vessels ([Figure 3](#)) were interspersed within the lesion, while neither necrosis nor increased mitotic activity was noted. Immunostaining showed strong positivity for vimentin, CD34, CD99 and BCL-2 ([Figure 4](#)) and immuno-negativity for pan-cytokeratin, epithelial membrane antigen (EMA), actin, desmin, myogenin, progesterone receptor (PR) and CD117 among the neoplastic cells. In accordance with the histomorphological and immunohistochemical (IHC)

findings, diagnosis of a solitary fibrous tumor of the prostate was rendered. Currently, the patient is on regular follow-up and asymptomatic.

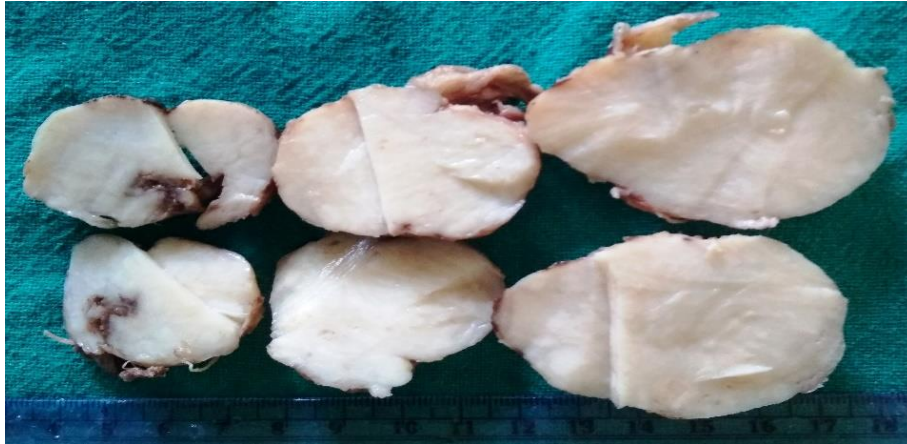

Fig. 1. Specimen comprises of three nodular masses. Gross examination of the cut section shows solid grey-white whorled areas.

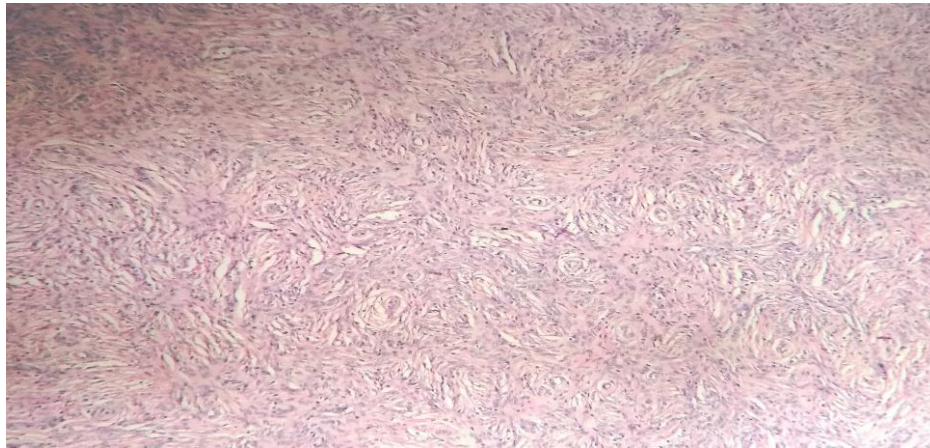


Fig. 2. Histological section shows tumor composed of haphazardly arranged ovoid and spindle cells with indistinct cell borders and relatively uniform nuclei embedded in a fibrocollagenous stroma (H&E; X100).

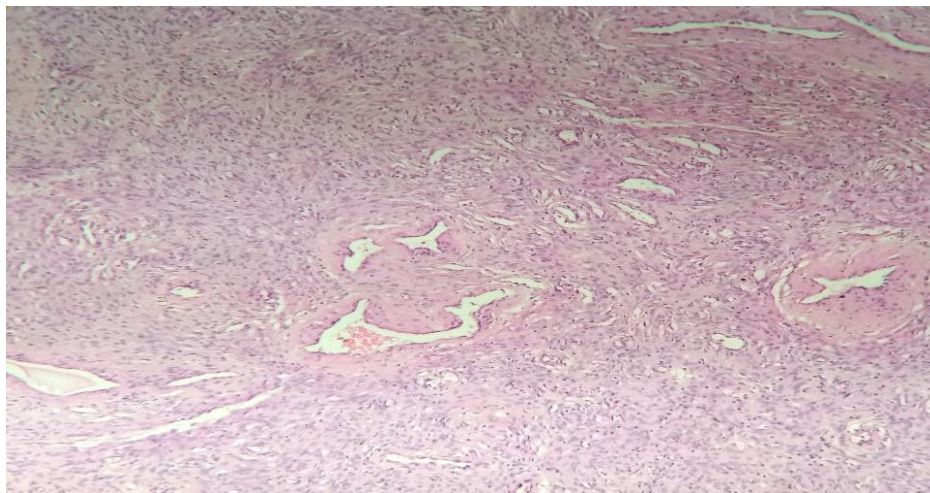


Fig. 3. Histological section shows multiple hemangiopericytoma-like blood vessels interspersed within the tumor (H&E; X100).

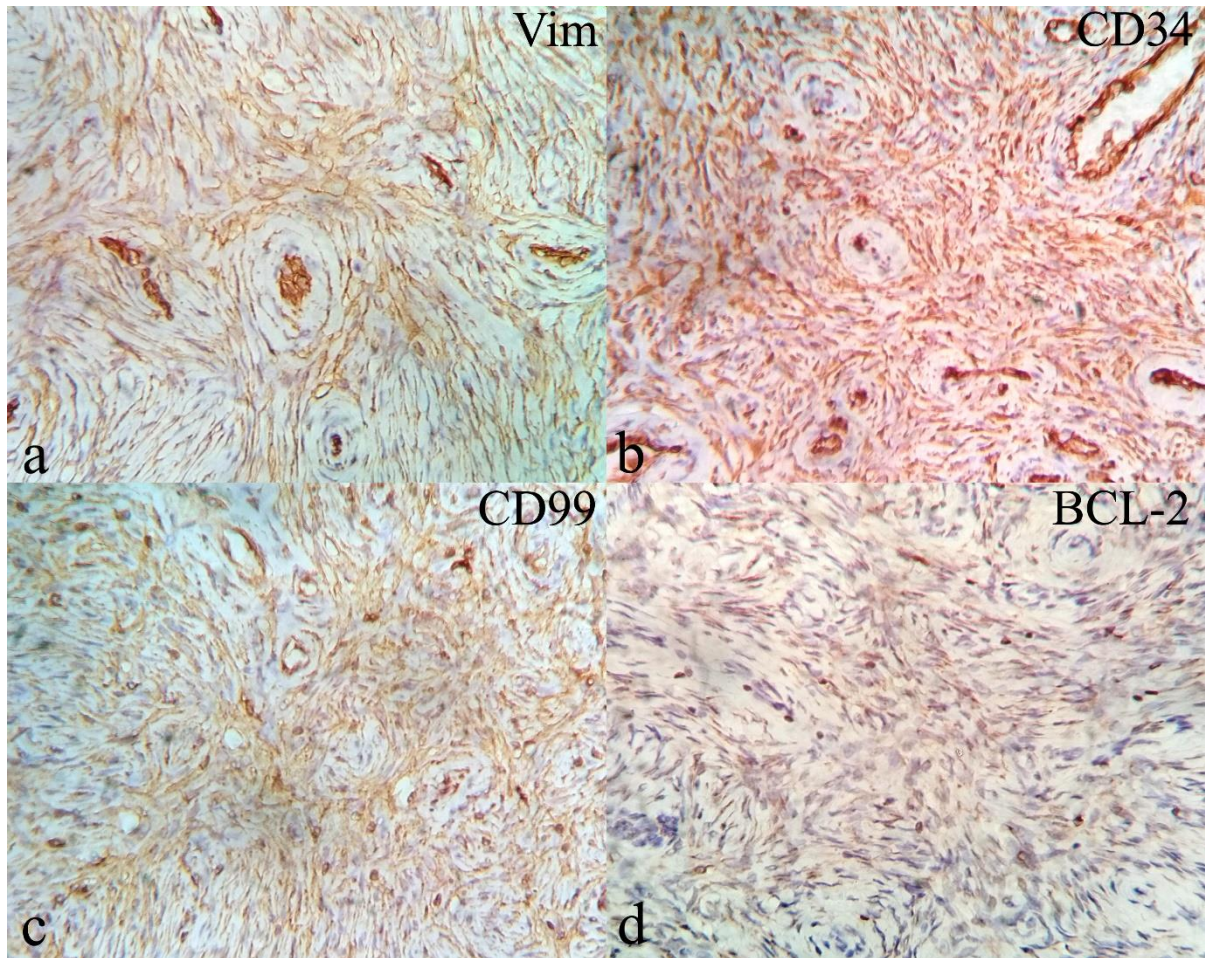


Fig. 4: Tumor cells demonstrating immuno-positivity for (a) Vimentin (IHC; X400), (b) CD34 (IHC; X400), (c) CD99 (IHC; X400), and (d) BCL-2 (IHC; X400).

Discussion

Mesenchymal neoplasms of prostate are uncommon and quite often pose a diagnostic difficulty for the pathologists, because of their overlapping histomorphological and IHC characteristics. Amongst others, SFT is considered as a least common mesenchymal neoplasm of the prostate, accounting for merely 30 cases globally (2).

SFT is usually seen among middle-aged and elderly individuals and frequently manifest as slow-growing mass. The tumor tends to remain asymptomatic initially; however, progressive increase in size leads to obstructive symptoms such as increased frequency, urinary retention, urgency along with dysuria and hematuria. Serum PSA level is within normal limit and few patients also present with hypoglycemia as SFTs have been documented to produce insulin-like growth factors (1). The tumor dimensions are quite variable; size may vary from 5cm to 18cm (4,5). Macroscopic examination reveals a well-circumscribed, nodular grey-white mass. Cut section may show a whorling appearance. Histomorphologically, the neoplasm is composed of bland fibroblast-like cells admixed with collagen, often arranged in 'patternless' pattern with interspersed hemangiopericytomatous or staghorn blood vessels and mitotic rate is $<4/10$ hpf. IHC profile of SFTs include immuno-positivity for vimentin,

CD99, CD34 and BCL-2 whereas pan-cytokeratin, actin, desmin, myogenin, PR, PSA, S-100 and CD117 are negative (1,4).

In the present case, initial clinical examination and laboratory work-up favoured the diagnosis of nodular hyperplasia of prostate with cystitis. However, the patient was not relieved by the designated treatment and finally, had to undergo open prostatectomy; in suspicion of malignancy. Based on histopathological and IHC evaluation of the specimen obtained post-surgery, a diagnosis of SFT of the prostate was rendered. A review article authored by McKenney documents that benign sub-epithelial connective tissue or benign prostatic hyperplasia can simulate SFT, in superficial biopsies obtained by the transurethral method (6). Additionally, the differential diagnosis of prostatic SFT in resected specimen encompasses a wide range of spindle cell lesions namely stromal tumor of uncertain malignant potential (STUMP), prostatic stromal sarcoma (PSS), smooth muscle tumors such as leiomyoma and leiomyosarcoma, fibrosarcoma, inflammatory myofibroblastic tumor, gastrointestinal stromal tumor (GIST), sarcomatoid carcinoma, rhabdomyosarcoma and schwannoma. As opposed to SFT, STUMP and PSS are PR positive. GIST is usually CD117 positive and schwannomas are

immunoreactive for S-100. Rest of the spindle cell neoplasms, unlike SFT, are negative for CD34 (4,6). Osamu *et al.* reported poorly differentiated adenocarcinoma mimicking as SFT, as the initial prostatic biopsy was pan-cytokeratin positive. Although, the histomorphological and IHC assessment of the prostatectomy specimen, revised the former diagnosis to solitary fibrous tumor (3). Thus, IHC plays a crucial role in the diagnosis of SFT. The recent literature describes nuclear STAT6 and cytoplasmic ALDH1 (Aldehyde Dehydrogenase 1) immunohistochemical expression to be specific for asserting SFT and also distinguishing from its histological mimics, particularly STUMP and PSS (7).

Extrapleural SFTs, particularly of the prostate pose a diagnostic challenge for the pathologists as well as clinicians. Its histomorphology often overlaps with various mesenchymal neoplasms, which translates to poor correlation between histologic features and clinical outcome. Furthermore, prostatic SFT has unpredictable clinical behaviour and might even undergo malignant transformation. Histopathological characteristics of malignant SFT include high cellularity with cytological atypia, presence of necrosis and increased mitotic activity (>4/10hpf) or atypical mitosis (8). In this regard, p53 IHC staining can aid in predicting the malignant potential tumors. Yokoi *et al.* have illustrated strong p53 immunoreactivity in malignant SFT while the benign ones were negative. Thus, p53 expression confers a poor prognosis (9).

Owing to the possible aggressive behaviour and likelihood of recurrence, prostatic SFTs should be treated by complete excision with negative margins and careful follow-up. Nerve-sparing radical prostatectomy should be opted in young men, for preserving sexual and urinary functions. Cystectomy must be reserved for cases with bladder involvement. In addition, radiotherapy and chemotherapy have proved futile in managing SFT of the prostate (10).

Conclusion

Given the scarcity of data, we report and add an additional case of prostatic SFT in a 54-year-old patient, whose initial diagnosis was benign hyperplasia of prostate. Additionally, SFT of the prostate can prove to be a diagnostic challenge for the pathologists as well as clinician, because it mimics an array of mesenchymal neoplasms and elicits an unpredictable clinical behaviour. Therefore, we emphasize on meticulous clinico-histopathological and immunohistochemical evaluation of the neoplasm along with

vigilant post-operative follow-up to circumvent tumor relapse or malignant transformation.

Acknowledgements

The authors are grateful to the teaching staff and laboratory personnel of the Department of Pathology, PGIMS, Rohtak for their valuable co-operation.

Conflict of Interest

The authors declared that there is no conflict of interest regarding the publication of this article.

References

1. Fletcher CDM, Bridge JA, Lee JC. Extrapleural solitary fibrous tumour. In: Fletcher CDM, editor. WHO classification of tumours of soft tissue and bone. 4th ed. Lyon: the International Agency for Research on Cancer press; 2013. p. 80-2.
2. Talvitie H, Aström K, Larsson O, Ahlén J, Bergh A, Egevad L. Solitary fibrous tumor of the prostate: a report of two cases. *Pathol Int.* 2011 Sep;61(9):536-8. [DOI:10.1111/j.1440-1827.2011.02696.x] [PMID]
3. Osamu S, Murasawa H, Imai A, Hatakeyama S, Yoneyama T, Hashimoto, et al. Solitary Fibrous Tumor of the Prostate Which Was Initially Misdiagnosed as Prostate Cancer. *Case Rep Urol.* 2017;Feb 26. [DOI:10.1155/2017/3594914] [PMID] [PMCID]
4. Hansel DE, Herawi M, Montgomery E, Epstein JI. Spindle cell lesions of the adult prostate. *Mod Pathol.* 2007 Jan;20(1):148-58. [DOI:10.1038/modpathol.3800676] [PMID]
5. Dhameja N, Santosh D, Dwivedi US. Solitary Fibrous Tumour of the Prostate with Ossification: A rare Case Report. *Annals of Pathology and Laboratory Medicine.* 2015 Jul 21;2(3):C146-150.
6. McKenney JK. Mesenchymal tumors of the prostate. *Mod Pathol.* 2018 Jan;31(S1):S133-42. [DOI:10.1038/modpathol.2017.155] [PMID]
7. Guner G, Bishop JA, Bezerra SM, Taheri D, Zahavi DJ, Mendoza Rodriguez MA, et al. The utility of STAT6 and ALDH1 expression in the differential diagnosis of solitary fibrous tumor versus prostate-specific stromal neoplasms. *Hum Pathol.* 2016 Aug;54:184-8. [DOI:10.1016/j.humpath.2016.03.011] [PMID]
8. Yokoi T, Tsuzuki T, Yatabe Y, Suzuki M, Kurumaya H, Koshikawa T, et al. Solitary fibrous tumour: significance of p53 and CD34 immunoreactivity in its malignant transformation. *Histopathology.* 1998 May;32(5):423-32. [DOI:10.1046/j.1365-2559.1998.00412.x] [PMID]
9. Park MS, Araujo DM. New insights into the hemangiopericytoma/solitary fibrous tumor spectrum of tumors. *Curr Opin Oncol.* 2009 Jul;21(4):327-31. [DOI:10.1097/CCO.0b013e32832c9532] [PMID]

How to Cite This Article

Nishith, N., Gupta, M., Kaushik, N., Sen, R. Solitary Fibrous Tumor of the Prostate: A Diagnostic Challenge: A Case Report. *Iranian Journal of Pathology*, 2020; 15(1): 41-44. doi: 10.30699/ijp.2019.104669.2069