

## Estrogen Receptor Expression in Glial Tumors of Iranian Patients: A Single Center Experience

Masoumeh Shafiee<sup>1</sup>, Ahmad Mafi<sup>2</sup> , Yalda Nilipour<sup>3</sup> , Ainaz Sourati<sup>1</sup>, Pegah Sassanpour<sup>1</sup>, Morteza Tabatabaefar<sup>4\*</sup>

1. Shohaday-e Tajrish Hospital, Shahid Beheshti University of Medical Sciences, Tehran, Iran
2. Imam Hussein Hospital, Shahid Beheshti University of Medical Sciences, Tehran, Iran
3. Pediatric Pathology Research Center, Research Institute for Children Health, Mofid and Shohaday-e Tajrish Hospital, Shahid Beheshti University of Medical Sciences, Tehran, Iran
4. Imam Hussein Hospital, Shahid Beheshti University of Medical Sciences, Tehran, Iran

### KEYWORDS

Gliomas,  
Estrogen receptor alpha,  
Estrogen receptor beta,  
Brain tumor grade

Scan to discover online



Main Subjects:  
Neuropathology

Received 17 Oct 2018;

Accepted 03 Sep 2019;

Published Online 26 Dec 2019;



10.30699/IJP.2019.95525.1946

PMCID: PMC6995676

PMID: [32095143](https://pubmed.ncbi.nlm.nih.gov/32095143/)

### ABSTRACT

**Background & Objective:** Gliomas are the most common type of primary intracranial tumors in adults. The expression of estrogen receptors varies in different grades of glial tumors, and some studies have suggested that this expression might have a prognostic value. It seems that estrogen receptor expression negatively correlates with the histological grade of gliomas. In the present study, we aimed to determine the expression of estrogen receptor in different glial tumors in Iranian patients and to find a possible correlation between its expression and the grade of glial tumors

**Methods:** The brain tumors pathology reports from 2014 to 2017 in the Pathology Department of Shohaday-e Tajrish Hospital in Tehran, Iran were evaluated and 104 different gliomas: 79 cases of astrocytoma and 25 cases of oligodendroglioma were selected. All the samples were re-evaluated by a neuropathologist in order to accurately determine the tumor grade. The immunohistochemistry was carried out to detect the expression of estrogen receptor alpha and beta on brain tumors.

**Results:** None of the samples expressed estrogen receptor alpha. In the case of estrogen receptor beta (ER $\beta$ ), all samples showed various degrees of positivity: 9% weak, 40% moderate, and 51% strong expressions. The level of ER $\beta$  expression was found to be conversely correlated with tumor grade.

**Conclusion:** Our study demonstrated that ER $\beta$  is expressed in the majority (if not all) of the glial tumors and its expression was conversely related to the tumor grade. Because of well-tolerability and acceptable adverse effects, ER agonists might be considered as therapeutic agents for the patients with glial tumors.

### Corresponding Information:

Morteza Tabatabaefar, Associate Professor of Radiation Oncology, Imam Hussein Hospital, Shahid Beheshti University of Medical Sciences, Tehran, Iran Email: [tabatabaefar@hotmail.com](mailto:tabatabaefar@hotmail.com)

Copyright © 2020. This is an open-access article distributed under the terms of the Creative Commons Attribution- 4.0 International License which permits Share, copy and redistribution of the material in any medium or format or adapt, remix, transform, and build upon the material for any purpose, even commercially.

### Introduction

Gliomas are the most common type of primary intracranial tumors in adults. They originate from supportive cells of the brain, called glial cells (1,2). While some hereditary disorders such as Li-Fraumeni syndrome, tuberous sclerosis, and neurofibromatosis are known to increase the risk of their development, the exact cause of gliomas is unknown (3). Based on the World Health Organization (WHO) classification, gliomas are categorized into four main groups (4): Grade I: tumors with a low proliferative potential and high probability of cure with surgical resection alone, Grade II: tumors that are infiltrative in nature and despite the low-level proliferative activity are associated with a high recurrence rate, Grade III: high-grade tumors with histological evidence of malignancy which include

nuclear atypia and mitotic activity that often recur as higher-grade tumors, and Grade IV: aggressive and malignant tumors that are mitotically active. They often cause necrosis and are typically associated with rapid progression despite multimodality treatments.

While low-grade tumors generally have a favorable outcome, high-grade tumors (especially grade IV) usually have a dismal prognosis despite using multimodality treatments including surgery, radiotherapy, and chemotherapy (3,5). Estrogen hormone, which regulates many functions in the human body, mediates its effects by two main estrogen receptors that are distributed throughout the body including glial cells: estrogen receptor alpha (ER $\alpha$ ) and estrogen receptor beta (ER $\beta$ ).

ER $\alpha$  and ER $\beta$  bind to the different ligands and studies have shown that ER $\alpha$  can enhance the proliferation of cancer cells, while ER $\beta$  has a potential role as a tumor suppressor. Several studies have demonstrated that high-grade gliomas are frequently associated with loss of ER $\beta$  expression, which results in a poor clinical outcome (6,7).

Observation of tumor regression using anti-estrogen medications in the patients with meningioma has made this hypothesis that these drugs might have a similar effect in other types of brain tumors. In-vitro effectiveness of hormonal treatments has been reported in the literature (8-11). The expression of estrogen receptors varies in different grades of glial tumors, and some studies have suggested that this expression might have a prognostic value.

While generally low-grade astrocytomas highly express estrogen receptors, their expression in high-grade gliomas is quite low and it seems that estrogen receptor (especially ER $\beta$ ) expression negatively correlates with the histological malignancy of gliomas (12).

In the current study, we aimed to evaluate the expression of estrogen receptors in Iranian patients with glial tumors and to find a possible correlation between its expression and the grade of glial tumors.

### Materials and Methods

In this cross-sectional study, we evaluated the expression of two variants of ER receptors; estrogen receptor alpha (ER $\alpha$ ) and estrogen receptor beta (ER $\beta$ ) on glial tumors.

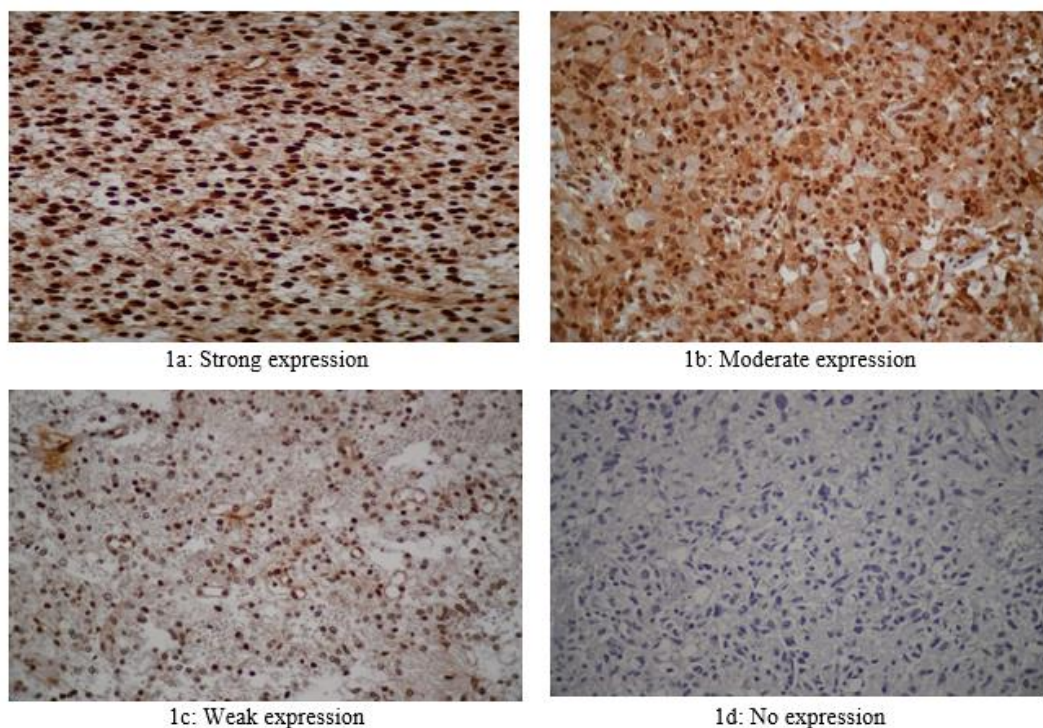
All paraffin-embedded blocks of reported glial tumors from 2014 to 2017 were obtained from the Department of Pathology in Shohaday-e Tajrish Hospital in Tehran, Iran.

A total number of 104 gliomas (Astrocytomas NOS, grade I to III, glioblastoma NOS, and oligodendrogliomas NOS grade II and III) that contained adequate amounts of tumoral tissue for complimentary pathological examinations were selected.

At first, all the samples were re-evaluated by a neuropathologist in order to re-confirm the initial diagnosis and to accurately determine the tumor grades based on the 2016 WHO classification of tumors of central nervous system. Tissue samples were analyzed by immunohistochemistry for determination of the estrogen receptor expression status by EnVision System kit from Dako (Denmark). Thin cut sections (4  $\mu$ m) were prepared, de-waxed in xylene and re-hydrated by alcohols. All the samples were buffered and microwaved twice. After 10 minutes of incubation with 0.03% H<sub>2</sub>O<sub>2</sub>, they were incubated for 1 hour by primary antibody (ER alpha and beta). After washing with PBS solution cut sections were incubated by EnVision kit (DAKO) for 1 hour. After washing hematoxylin Harris staining was used for 2 minutes for background staining. Breast cancer tissue was used as control for the ER expression. This pathologic evaluation was performed by a blinded pathologist who was unaware of the other clinical data.

The results of IHC assessment were reported in four levels (1) (Figure 1):

Negative expression (less than 10% of the cells show nuclear staining), weak expression (weak nuclear staining intensity or 10-50% of the cells show nuclear staining), moderate expression (moderate nuclear staining intensity and more than 50% of the cells show nuclear staining), strong expression (strong nuclear intensity and more than 50% of the cells show nuclear staining).



**Fig. 1.** Different patterns of estrogen receptor expression

The SPSS 21 (SPSS Inc., Chicago, Illinois, USA) was used for the statistical analysis. For the comparison and description of variables, T-test and  $\chi^2$  test were used, and P-value<0.05 was considered statistically significant.

This study was approved by the Ethical Committee of Shahid Beheshti University of Medical Sciences (ethical code: IR.SBMU.MSP.REC.1395.6).

**Results**

In 104 cases, 64 (61.5%) were men and 40 (38.5%) were women. The median age at the diagnosis was 46.7± 15.8 years (range 8 to 81 years old). The majority of the samples (80 cases, 76%) were obtained by open surgery and 20 cases (24%) by stereotactic biopsy. From the samples, 79 cases (76%) were astrocytoma and 25 cases (24%) were oligodendroglioma.

All of the samples were negative for ER $\alpha$  but positive for ER $\beta$  in different degrees: 10 (9%) samples showed weak expression, 41 (40%) moderate expression and 53 (51%) strong expression (Figure 2, Table 1).

Based on our results, increase in the median age was associated with higher-grade tumors (P<0.0001). Besides, the patients with moderate and strong ER $\beta$  expression had a higher mean age, but this difference was not statistically significant.

The difference in the pattern of ER $\beta$  expression in males and females were marginally significant (P=0.058) and women showed more cases of strong expression compared to men.

As shown in Table 1, the cases with weak ER $\beta$  expression were mainly high-grade tumors (90% grade III and IV), while this figure dropped to 54.7% in samples that showed strong ER $\beta$ . This difference was statistically significant (P<0.001).

In cases with the diagnosis of oligodendroglioma, no weak ER $\beta$  expression was detected. Majority of the grade II cases showed strong ER $\beta$  expression, while the majority of the grade III cases demonstrated moderate expression. However, this difference was not statistically significant (Figure 3).

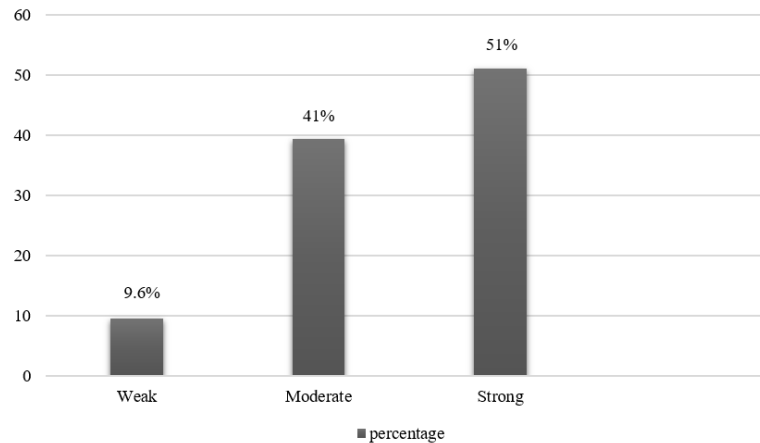


Fig. 2. The percentage of various levels of ER $\beta$  expression in all 104 cases

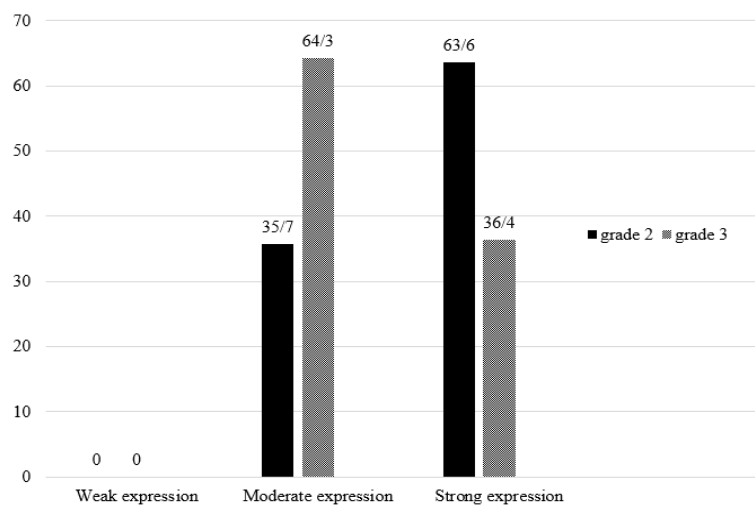


Fig. 3. ER $\beta$  expression in various grades of oligodendroglioma

**Table 1.** Frequency of different tumor grades based on the ER $\beta$  expression

Grade \ ER $\beta$ expression	1	2	3	4
Weak	1 (10%)	0	0	9 (90%)
Moderate	2 (4.9%)	6 (14.6%)	11 (26.8%)	22 (53.7%)
Strong	3 (5.7%)	21 (39.6%)	6 (11.3%)	23 (43.4%)

## Discussion

In recent years, there has been growing interest in finding novel therapeutic options in order to improve the survival of patients with glial tumors, especially high-grade tumors (13,14).

Data from recent studies suggest a possible protective role of female sex hormones in glioma progression (3). It has been observed that different grades of gliomas demonstrate different levels of estrogen receptor expression, with higher levels of expression seen in lower grade tumors (1).

While a few studies have described a decline in ER $\alpha$  expression, a growing body of evidence has shown a decrease in ER $\beta$  expression with increasing histological grade of astrocytomas. Besides, while some studies have reported increased ER $\alpha$  expression as a biomarker of good prognosis, the majority have described increased ER $\beta$  expression as a favorable biomarker (15-18).

Previous and ongoing clinical trials have also shown that ER $\beta$  agonists are well tolerated with acceptable side effects. Therefore, they might be considered as a therapeutic option to enhance the survival and the quality of life of the patients with glial tumors (18,19). In our study, none of the samples were positive for ER $\alpha$ , while all the samples were found to be positive for ER $\beta$ . One reason for this finding could be the fact that low levels of ER $\alpha$  expression could not be evaluated accurately by the IHC method (14,16).

Similar to many previous studies, ER $\beta$  in different grades of astrocytic tumors had different patterns of expression and its expression decreased by increasing tumor grade (1,14).

However, there are some contradictory reports. Lie *et al.*, found in their study that ER $\beta$  expression increased in higher-grade glial tumors. They proposed that this finding could be due to the hypoxia-induced expression of this ER $\beta$  subtype as a self-protective mechanism against tumor proliferation (12).

Statistically, the pattern of ER $\beta$  receptors expression in men and women was marginally different. Females showed more cases of strong expression, while in male samples, moderate expression was the dominant pattern. This is in line with the results of many previous studies indicating that endogenous estrogens could have beneficial effects against glioma development. As a result, women generally have a lower incidence than men (12).

In our study, astrocytomas mainly showed moderate or strong levels of expression and weak expression was rare. This finding was in contrast to the findings of Batistato *et al.*, who reported that half of their astrocytic tumoral cases demonstrated weak or no ER $\beta$  expression (1).

Seventy percent of oligodendroglial tumors in our study showed no or weak ER $\beta$  expression and similar to the previous studies (14), we did not find any correlation between oligodendrogloma grade and expression of estrogen receptors.

## Conclusion

Our study demonstrated that while there was no ER $\alpha$  expression detection, ER $\beta$  is probably expressed in the majority (if not all) of the glial tumors and its expression is conversely correlated with tumor grade. Previous and ongoing clinical trials have shown that ER $\beta$  agonists are well tolerated with acceptable side effects. Further trials are needed to clarify the potential role of ER $\beta$  agonists as a therapeutic option to enhance survival and quality of life of the patients with glial tumors.

## Acknowledgements

The authors would like to thank the faculty, staff and residents of the pathology department of Shohaday-e Tajrish Hospital for their help and support.

## Conflict of Interest

The authors declared that there is no conflict of interest regarding the publication of this article.

## References

- Sareddy GR, Nair BC, Gonugunta VK, Zhang QG, Brenner A, Brann DW, et al. Therapeutic significance of estrogen receptor  $\beta$  agonists in gliomas. *Mol Cancer Ther.* 2012 May;11(5):1174-82. [DOI:10.1158/1535-7163.MCT-11-0960] [PMID] [PMCID]
- Louis DN, Ohgaki H, Wiestler OD, Cavenee WK, Burger PC, Jouvet A, et al. The 2007 WHO classification of tumours of the central nervous system. *Acta neuropathologica.* 2007 Aug;114(2):97-109. [DOI:10.1007/s00401-007-0243-4] [PMID] [PMCID]
- Li W, Winters A, Poteet E, Ryou MG, Lin S, Hao S, et al. Involvement of estrogen receptor  $\beta$ 5 in the progression of glioma. *Brain Res.* 2013 Mar 29;1503:97-107. [DOI:10.1016/j.brainres.2013.02.004] [PMID] [PMCID]
- Batistatou A, Stefanou D, Goussia A, Arkoumani E, Papavassiliou AG, Agnantis NJ. Estrogen receptor beta (ER $\beta$ ) is expressed in brain astrocytic tumors and declines with dedifferentiation of the neoplasm. *J Cancer Res Clin*



- Oncol. 2004 Jul;130(7):405-10. [DOI:10.1007/s00432-004-0548-9] [PMID]
5. Sareddy GR, Vadlamudi RK. Cancer therapy using natural ligands that target estrogen receptor beta. *Chin J Nat Med.* 2015 Nov;13(11):801-807. [DOI:10.1016/S1875-5364(15)30083-2]
  6. Dueñas JM, Arellano AC, Santerre A, Suárez SO, Sánchez HS, Romero IF, et al. Aromatase and estrogen receptor alpha mRNA expression as prognostic biomarkers in patients with astrocytomas. *J Neurooncol.* 2014 Sep;119(2):275-84. [DOI:10.1007/s11060-014-1509-z] [PMID]
  7. Kabat GC, Etegen AM, Rohan TE. Do steroid hormones play a role in the etiology of glioma? *Cancer Epidemiol Biomarkers Prev.* 2010 Oct;19(10):2421-7. [DOI:10.1158/1055-9965.EPI-10-0658] [PMID]
  8. Ungureanu G, Iancu I, Chitu A, Berce C, Florian IS, Ungureanu G. Estrogen Receptor Expression in Glioblastoma Influences PFS and Life Expectancy of Patients. *Neuro Oncol.* 2014 Sep;16(Suppl 2):ii108-ii109. [DOI:10.1093/neuonc/nou174.419] [PMCID]
  9. Arevalo MA, Galindo MS, Lagunas N, Azcoitia I, Segura LM. Selective estrogen receptor modulators as brain therapeutic agents. *J Mol Endocrinol.* 2011 Jan 19;46(1):R1-9. [DOI:10.1677/JME-10-0122] [PMID]
  10. Wigertz A, Lönn S, Mathiesen T, Ahlbom A, Hall P, Feychting M, et al. Risk of brain tumors associated with exposure to exogenous female sex hormones. *Am J Epidemiol.* 2006 Oct 1;164(7):629-36. [DOI:10.1093/aje/kwj254] [PMID]
  11. Liu X, Wang L, Chen J, Ling Q, Wang H, Li S, et al. Estrogen receptor  $\beta$  agonist enhances temozolomide sensitivity of glioma cells by inhibiting PI3K/AKT/mTOR pathway. *Mol Med Rep.* 2015 Feb;11(2):1516-22. [DOI:10.3892/mmr.2014.2811] [PMID]
  12. Sareddy GR, Li X, Liu J, Viswanadhapalli S, Garcia L, Gruslova A, et al. Selective Estrogen Receptor  $\beta$  Agonist LY500307 as a Novel Therapeutic Agent for Glioblastoma. *Sci Rep.* 2016 Apr 29;6:24185. Liu C, Zhang Y, Zhang K, Bian C2, Zhao Y, Zhang J. Expression of estrogen receptors, androgen receptor and steroid receptor coactivator-3 is negatively correlated to the differentiation of astrocytic tumors. *Cancer Epidemiol.* 2014 Jun;38(3):291-7. [DOI:10.1016/j.canep.2014.03.001] [PMID]
  13. Tavares CB, Braga Fd, Silva DR, Dourado CS, Borges US, Junior AM, et al. Expression of estrogen and progesterone receptors in astrocytomas: a literature review. *Clinics (Sao Paulo).* 2016 Aug;71(8):481-6. [DOI:10.6061/clinics/2016(08)12]
  14. Kefalopoulou Z, Tzelepi V, Zolota V, Grivas PD, Christopoulos C, Kalofonos H, et al. Prognostic value of novel biomarkers in astrocytic brain tumors: nuclear receptor co-regulators AIB1, TIF2, and PELP1 are associated with high tumor grade and worse patient prognosis. *J Neurooncol.* 2012 Jan;106(1):23-31. [DOI:10.1007/s11060-011-0637-y] [PMID]
  15. Daras M, Cone C, Peters KB. Tumor progression and transformation of low-grade glial tumors associated with pregnancy. *J Neurooncol.* 2014 Jan;116(1):113-7. [DOI:10.1007/s11060-013-1261-9] [PMID]
  16. Lan YL, Zou S, Wang X, Lou JC, Xing JS, Yu M, et al. Update on the therapeutic significance of estrogen receptor beta in malignant gliomas. *Oncotarget.* 2017 Sep;8(46):81686-96. [DOI:10.18632/oncotarget.20970]
  17. Zhou M, Sareddy GR, Li M, Liu J, Luo Y, Venkata P, et al. Estrogen receptor beta enhances chemotherapy response of GBM cells by down regulating DNA damage response pathways. *Sci Rep.* 2019 Apr 16;9(1):6124. [DOI:10.1038/s41598-019-42313-8] [PMID] [PMCID]
  18. Micevych P, Bondar G, Kuo J. Estrogen actions on neuroendocrine glia. *Neuroendocrinology.* 2010 Mar 24;91(3):211-22. [DOI:10.1159/000289568] [PMID] [PMCID]

#### How to Cite This Article

Shafiei, M., Mafi, A., Nilipour, Y., Sourati, A., Sasanpour, P., Tabatabaeefar, M. Estrogen Receptor Expression in Glial Tumors of Iranian Patients: A Single Center Experience. *Iranian Journal of Pathology*, 2019;15 (1): 8-12. doi: 10.30699/ijp.2019.95525.1946