

Beware of Bone Marrow: Incidental Detection and Primary Diagnosis of Solid Tumours in Bone Marrow Aspiration and Biopsies; A Study of 22 Cases

Ruchita Tyagi^{1*}, Aminder Singh¹, Bhavna Garg¹, Neena Sood¹

1. Dept. of Pathology, Dayanand Medical College and Hospital, Tagore Nagar, Ludhiana, India

KEYWORDS

Bone marrow aspiration
Biopsy
Metastatic Deposit
Primary Diagnosis

ABSTRACT

Background & objective: Introduction: First detection of any solid tumour as metastatic deposits in bone marrow directs clinicians to start searching for the primary tumour. Detection of bone marrow metastasis determines the stage of the malignancy, prognosis, mode of treatment, chemotherapeutic response and follow-up in case of relapse. The aim of the current study was to analyse the clinico-haematological presentation and morphological pattern of infiltration of solid tumours detected first as metastatic deposits on bone marrow examination.

Methods: Three-year retrospective analysis of MGG-stained bone marrow aspiration smears and touch imprints of the bone marrow biopsy and Hematoxylin and Eosin (H&E) stained histopathological sections of biopsies was performed at the Department of Pathology at a tertiary care institute (January 2014 to December 2016). The morphological pattern of metastatic deposits and haematological profiles of the patients were analysed. Exclusion criterion was the presence of hematolymphoid malignancies.

Results: In 22 cases, bone marrow was the first site of detection of metastasis. The age of the patients ranged from 3 years and 10 months to 82 years, with equal gender predilection. Overall, 16 cases had cytopenias, 9 cases each had leucocytosis and leukoerythroblastic presentation. The metastasis was from Ewing's sarcoma, prostate carcinoma, gastric adenocarcinoma invasive duct carcinoma breast, gallbladder carcinoma, lacrimal duct carcinoma and invasive papillary urothelial carcinoma.

Conclusions: Bone marrow examination is a cheap and reliable investigation to detect metastasis in an unsuspecting case. Bilateral trephine biopsies are recommended to increase the efficacy of detecting bone marrow metastasis.

Article Info

Received 30 Dec 2016;
Accepted 26 Apr 2017;
Published Online 2017;

Corresponding information: Ruchita Tyagi, Assistant Professor, Department of Pathology, Dayanand Medical College and Hospital, Tagore Nagar, Ludhiana – 141012, Punjab, Phone number: +919876589911, Email: ruchitatyagi@gmail.com

Copyright © 2017, IRANIAN JOURNAL OF PATHOLOGY. This is an open-access article distributed under the terms of the Creative Commons Attribution-noncommercial 4.0 International License which permits copy and redistribute the material just in noncommercial usages, provided the original work is properly cited.

Introduction

It is very rare to detect non-hematologic solid tumours while examining the bone marrow smears and/or bone biopsy sections. First time detection of any solid tumour as metastatic deposits in bone marrow alarms the pathologist and helps clinicians to start searching for the primary tumour (1). Any tumour capable of haematogenous spread could involve the bone marrow. Detection of bone marrow metastatic deposits is important to determine the stage of the malignancy, prognosis, mode of treatment, chemotherapeutic response, and follow-

up in case of relapse (1,2). Patients present anaemia or pancytopenia which does not improve on treating with hematinics. Sometimes haematological indices may be within the normal limits even if the bone marrow shows metastatic deposits. The detection of metastatic deposits in bone marrow helps clinicians to investigate for the primary tumour and heralds a poor prognosis (2,3). The aim of this study was to analyse the clinical and haematological presentation of tumours detected first as metastatic deposits on bone marrow examination, and assess the association

of bone marrow aspirate findings with trephine biopsy features.

Material and methods

This was an observational study based on retrospective analysis of bone marrow aspiration smears and biopsies received at the Department of Pathology at a tertiary care institute, over a period of 3 years (2014 to 2016). Bone marrow examination of adult patients was performed at the Department of Pathology while paediatric bone marrow examinations were performed at the Department of Paediatrics. The air-dried slides and biopsy specimens were received at the Department of Pathology for processing and staining. The aspiration smears and touch imprints of the biopsy were stained with May Grunwald Giemsa and Perl's Prussian Blue while the biopsies were fixed in formalin, decalcified in nitric acid and routinely processed and stained with Haematoxylin and Eosin (H&E). Reticulin and other special stains were also used as required. Immunohistochemical staining was performed according to clinical details and morphological features of the metastasis.

Three millilitres of peripheral blood was collected in an EDTA vial and run in the autoanalyser (Beckman Coulter LH 750) to estimate the haematological parameters. Peripheral smears were prepared and stained with MGG and examined under the microscope for morphology. Hematolymphoid malignancies were not included in this study.

Results

Of 2860 bone marrows reported at the Department of Pathology from January 2014 to December 2016, 22 cases showed metastatic deposits from solid tumours, accounting for 0.8% of samples. The youngest patient was 3-year and 10-month old child while the oldest patient was 82 years. The average age was 56.7 years.

Male to female ratio was 1.2:1. Eleven patients reported fever on presentation. Backache was observed in 4 patients, while 3 patients complained

of abdominal pain. Two patients each complained of epistaxis and breathlessness.

Biochemical findings – Seven patients had raised serum levels of Alkaline Phosphatase (ALP) while increased levels of Lactate Dehydrogenase (LDH) and calcium were observed in three patients each. In 2 patients, Prostate Specific Antigen (PSA) levels were elevated.

Radiological findings- Radiological evidence of skeletal deposits was noted in seven cases. Four patients had evidence of deposits in their liver while pulmonary deposits were noted in 3 cases using Magnetic Resonance Imaging (MRI).

Peripheral smear findings- Pancytopenia was observed in one patient. Eleven cases had bicytopenia (thrombocytopenia and anaemia). Four patients had only anaemia, 2 had only thrombocytopenia. Nine cases had leucocytosis. Ten cases had leukoerythroblastic images (Table I).

Table 1. Peripheral Blood Findings

Haematological features	No of cases
Anaemia	4
Thrombocytopenia	2
Pancytopenia	1
Bicytopenia	11
Leucocytosis	9
Leukoerythroblastemia	10

Bone marrow findings - Aspirates were hypercellular in 7 cases, normocellular in 4 cases, diluted in 8 cases and dry tap was obtained in 4 cases. In 7 cases, there was no evidence of tumour cells on aspirate smears while the touch imprints showed presence of tumour cell clusters. In addition, in 3 cases, there was no evidence of tumour in the aspirates as well as the touch imprints, while the bone marrow biopsy sections revealed presence of tumour deposits. In 8 cases, fibrosis and sclerosis were also seen in the trucut bone biopsy along with tumour deposits. In 18 cases, the tumour was predominantly present as clusters in the biopsy (Figure 3), while 8 cases also had sheets of tumour cells (Figure 1 d)

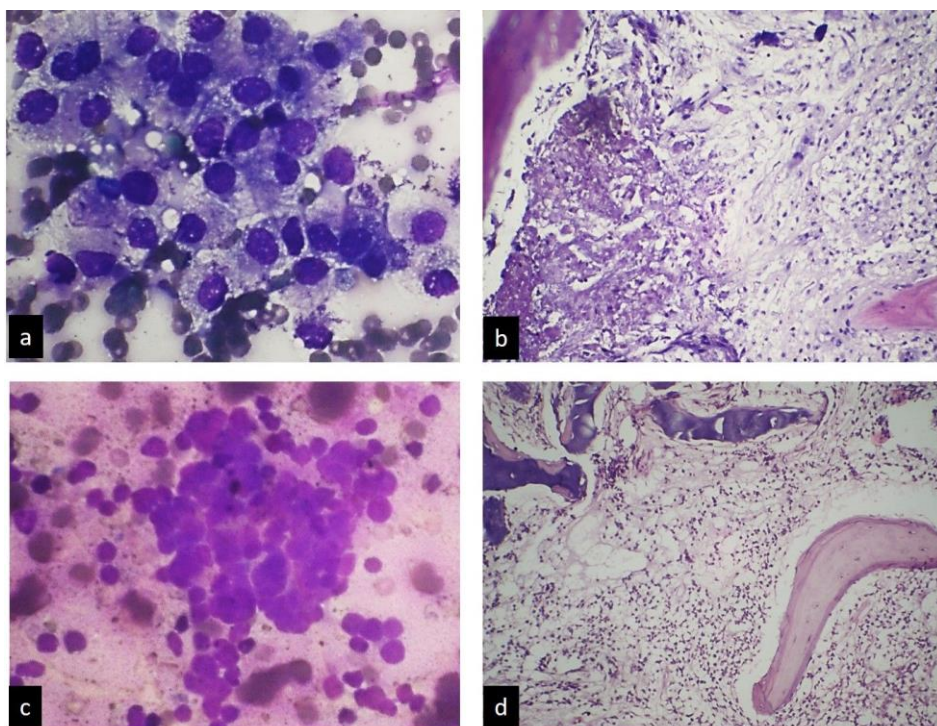
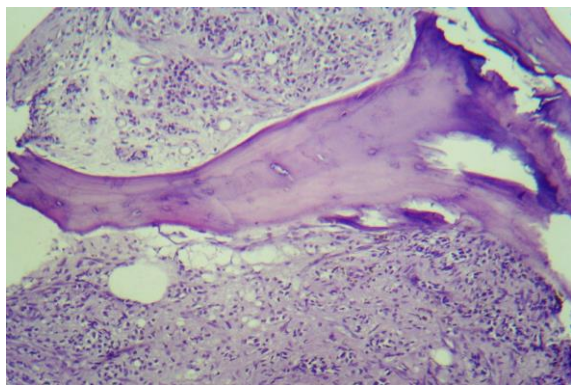


Fig 1. Figure 1 : a) Bone marrow aspirate in case of prostatic carcinoma showing clusters of tumor cells with nuclear crowding, overlapping and moderate amount of cytoplasm with fine vacuolations (MGG, 400x); b) Trehine biopsy section of same case showing foci of necrosis and fibrosis in marrow (H&E, 100x); c) Bone marrow aspirate in Ewing's sarcoma showing clusters of round tumor cells with hyperchromatic nuclei and scanty cytoplasm (MGG, 100x); d) Trehine biopsy section of same case showing diffuse sheets of tumor cells in intertrabecular spaces (H&E,100x).



In six cases, glandular pattern of arrangement of metastatic deposits were found on biopsy sections (Figure 2) (Table II).

Fig 2. Glandular arrangement of tumor cells with surrounding desmoplastic reaction in bone marrow biopsy in case with metastasis from gastric adenocarcinoma. (H&E, 100x)

Table 2. Bone Marrow Findings

Bone marrow features	No of cases
Dry tap	4
Diluted marrow	8
Normocellular	4
Hypercellular	7
Metastatic deposits in touch imprints & biopsy, absent in aspirate smears	7
Metastatic deposits in trephine biopsy only	3
Metastatic deposits in both aspirate & biopsy	12
Fibrosis on biopsy	8
Tumour cells as clusters	18
Tumour cells in sheets	8
Tumour cells in glandular pattern	6

In the current study, the researchers had only one case of Ewing's sarcoma and the patient was 22 years old, with extradural spread of the tumour at the level of D6 thoracic spine. The aspirate showed clusters of round cells with hyper-chromatic nuclei and scanty cytoplasm (Figure 1c). The trephine biopsy showed diffuse sheets of small round tumour cells replacing all hematopoietic elements (Figure 1d). Among adults, there was one patient with Gastric carcinoma (Figure 2), 3 patients each with prostate carcinoma (Figure 1 a and b) and invasive ductal carcinoma of the breast. One case each of gallbladder carcinoma, serous carcinoma ovary (Figure 3), lacrimal duct carcinoma and invasive papillary urothelial carcinoma were also seen. In one of the cases with breast carcinoma, after detecting metastasis in the bone marrow, FNAC of a neglected breast lump, present for 18 years, was performed, which confirmed the presence of invasive ductal carcinoma. The other patient was a treated case of breast carcinoma, who sought medical attention for dengue fever. She was found to have thrombocytopenia and anaemia. Radiological investigations indicated the presence of pulmonary and hepatic deposits while detection of tumour cells on bone marrow confirmed the presence of skeletal metastasis. Those patients who were later found to have gastric cancer, papillary urothelial carcinoma and lacrimal duct carcinoma had lytic bony lesions and metastatic deposits on bone marrow examination confirmed the presence of a malignancy (Table III). Ten patients were lost to follow-up and primary tumour could not be ascertained.

Table 3. Primary Tumors as a Source of Bone Marrow Metastasis

Primary	No of cases
Ewing's sarcoma	1
Gastric adenocarcinoma	1
Prostate carcinoma	3
Invasive duct carcinoma breast	3
Gall bladder adenocarcinoma	1
Lacrimal duct carcinoma	1
Papillary urothelial carcinoma	1
Serous carcinoma ovary	1
Unknown	10
Total	22

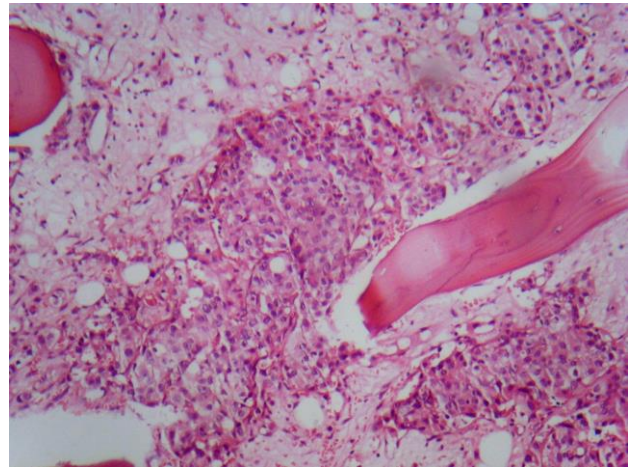


Fig 3. Trephine biopsy section from case having metastasis from serous carcinoma ovary showing tumor cells arranged in nests and clusters. (H&E, 100x)

Discussion

Bone involvement by solid tumours can be diagnosed on CT, MRI or bone scan yet histopathological examination is required for confirmation. Detection of tumour cells on bone marrow aspiration smears and biopsy increases the stage of the tumour and reduces the overall survival rate. Bone marrow examination is also performed in patients with a relapse (2 - 4).

Bone pain, hypercalcemia, raised levels of ALP and /or LDH, unexplained cytopenias and lytic or sclerotic bony lesions on radiology suggest bone marrow metastasis (5-8). In the current study, only 4 patients presented back-pain, 5 cases had elevated ALP levels and only 3 patients had hypercalcemia. Even though bone scans and X rays could predict bone marrow involvement by tumour, only 7 cases had radiological evidence of skeletal deposits in the current study.

We found leucocytosis in 9 cases (around 45%). Chauhan et al. observed leucocytosis in 25% of their cases (7). Anaemia was seen in 4 cases, thrombocytopenia in 2 and bicytopenia (anaemia with thrombocytopenia) was observed in 9 patients. Peripheral leukoerythroblastic picture was seen in nine cases. Cytopenias and leukoerythroblastosis have been commonly reported in bone marrow infiltrative disorders (2,6,7,9). Mehdi and Bhat also observed anaemia, thrombocytopenia, and pancytopenia in 71.4%, 45.1%, and 19.3% of their cases, respectively (10). Anaemia and cytopenias result from myelophthitic anaemia due to bone

marrow metastasis (11). Overall, 30% to 35% of cases of skeletal metastasis may have leukoerythroblastic images, which is mainly a result of bone marrow fibrosis due to metastasis and does not correlate with the extent of bone marrow involvement. Another feature associated with bone marrow fibrosis is 'dry tap' or diluted aspirate as a result of multiple failed attempts at aspiration (6,9). In this study, the aspirate was diluted with blood in 7 cases while dry tap was obtained in 3 cases. Fibrosis and osteosclerosis is commonly associated with bone marrow metastasis, as was also noted in 8 cases of this study. Osteonecrosis and tumour necrosis observed in 1 case with metastasis from prostatic adenocarcinoma. Some authors have also observed eosinophilia, reactive plasmacytosis, osseous metaplasia, desmoplasia, granulomas, necro-inflammation and infections in the bone marrow as a response to metastatic deposits (1,9). Sometimes megakaryocytes, crushed erythroid precursors, osteoblasts, osteoclasts or stromal macrophages may simulate cells of non-hematologic origin and be misinterpreted as metastatic deposits. The IHC on bone biopsy or clot sections could distinguish haematological cells from tumour cells (2).

In the current study, metastatic deposits were absent on aspirate in 3 cases (14.3%) while the biopsy sections showed tumour cells. The current researchers found tumour cells in examination of all the biopsy sections, unlike Sharma and Murari, who reported the rare presence of metastasis only on aspirate smears (3). Chauhan et al. also found metastatic tumour cells in only aspirate smears of a case of small cell carcinoma lung, while there was no tumour seen on the biopsy section. They have attributed this phenomenon to inadequate length of bone biopsy (7). Toi et al. found metastatic deposits on bone marrow biopsy alone in 2 of 6 (33%) cases. In their study, there was a single case in which aspirate smears demonstrated metastatic tumour cells while the biopsy section showed infarcted marrow. They reported 50% correlation between aspiration smears and biopsy sections in cases of metastasis from solid tumour (12). Absence of tumour cells on aspirates could be explained by patchy involvement of the marrow and marrow fibrosis caused by the presence of tumour cells resulting in dry tap. Biopsy sections, especially when

taken from multiple sites, like bilateral posterior superior iliac spines and sternum, increase the volume of the marrow examined and hence the chances of detecting metastatic deposits (6,14). Although many studies have debated over the superiority of biopsy sections over aspirate smears, both aspiration and biopsy are considered complimentary modalities to detect metastasis in bone marrow (1,6,7,9,12,15,16). Toi et al. have supported the examination of touch imprint smears of biopsy for better evaluation of tumour cell morphology (12). Singh et al. additionally recommend the examination of clot sections of aspirates to increase the rate of detecting metastasis (5). No study conclusively declared the superiority of either one among aspirate smears, clot sections, touch imprints or biopsy sections, over others. The metastatic deposits of round cell tumours like rhabdomyosarcoma and neuroblastoma may be too subtle to be readily identified on trephine biopsy sections and are better appreciated on aspirate smears. On the other hand, histological arrangement of tumour cells like nests, clusters, and glands can be easily detected on biopsy sections. Besides, clot sections and biopsy specimens can be used for immunohistochemistry, which may help in determining the origin of metastatic deposits, in case of an unknown primary tumour (2,5,6). The 2 most important primary sites that must be identified are breast and prostate as these tumours respond to hormonal therapy (7).

Among children, Ewing's sarcoma, rhabdomyosarcoma, and neuroblastoma are the commonest tumours that invade the bone marrow. Carcinomas of GIT, prostate, and breast are the commonest causes of bone marrow involvement in adults (1,2,6,7,9). In the current study, the researchers had only one case of Ewing's sarcoma and the patient was a 22-year-old, with extradural spread of the tumour at the level of D6 thoracic spine. Among adults, we had 1 patient, who was subsequently detected to have gastric carcinoma, and 3 patients each with prostate carcinoma and invasive duct carcinoma breast. Mehdi and Bhatt found gastric carcinoma in 5 cases, prostate carcinoma in 9 cases, breast carcinoma in 8 cases and 1 case each of Ewing's sarcoma and unknown primary anaemia, which resulted in bone marrow metastasis in their

study (10). Toi et al. reported bone marrow metastasis from gastric carcinoma in 3 patients and breast carcinoma as primary tumour in 1 patient (12). One of our 2 cases of breast carcinoma had already received treatment for the same reason and had sought medical attention for dengue fever. Radiological investigations suggested lytic lesions in the bone, which were confirmed to be metastatic deposits on bone marrow examination. Chauhan et al. also described a similar scenario of relapsed breast cancer (post mastectomy) with extensive bone marrow infiltration (7). Other primary tumours detected in the current study were one case each of gall bladder carcinoma, lacrimal duct carcinoma, and invasive papillary urothelial carcinoma. The IHC can be used on biopsy sections to detect the site of primary tumours.

Conclusion

Bone marrow examination is a cheap, highly effective and confirmatory investigation to detect metastasis in an unsuspecting case, in which the stage of the tumour is already known and to check for bone marrow involvement in a case of relapse (2). Bilateral trephine biopsies are recommended to increase the efficacy of detecting bone marrow metastasis (12). Being invasive in nature, some patients may not give consent for bone marrow examination (5). In such a scenario, proper counselling and use of adequate local anaesthesia is required to alleviate the anxiety of patient and caregivers. Accurate detection of tumour cells by the pathologist is the cornerstone of appropriate management of patients with bone marrow involvement by solid tumours. The IHC on biopsy sections can help determine the nature of an unknown primary tumour first detected accidentally on bone marrow.

References

1. Mishra P, Das S, Kar R, Jacob SE, Basu D. Non-hematopoietic malignancies metastasising to the bone marrow: A 5 year record based descriptive study from a tertiary care centre in South India. *Indian J Cancer* 2014;51:30-4.
2. Kucukzeybek BB, Calli AO, Kucukzeybek Y, Bener S, Dere Y, Dirican A, et al. The prognostic significance of bone marrow metastases: Evaluation of 58 cases. *Indian J PatholMicrobiol* 2014;57:396-9.
3. Sharma S, Murari M. Bone marrow involvement by metastatic solid tumors. *Indian J PatholMicrobiol* 2003;46:382-4.
4. Sambit KM, Sumitra Dash. Bone marrow metastasis in solid tumors. *Indian J PatholMicrobiol* 2003;46:613-16.
5. Singh MK, Goel MM, Singh US, Dalela D, Shankwar SN, Kumar A. *Clinical Cancer Investigation Journal* 2013;2:319-24.
6. Brahmabhatt B, Parikh B, Shah M. Bone marrow involvement by metastatic solid tumors. *Gujarat Medical Journal* 2014;69:54-7.
7. Chauhan K, Jain M, Grover S, Shukla P, Rusia U, Grover RK. Bone marrow metastasis in non-hematologic malignancies: Data from a cancer hospital. *Clinical Cancer Investigation Journal* 2016;5: 103-9.
8. Ozkalemkas F, Ali R, Ozkocaman V, Ozcelik T, Ozan U, Ozturk H, et al. The bone marrow aspirate and biopsy in the diagnosis of unsuspected nonhematologic malignancy: a clinical study of 19 cases. *BMC Cancer* 2005;5:144.
9. Mohanty SK, Dash S. Bone marrow metastasis in solid tumors. *Indian J PatholMicrobiol* 2003;46:613-6.
10. Mehdi SR, Bhatt MLB. Metastasis of solid tumors in bone marrow: a study from Northern India. *Indian J Hematol Blood Transfus* 2011;27:93-5.
11. Tasleem RA, Chowdhary ND, Kadri SM, Chowdhary QA. Metastasis of solid tumors in bone marrow: a study from Kashmir India. *J Clin Pathol* 2003;56:803-4.
12. Toi PC, Varghese RG, Rai R. Comparative evaluation of simultaneous bone marrow aspiration and bone marrow biopsy : an institutional experience. *Indian J Hematol Blood Transfus* 2010;26:41-44.

13. Kaur G, Basu S, Kaur P, Sood T. Metastatic Bone Marrow Tumors: Study of Nine Cases and Review of the Literature. *J Blood DisordTransfus* 2011;2:110. doi:10.4172/2155-9864.1000110

14. Basu D, Singh T, Shinghal RN. Micrometastasis in bone marrow in brain cancer. *Indian J PatholMicrobiol* 1994;38:159-64.

15. Bearden JD, Ratkin GA, Coltman CA. Comparison of the diagnostic value of bone marrow biopsy and bone marrow aspiration in neoplastic disease. *J Clin Pathol* 1974;27:738-40.

16. Gupta N, Kumar R, Khajuria A. Diagnostic assessment of bone marrow aspiration smears, touch imprints and trephine biopsy in non-hematological disorders. *JK Sci* 2011;13:70-2.

How to Cite This Article

Tyagi, R., Singh, A., Garg, B., Sood, N. Beware of Bone Marrow: Incidental Detection and Primary Diagnosis of Solid Tumours in Bone Marrow Aspiration and Biopsies; A Study of 22 Cases. *Iran J Pathol.* 2018; 13(1): 78-84.