

Case Report

Leiomyoma of Scrotum: a Rare Case Report

Shweta Rana, Puja Sharma, Pawan Singh, Rahul N Satarkar

Dept. of Pathology, SHKM, GMC, Nalhar, Mewat, Haryana.

ABSTRACT

Leiomyomas are benign tumors that originate from smooth muscle cells. Leiomyomas are well known to be the commonest neoplasm arising from the uterus but leiomyomas originating from the scrotum is a rare entity. They originate from the subcutaneous tissue or tunica dartos and can be solitary or multiple. We present a case of solitary scrotal leiomyoma in a 75 years old male who presented with a slowly growing, painless, firm, mobile 4cm lump in right side of scrotum. Clinically, it was provisionally diagnosed as sebaceous cyst and was excised. Histopathology and Immunohistochemistry (IHC) showed findings consistent with Leiomyoma. There was no cytological atypia or mitosis. The final diagnosis of scrotal leiomyoma was given.

Keywords: Scrotum, Leiomyoma, Case Report

Introduction

Leiomyoma is a benign tumor of smooth muscles that can arise almost anywhere in the body. Leiomyoma of the scrotum is a rare entity described as a benign pathology arising from the subcutaneous tissue or dartos muscle (1). Superficial leiomyoma of skin and subcutaneous tissue can be of three types; (a)

tumor of arrector pili muscles (piloleiomyoma), (b) tumors of smooth muscles of blood vessels (angioleiomyoma), and (c) genital leiomyoma (from the smooth muscles of nipple, vulva and scrotum) (2). Smooth muscle tumors of scrotum were first described by Forsters in 1858 and are reported to be extremely rare (3). Cutaneous leiomyomas account for approximately 5% of all leiomyomas, and genital leiomyomas, such as

Received: 25 April 2014

Accepted: 11 July 2014

Address communications to: Dr. Shweta Rana, Department of Pathology, SHKM, GMC, Nalhar, Mewat, Haryana.

Email: drshwetarana15@gmail.com

scrotal leiomyoma, have an even lower incidence rate (4). Siegel and Gaffey (1) demonstrated the rarity of this tumor finding only 11 cases in a review of 11000 cases of scrotal tumor. Their recurrence and malignant transformation have been described (1).

Keeping in view the rarity of this tumor, we report a case of solitary scrotal leiomyoma.

Case Report

A 75-years-old man presented with the complaints of a painless mass right side of scrotum for 2 years. Physical examination revealed a single well-defined, soft to firm, non-tender, mobile lump of $4 \times 3 \times 3$ cm³ on anterior aspect of right scrotum. It had no palpable connection to the testis, epididymis or spermatic cord. The overlying skin was normal without any ulceration. Both the testes were normal without any palpable inguinal lymph nodes. The lump was clinically diagnosed as sebaceous cyst. The

lump was excised from the scrotal dartos layer and sent for histopathological examination.

Gross examination showed a single, skin covered, firm tissue mass measuring $3 \times 2.5 \times 2.5$ cm³ (Fig. 1a). Cut surface showed solid, grey white, homogenous character with whirling (Fig. 1b). Haematoxylin and eosin stained microsections revealed a well-circumscribed tumor composed of spindle shaped cells having blunt ended elongated nuclei and eosinophilic cytoplasm arranged in interlacing and whirling pattern (Fig. 2a); nuclear pleomorphism and mitoses were absent (Fig. 2b). Immunostaining for smooth muscle actin (SMA) was done on paraffin embedded sections using immunoperoxidase stain and diaminobenzidine method (Zymed, 1:100 dilution). The tumour showed SMA positivity on immunohistochemistry, confirming smooth muscle phenotype (Fig. 2c and 2d). On the basis of histopathological and IHC profile a diagnosis of scrotal leiomyoma was made. The patient was kept on follow up.

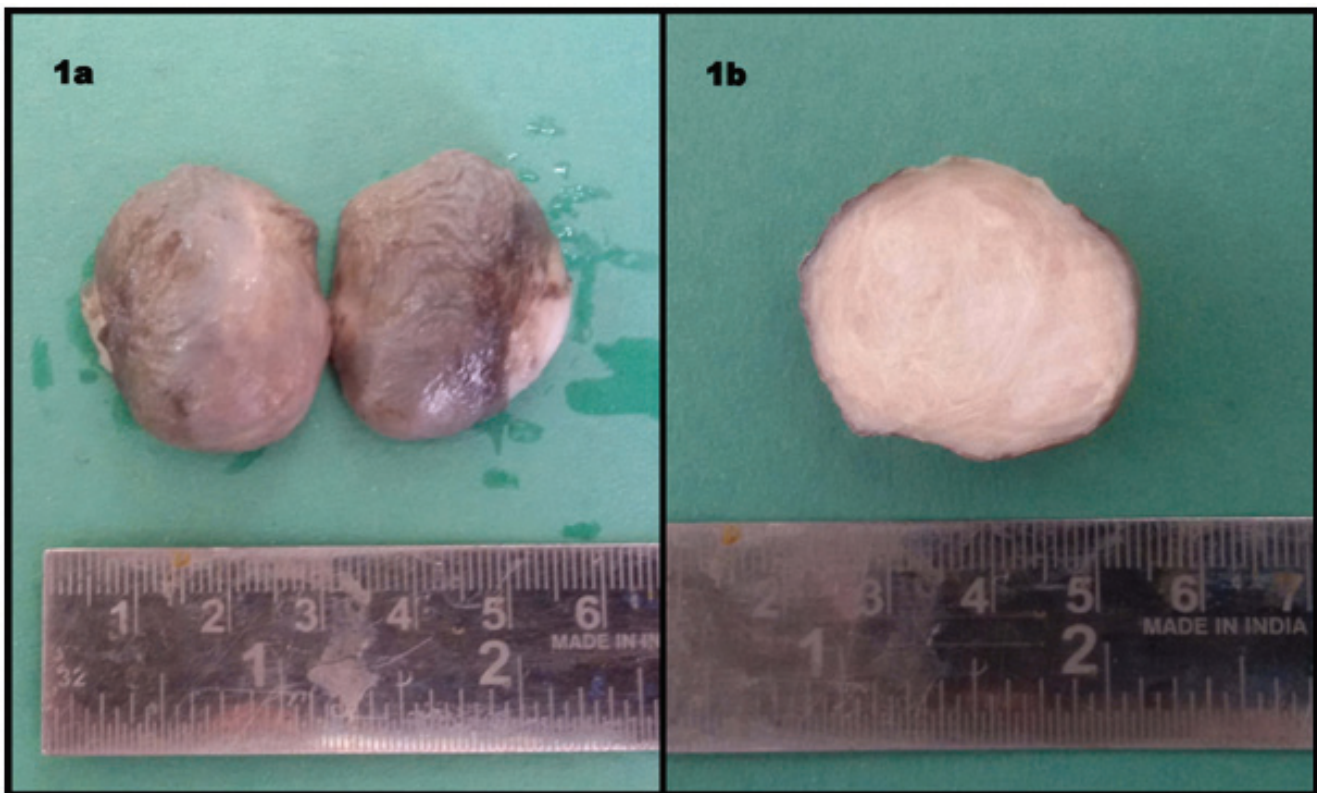


Fig. 1a) Excised skin covered tumor mass; **1b)** Cut section of the tumor showing solid grey white surface with areas of whirling

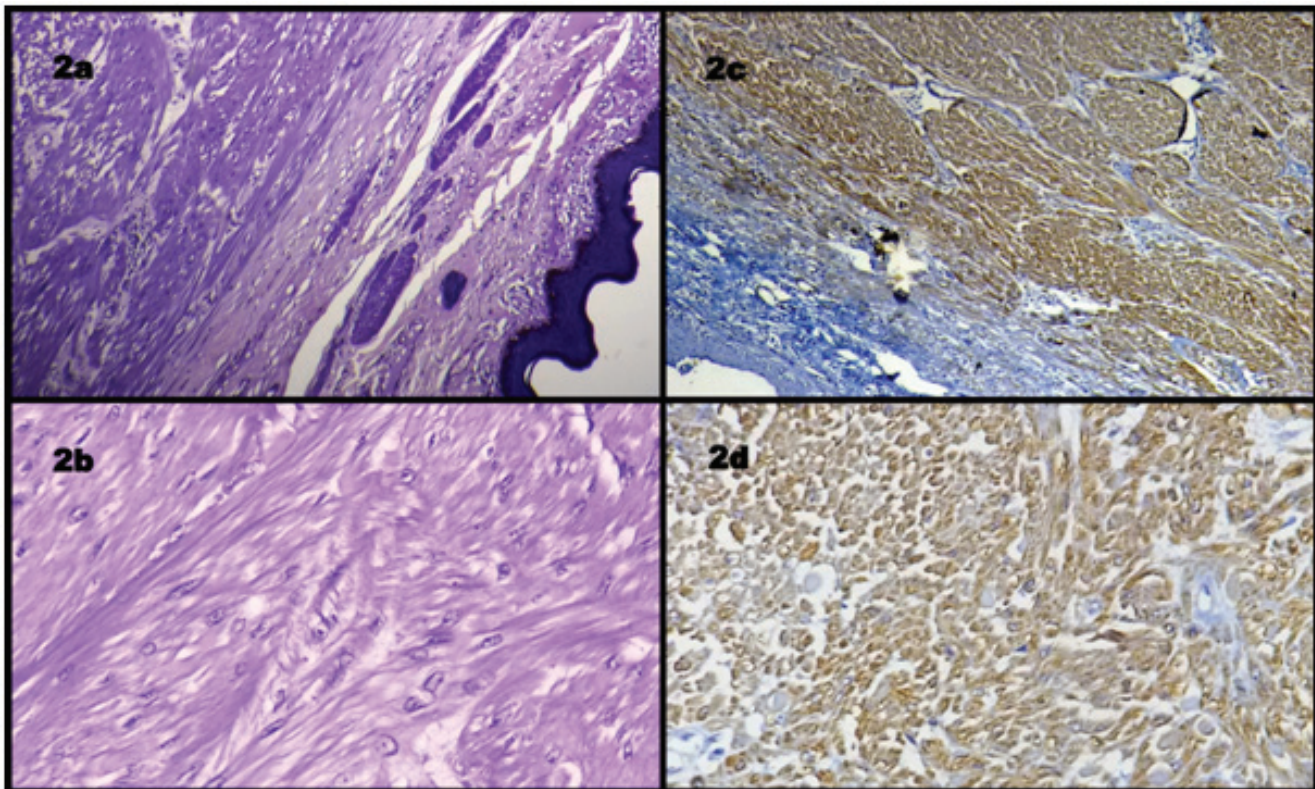


Fig. 2a): Photomicrograph showing well circumscribed tumor mass well delineated from skin; revealing interlacing bundles of spindle shaped leiomyomatous cells. (H&E; $\times 100$); **2b)** Photomicrograph showing interlacing bundles of spindle shaped cells with elongated nuclei and blunt ends. There is no cytological atypia or mitosis (H&E; $\times 400$); **2c)** Photomicrograph showing immunohistochemically smooth muscle actin (SMA) positive expression (SMA, $\times 100$); **2d)** Photomicrograph showing immunohistochemically smooth muscle actin (SMA) positive expression (SMA, $\times 400$)

Discussion

Leiomyomas may originate from any anatomic location of smooth muscle in the genitourinary system (5). Isolated cases of leiomyomas have been reported arising from the renal pelvis, bladder, spermatic cord, and epididymis, prostate as well as the glans penis (5-8). Scrotal wall leiomyomas are rare, usually asymptomatic tunica dartos tumors, commonly seen in middle-aged Caucasian men (1). They are typically slow growing tumors presenting in the fifth decade of life (9). Patients usually present with painless solitary small cutaneous lesion measuring 1-14 cm with the average of 6.4cm (10). Due to their painless and slow growing nature, the patients usually present late with an average of 7.6 years between the patients recognition of the tumor

and its surgical removal (1). In our case, the patient presented within 2 years of lump recognition. A much shorter duration of 10 months between lump recognition and surgical removal has been reported by Sherwani et al. (11). A case of pedunculated scrotal leiomyoma presenting after 20 years of lump recognition has been reported by Chang et al. (12). The painless nature of scrotal leiomyoma corresponds well with the slow growing nature of the tumor pushing the nerve trunk outward rather than compressing it (11). The clinical manifestations of scrotal leiomyoma may not be characteristic of the disease, and in order to identify it, a variety of differential diagnoses should be considered. Clinically, the differential diagnosis includes a sebaceous cyst, fibroma and, if painful, a schwannoma (13). In cases of ulcerative lesions, the scrotal squamous

carcinoma should be included in the differential diagnosis (12).

Scrotal smooth muscle tumours can further be categorized as leiomyoma, atypical leiomyoma and leiomyosarcoma (3). Four pathological features are used to grade the scrotal smooth muscle tumours that include (i) size ≥ 5 cm in greatest dimension; (ii) infiltrating margin; (iii) ≥ 5 mitotic figures per 10 high-power field and (IV) moderate cytological atypia. Tumours with only one of the above-mentioned features are considered benign and those fulfilling two of the criteria are diagnosed as atypical leiomyomas while tumours showing three to four of these criteria are leiomyosarcomas (14). However, in a review of Newman and Fletcher (10), the presence of any mitotic activity was advocated as a criterion of potential malignancy. Thus, it is important for the pathologist to look for them carefully. The nature of the spindle cells can be revealed by immunohistochemical stains. The smooth muscle tumour shows cytoplasmic positivity for smooth muscle actin and desmin and is negative for S100 protein. "A paucicellular tumour with pleomorphic atypical nuclei with a low mitotic activity is termed as pleomorphic/bizarre/ symplasmic or atypical leiomyoma. Nuclear atypia in these tumours represents only a degenerative change. In every histologically diagnosed case of an atypical leiomyoma, the possibility of a leiomyosarcoma has to be ruled out"(10).

Conventional leiomyomas and atypical leiomyomas behave in a similar fashion. "Hence, they are conservatively managed with just an excision while leiomyosarcomas require a wider resection with a 3 to 5 cm margin, including the subcutaneous tissue and fascia and negative margins" (13). Radiation should be avoided for treating leiomyomas as it may induce a malignant transformation (11). Follow-up is required and if recurrence is there a thorough investigation should be carried out to rule out any possibility of malignancy.

This case report highlights the clinicopathological characteristics of the scrotal smooth muscle tumors in order to increase our understanding and thus avoid the possibility of erroneous diagnosis and treatment.

Conflict of Interest

There is no conflict of interest.

References

1. Siegal GP, Gaffey TA. Solitary leiomyomas arising from the tunica dartos scroti. *J Urol* 1976;116(1):69.
2. Livne PM, Nobel M, Savir A, Avidor I, Servadio C. Leiomyoma of the scrotum. *Arch Derm* 1983;119(4):358-9.
3. Das AK, Bolick D, Little NA, Walther PJ. Pedunculated scrotal mass: leiomyoma of scrotum. *Urol* 1992;39(4):376-9.
4. Li SL, Han JD. A case report of atypical Scrotal Leiomyoma. *Case Rep Dermatol* 2013;5(13):316-20.
5. Belis JA, Post GJ, Rochman SC, Milam DF. Genitourinary leiomyomas. *Urol* 1979;13(4):424-9.
6. Borri A, Nesi G, Bencini L, Pernice LM. Bizarre leiomyoma of the epididymis. A case report. *Minerva Urol Nefrol* 2000;52(1):29-31.
7. Rosen Y, Ambiavagar PC, Vuletin JC, Macchia RJ. Atypical leiomyoma of prostate. *Urol* 1980;15(2):183-5.
8. Redman JF, Liang X, Ferguson MA, Savell VH. Leiomyoma of the glans penis in a child. *J Urol* 2000;164(3):791.
9. Chiong E, Tan KB, Siew E, Rajwanshi A, See H, Esuvaranathan K. Uncommon benign intrascrotal tumours. *Ann Acad Med Singapore* 2004;33:351.
10. Newman PL, Fletcher CD. Smooth tumours of the external genitalia: Clinicopathological analysis of a series. *Histopathol* 1991;18(6):523-9.
11. Sherwani RK, Rahman K, Akhtar K, Zaheer S, Hassan MJ, Haider A. Leiomyoma of scrotum. *Ind J Pathol Microbiol* 2008;51(1):72-3.
12. Chang SG, Lee SC, Park YK, Chai SE. Pedunculated leiomyoma of Scrotum. *J Kor Med Sci* 1991;6(3):284-6.

13. Rao S, Fimate P, Ramakrishnan R, Rajendiran S. Atypical Leiomyoma of Scrotum. *J Cutan Aesthet Surg* 2012;5(3):216-7.
14. Ragsdale BD. Tumours with fatty, muscular, osseous tissue and/ or cartilaginous differentiation. In: Elder

DE, Elenitsas R, Johnson BL, Murphy GF, Xu G, editors. *Lever's Histopathology of the Skin*. 10th edition. Philadelphia: Lippincott Williams & Wilkins; 2009. p. 1080.