

Case Report

Unilateral Tuberculous Epididymo- Orchitis with Scrotal Fistula: a Case Report

Hadiseh Hosamirudsari¹, Farzaneh Mohammadizia²

1. *Infectious Diseases Clinic, Baharloo Hospital, Tehran University of Medical Sciences, Tehran, Iran*
2. *Dept. of Pathology, Baharloo Hospital, Tehran University of Medical Sciences, Tehran, Iran*

ABSTRACT

Tuberculosis (TB) global prevalence remains almost unchanged over the past few decades. Though genitourinary tract tuberculosis is common, it is rarely associated with scrotal fistula. We present a rare case of advanced tuberculous epididymo-orchitis (TBEO) which culminated in removing the testis. Before final diagnosis is made, it was unresponsive to empirical therapy of bacterial epididymo-orchitis. The approaches to this case were clinical, radiological and histopatologic. For treatment and follow up see the case report.

Keywords: Epididymitis, Orchitis, Fistula, Tuberculosis

Introduction

Tuberculosis as an infectious disease is caused by the bacillus *Mycobacterium tuberculosis*. It affects about one third of the world population (1). TB prevalence is 33 per 100000 population in Iran (2). More than 20% of cases demonstrate extra pulmonary manifestation (3). Genitourinary TB, including tuberculous epididymo-orchitis (TBEO) is the second most common type of extra pulmonary tuberculosis

(4). In almost 28% of the genitourinary TB cases, which itself accounts for 30% of nonpulmonary tuberculosis (5), merely the genitalia is involved (6).

Eighty five percent of the epididymal lesions are believed to be secondary to the prostate infection developed by urine released from renal tuberculosis (7). It is likely that TB bacilli settlement on the epididymis occurs during hematogenous spread from a primary source (8). The present case report is a TBEO with scrotal fistula without any trace of TB elsewhere in the

Received: 07 Jan 2014

Accepted: 31 May 2014

Address Communications to: Dr. Hadiseh Hosamirudsari, Infectious Diseases Clinic, Baharloo Hospital, Behdari st., Railway Sq., Tehran, Iran.

Email: hhrudsari@yahoo.com

body. The importance of this case is unilateral advanced involvement (epididymis, testis, scrotal wall) without clinical involvement of other testis.

Case Report

In April 2010, a 28 years old Afgan man presented with left painless testicular swelling and ipsilateral scrotal ulcer with discharge from two months earlier. He had been married and had two children. The patient had no medical history of tuberculosis, although he suffered from fever, sweating, weakness and unexplained weight loss since the start of symptoms. He had no respiratory symptoms, dysuria, frequency, nausea and vomiting. The patient was treated as epididymo-orchitis with doxycyclin, ceftriaxon, erythromycin, spectinomycin without any response. On physical examination there was swelling of left testis without any pain, erythema and warmth. Furthermore on the left scrotal wall there was a fistula tract with slight serous discharge. The other physical examinations were otherwise unremarkable. Routine blood tests including hemoglobin, WBC counts and liver function tests were in the normal limits and post op ESR has been 20 mm/h. Chest radiography and abdomino-pelvic CT-scan have not been compatible with disseminated TB infection; this might imply the absence of a primary site. Smear of scrotal fistula discharge for acid fast bacilli, was negative. Because the prolonged orchitis has been refractory to ordinary medical treatment, this patient underwent left orchiectomy. The specimen was consisted of a large testis with intact and congested capsule, white- cream – yellow and purplish in color measuring 8.5× 5 ×4.5 cm. The cut surfaces from testis revealed vas deferens measuring 3.5 cm in length and 0.3 in width. This testis was divided into three well defined lobes separated by prominent gray colored thin septae. The middle lobe measuring 3.5 cm in diameter showed many prominent, separated cream –yellow colored granules in background of necrotic tissue and adjacent to

orange colored testicular tissue. The latter was infiltrated by these granules.

Microscopic examinations showed granulomatous orchitis with involvement of epididymis and even wall of vas deferens and caseous granulomas in subcutaneous tissues of scrotum (Fig. 1). Special staining on tissue fragment has failed.

Post-surgical operation, the patient was treated with a combination therapy of isoniazid, rifampin, ethambutol, pyrazinamid and pyridoxin (2 months with 4 drugs and 4 months with 2 drugs). Two mornings urine samples for *Mycobacterium tuberculosis* were positive after six weeks. In six months , 1 year and 2 years period of follow up, he had no complains.

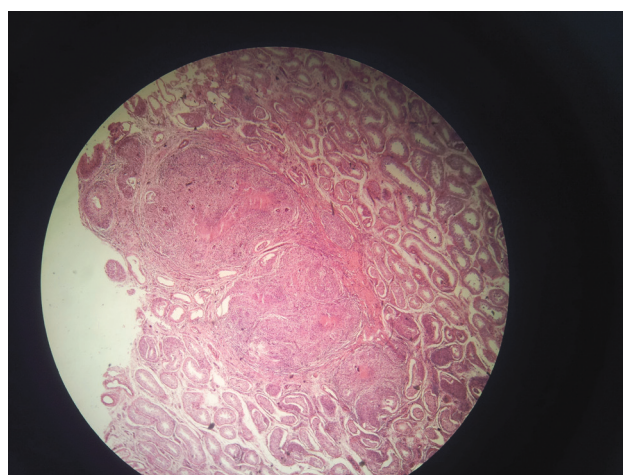


Fig.1: Surgical pathology of patient with male genital tuberculosis. Granulomatous inflammation with langhans giant cell in testicular parenchymal tissue. The three white horizontal arrows point to granuloma. The large black arrow points to caseouse necrosis. The small black arrow points to seminiferous tubule. The vertical white arrow points to multinucleated Giant cells of Langhan's type. (H& E, ×10)

Discussion

TBEO is common in the age group of 20 to 50 years old (9). Its diagnosis is usually confirmed by isolation of *M. tuberculosis* from urine or seminal fluid (10), however tissue samples and histological examinations support diagnosis (11). Nowadays PCR is alternatively used for detection

of *M. tuberculosis* (12). Diagnosis of TB merely based on smear of urine sample and imaging studies, may be difficult (12, 13). Swelling and tenderness of scrotum pointed to the likelihood of bacterial epididymo-orchitis and malignancy. Histopathology and culture would also help distinguish bacterial epididymo-orchitis and malignancy from TBEO (8).

The most common sites of involvement in order of occurrence rate are epididymis, prostate, seminal vesicles and testis (14, 3). In two case studies on male genital tuberculosis, almost 62% (15) and 64 % (16) of patients were diagnosed as renal tuberculosis alongside with TBEO. Another study on TBEO patients found out that in nearly 80% of cases, extra genital organs are involved (17). Detailed chest X-ray investigation has also suggested that 69% of TBEO patients had pulmonary tuberculosis (16). In our case, scrotal wall was also involved (Fig. 1) that suggested advanced, extensive genital disease (9). Despite involvement of left epididymis, testis and left scrotal wall, the right side was not clinically involved. The present case therefore, might be considered as a rare unilateral TBEO. A comparison of the present case with a review study on 34 cases of TBEO (16), revealed similarities in scrotal swelling, pain and urine positive culture for *M. tuberculosis* without any pyuria, however the major difference of the present case is the absence of concomitant tuberculosis in other organs.

Patients with TBEO have milder symptoms than pyogenic epididymo-orchitis so that they would visit physician later and sometimes in more advanced stages of diseases. The importance of the presented case is in two points: one is the lack of any evidence of involvement of other organs in chest X ray and abdomino-pelvic CT scan and the other, is absence of any evidence for TB in other side of genitalia. Patients with mild symptoms of epididymo-orchitis should be considered as likely cases of tuberculosis, especially those from endemic area and those

who have risk factors such as HIV infection and other immunosuppressive conditions.

Acknowledgements

Valuable comments provided by the editor and the anonymous reviewers have significantly improved this manuscript and are highly appreciated. The authors declare that there is no conflict of interests.

References

1. Shugaba AI, Rabiou AM, Uzokwe C, Matthew RM. Tuberculosis of the testis: A case report. *Clin Med Insight: Case Rep.* 2012; 5: 169–172.
2. WHO. Tuberculosis profile of Iran. 2014. Available from: <http://www.who.int/tb/data>.
3. Madeb R, Marshal J, Nativ O, Erturk E. Epididymal Tuberculosis: case report and review of the literature. *Urology* 2005; 65(4):798.e22-4.
4. Kapoor R, Ansari MS, Mandhani A, Gulia A. Clinical presentation and diagnostic approach in cases of genitourinary tuberculosis. *Indian J Urol* 2008; 24(3): 401–405.
5. Wise GJ, Venkata KM. Genitourinary manifestation of tuberculosis. *Urol Clin N Am* 2003; 30(1):111-21.
6. Shah H, Shah K, Dixit R, Shah KV. Isolated Tuberculous epididymo-orchitis. *Indian J Tuberc* 2004; 51: 159-62.
7. Veenema RJ, Lattimer JK. Genital tuberculosis in the male: clinical pathology and effect on fertility. *J Urol* 1957; 78(1):65-77.
8. Yu-Hung Lai A, Lu SH, Yu HJ, Kuo YC, Huang CY. Tuberculous epididymitis presenting as huge scrotal tumor. *Urology* 2009; 73(5): 1163e5-7.
9. Heaton ND, Hogan B, Michell M, Thompson P, Yates-Bell AJ. Tuberculous epididymo-orchitis: clinical and ultrasound observations. *Br J Urol* 1989; 64(3):305-9.
10. Center for Disease Control and Prevention. Nucleic acid amplification tests for tuberculosis. *Morb Mortal Wkly Rep* 1996; 45: 950-2.
11. Ferrie BG, Rundle JS. Tuberculous epididymo-or-

chitis. A review of 20 cases. Br J Urol 1983;55(4):437-9.

12. Cos LR, Cockett AT. Genitourinary tuberculosis revisited. Urology 1982; 20(2): 111-7.

13. Daher EDF, da Silva Junior GB, Pinherino HCF, de Oliveria TR, Vilar MDLL, de Alcantara KJ. Erythema induratum of Bazin and renal Tuberculosis; report of association. Rev Inst Med Trop S Paulo. 2004; 46(5): 295-8.

14. Oben FT, Wright RD, Ahaghotu CA. Tuberculous epididymitis with extensive retroperitoneal and mediastinal involvement. Urology 2004; 64(1): 156-8.

15. Kulchavenya E, Khomyakov V. Male genital tuberculosis in Siberians. World J Urol 2006; 24(1):74-8.

16. Garcia IG, Mampaso EG, Revilla JB, Molina MR, Crespo AS, Buitrago LA, *et al.* Tuberculous Orchiepididymitis during 1978- 2003 Period: Review of 34 Cases and Role of 16SrRNA Amplification. Urology 2010; 76(4):776-81.

17. Wolf JS, McAnich JW. Tuberculous epididymo-orchitis: diagnosis of fine needle aspiration. J Urol 1991; 50(3):243-9.