

Case Report

Adenosquamous Carcinoma Of Stomach: A Case Report

Indranil Chakrabarti, Anuradha De A, Kaushik Majumdar, Amita Giri

Dept. of Pathology, North Bengal Medical College, Sushrutanagar, West Bengal, India

ABSTRACT

Adenosquamous carcinomas of stomach are rare entities comprising 0.5% of stomach carcinomas. Here, we report a case of a 50-year-old female, who presented with weakness, pallor, and symptoms of gastric outlet obstruction. A partial gastrectomy was done and histology showed evidence of adenosquamous carcinoma of the antrum with metastasis to the perigastric lymph nodes. The patient condition improved at 6-month follow-up.

Keywords: Adenosquamous carcinoma, Stomach, Metastasis, Lymph node

Introduction

Adenosquamous carcinoma and pure squamous cell carcinomas occurring in stomach are rare entities, which generate considerable interest because these are tumors of cells, which are different from the cells found in the normal organ. According to the literature, the incidence of these tumors collectively varies between 0.04 and 0.7% with a male: female ratio of approximately 4:1(1). Most of the reported cases have occurred in Japan and similar reports are sparse in other parts of the world. Usually these tumors involve the antrum and consist of varying proportions of adenocarcinoma and squamous cell carcinomas. The origin of these tumors has been of considerable debate.

Case Report

A 50 year-old woman presented with pallor, weakness, anorexia, and abdominal pain in the epigastric region of 4-month duration. This was accompanied by presence of vomiting after intake of food for the last couple of weeks. She underwent a complete hemogram, which revealed a hemoglobin percentage of 6.8 gm/dl and a microcytic, hypochromic anemia. The WBC and the platelet counts were unremarkable.

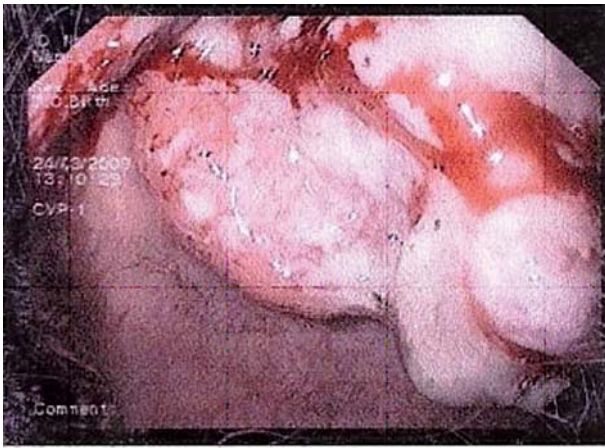
An upper GI endoscopy revealed a proliferative growth in the antrum of the stomach involving the pylorus leading to gastric outlet obstruction (Fig.1). The fundus and body were filled with liquid contents and the gastro-esophageal junction was competent. Multiple biopsies were taken from the various areas of the growth.

Received: 14 October 2009

Accepted: 16 December 2009

Address communications to: Dr Indranil Chakrabarti, Department of Pathology, North Bengal Medical College, Sushrutanagar, Darjeeling, West Bengal, India

Email: drinch@rediffmail.com



ANTRUM, GROWTH

Fig. 1: Endoscopy showed a proliferative growth in the antrum

Histopathology revealed an intestinal type of adenocarcinoma. Partial gastrectomy was done

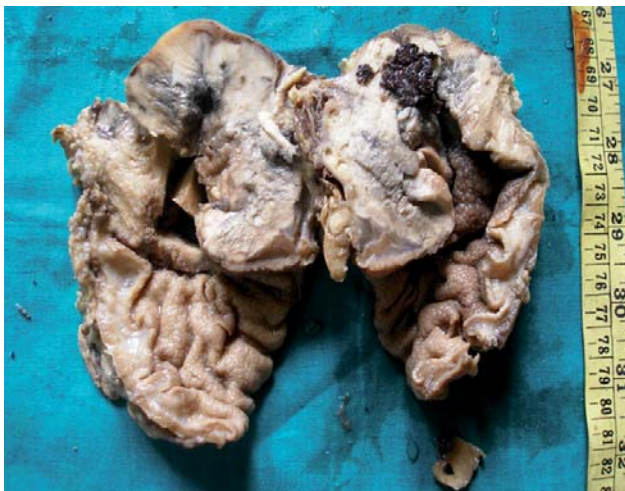

Fig. 2: Grossly a proliferative growth in the antrum and pylorus was seen

Histologically, the gastric tumor consisted of a mixture of adenocarcinoma (40% in area) and squamous cell carcinoma (60% in area). The squamous cell carcinoma was well differentiated with foci of necrosis and formation of small keratin pearls (Fig. 3).

and the specimen was sent for histopathological examination.

A pre-operative abdominal CT scan was done which showed some enlarged perigastric lymph nodes in addition to the growth in the antrum but no evidence of metastasis in liver, peritoneum was detected.

Gross examination of the specimen revealed a Borrmann Type I growth measuring 7.5cm X 6.5 cm X 2.5 cm and involving the antrum as well as the pylorus of the stomach. The cut section showed mostly solid areas with small glistening areas and foci of hemorrhage (Fig. 2). Ten perigastric lymph nodes were sent along with, the largest measuring 2.5 X 2 cm. Tissue blocks taken from representative areas and all the ten lymph nodes were processed by the standard histopathological procedure. The sections were stained by Hematoxylin and Eosin stains.

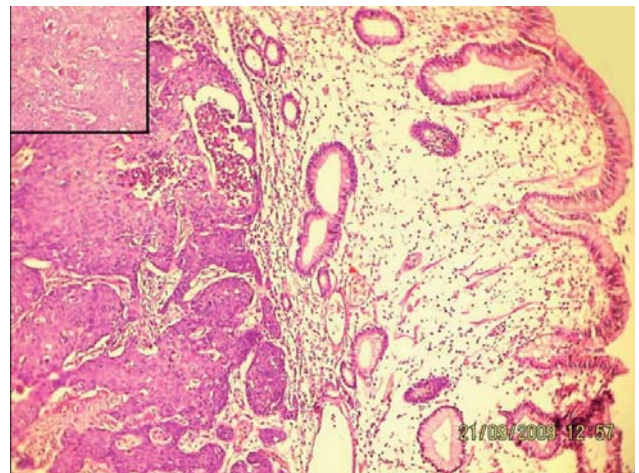


Fig. 3: Microphotograph showing normal gastric mucosa with underlying well differentiated squamous cell carcinoma with areas of necrosis. (Hematoxylin and Eosin stain, 100X magnification) Inset shows presence of squamous pearls. (Hematoxylin and Eosin stain, 400X magnification)

The adenocarcinoma was of intestinal type with malignant cells forming glandular structures and areas of extra cellular mucin. There was a gradual transition between adenocarcinoma and squamous cell carcinoma. The tumor cells invaded up to the serosa. There was a focus of poorly differentiated adenocarcinoma composed of small sized, hyperchromatic cells (Fig. 4).

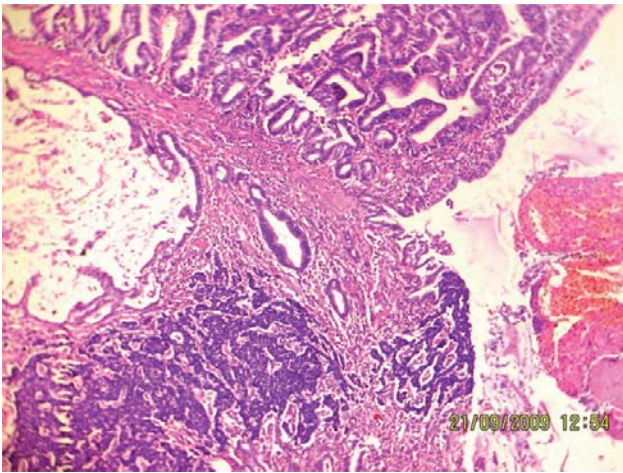


Fig. 4: Microphotograph showing well differentiated adenocarcinoma with areas of extracellular mucin and a foci of poorly differentiated carcinoma composed of small, hyperchromatic cells. (Hematoxylin and Eosin stain, 100× magnification)

Five of the ten perigastric lymph nodes showed metastases of adenocarcinoma with no evidence of squamous cell carcinoma. One of the lymph nodes showed perinodal spread (Fig. 5).

Discussion

Adenosquamous carcinomas of stomach are rare entities with some studies showing the incidence of 0.5% of gastric carcinomas (2). These tumors show evidence of admixed adenocarcinoma and squamous cell carcinoma with gradual transformation of one into the other. Cases with sharp demarcation between the two malignancies are referred to as collision tumors. Toyota *et al.* (2) reported a case of adenosquamous carcinoma of the stomach associated with separate early gastric cancer (type IIc). Most of the reported cases of adenosquamous carcinomas have been from Japan where there is high incidence of gastric carcinomas. Similar cases of adenosquamous carcinomas with lymph node metastasis have been reported by Shigematsu *et al.*(3) Although reported to be more common in men, our patient was a female who presented with symptoms of gastric outlet obstruction. In most of the cases reported by Masuda *et al.*(4) and Terada (5), the adenocarcinoma

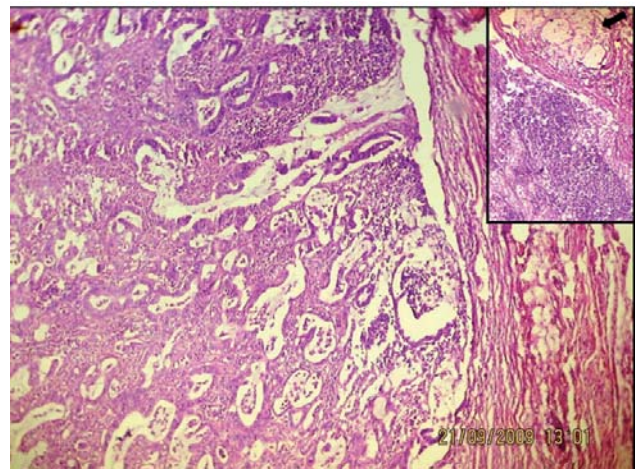


Fig. 5: Section from one involved lymph node showing deposits of mucin producing well differentiated adenocarcinoma . Inset shows perinodal spread (arrow).(Hematoxylin and Eosin stain, 100X magnification)

The patient condition improved at 6-month follow up with no evidence of distant metastasis.

components were poorly differentiated. In our case, however, the adenocomponent was that of a well-differentiated intestinal type of adenocarcinoma with extra-cellular mucin production.

Adenosquamous carcinomas are known to follow a very aggressive clinical course with metastasis in the other abdominal organs like liver, gallbladder, lymph nodes, peritoneum etc. while the present case showed involvement of the perigastric lymph nodes only.

It is very interesting that the present case showed metastases of adenocarcinoma in the lymph node but not squamous cell carcinoma. Similar observation was also noted by Terada (5) who inferred that it seems that the biologic behaviors may be determined by adenocarcinoma element in adenosquamous carcinoma of the stomach (5). If that holds true then the degree of differentiation of the adenocarcinoma component may have important prognostic implications as well. The origin of adenosquamous carcinoma has been a matter of speculation for quite

sometime with Mori *et al.* (6, 7) considering that adenosquamous carcinoma is derived from squamous transdifferentiation of adenocarcinoma cells and Mingzzini *et al.* (8) believing that adenosquamous carcinoma of the stomach are derived from totipotential undifferentiated cells of the stomach. However, this remains an open issue and further studies are required to ascertain the histogenesis and pathogenesis of these tumors.

Acknowledgements

We are thankful to Dr. Nilanjana Ghosh for her help in preparing the manuscript. The authors declare that they have no conflicts of interest.

References

1. Straus R, Heschel S, Fortmann DJ. Primary adenosquamous carcinoma of the stomach. A case report and review. *Cancer* 1969;24(5):985-95.
2. Toyota N, Minagi S, Takeuchi T, Sadamitsu N. Adenosquamous carcinoma of the stomach associated with separate early gastric cancer (type IIc). *J Gastroenterol* 1996;31(1):105-8.
3. Shigematsu T, Nakamura K, Fukui K, Morita H, Samejima Y, Goto T, *et al.* A primary gastric adenosquamous carcinoma with remarkable lymphatic metastasis diagnosed by the stomach and lymph node biopsy. *Gan No Rinsho* 1989;35(3):421-6.
4. Masuda T, Kizaki M, Akaiwa Y, Kamiya T, Suzuki O, Okawa H, *et al.* A case of primary adenosquamous carcinoma of the stomach preoperatively diagnosed by endoscopic biopsy. *Gan No Rinsho* 1985;31(2):212-6.
5. Terada T. Adenosquamous Carcinoma of the Stomach: Report of Two Cases. *Gastroenterol Res* 2009;2(1):54-6.
6. Mori M, Fukuda T, Enjoji M. Adenosquamous carcinoma of the stomach. Histogenetic and ultrastructural studies. *Gastroenterology* 1987;92(4):1078-82.
7. Mori M, Iwashita A, Enjoji M. Adenosquamous carcinoma of the stomach. A clinicopathologic analysis of 28 cases. *Cancer* 1986;57(2):333-9.
8. Mingazzini PL, Barsotti P, Malchiodi AF. Adenosquamous carcinoma of the stomach: histological, histochemical and ultrastructural observations. *Histopathology* 1983;7(3):433-43.