

# Case Report

## Breast Metastasis of Ovarian Carcinoma

*Dhaneshor Sharma<sup>1</sup>, Tomcha Singh<sup>1</sup>, Rajesh Singh Laishram<sup>2</sup>, Ranjit Singh<sup>3</sup>*

*1. Dept. of Radiotherapy, Regional Institute of Medical Sciences, Lamphelpat, Imphal, India*

*2. Dept. of Pathology, Regional Institute of Medical Sciences, Lamphelpat, Imphal, India*

*3. Dept. of Obstetrics & Gynecology, Regional Institute of Medical Sciences, Lamphelpat, Imphal, India*

### ABSTRACT

Breast metastasis of ovarian carcinoma is rare. To date, only 39 cases have been reported in the English-language literature so far. We are herewith reporting a primary ovarian papillary serous cystadenocarcinoma metastasizing to breast and ipsilateral supraclavicular node in a 58 year old female as the first case in our centre, located at North-East India. The purpose of reporting this case is to emphasize the need of examining breasts in patients of ovarian cancer and the need to exercise meticulous care to exclude second primary at breast from possible secondaries at breast from ovarian cancer.

**Keywords:** Breast, Metastasis, Ovary Cancer

---

### Introduction

The management of ovarian carcinoma has changed recently with improved survival due to better screening strategies, major advances in chemotherapy and the constantly evolving role of surgery. Rare distant metastases are observed in liver, lung, bone, and brain due to improvement in overall survival. Even, isolated brain metastasis was reported in a patient of ovarian carcinoma (1).

However, breast metastasis due to ovarian carcinoma is rare (2-4). To date, only 39 cases were reported in the English-language literature (5).

We present this case of breast metastasis of ovarian cancer in view of rarity, paramount importance in early diagnosis, poor prognosis and to avoid unnecessary major surgery except palliative mastectomy in this systemic disease.

*Received: 22 July 2010*

*Accepted: 21 October 2010*

*Address communications to:*

*Corresponding author's address: Dr. Rajesh Singh Laishram, Department of Pathology, Regional Institute of Medical Sciences, Lamphelpat, Imphal, Manipur State, India*

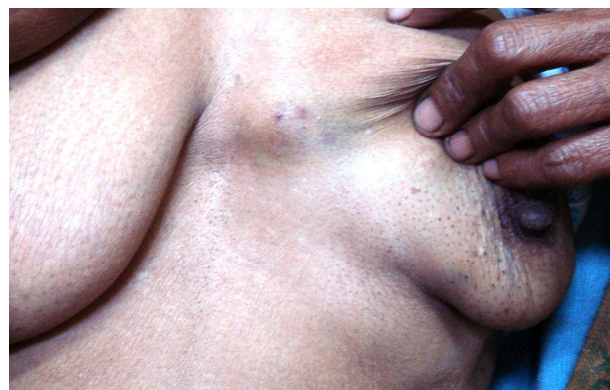*E mail: rajeshlaishr@gmail.com*

## Case History

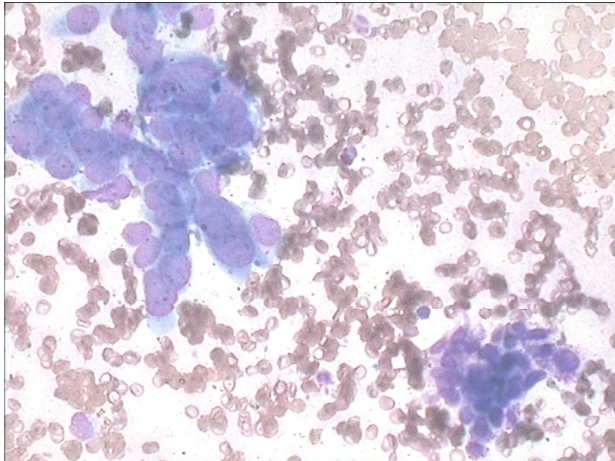
A 58-year-old female, old treated case of papillary serous cyst adenocarcinoma of ovary in stage III b was reported to our department with the complaints of a hard nodule at her left breast for the last 1 month. She underwent a total abdominal hysterectomy with bilateral salpingoophorectomy, omentectomy, and periaortic lymphadenectomy, 19 months back followed by 8 cycles of chemotherapeutic regimen consisting of intravenous cisplatin and Taxol. After 8 cycles of chemotherapy, she underwent a CT scan of the chest, abdomen, and pelvis including serum CA-125 estimation and all of them being reported normal study. Patient refused second look surgery and she was kept on two monthly follow up. At last follow-up, February 2010, almost 11 months after her initial ovarian cancer diagnosis, all vital signs were normal, and physical examination revealed a rounded nodule at inner lower quadrant of left breast, sized 4x3 cm (Fig. 1). Nodule was hard and partially fixed to underlying chest wall and it was nontender. Axillary nodes were not palpable but ipsilateral supraclavicular node was palpable, nontender, hard, sized 1x0.5cm. The rest of her general and systemic examinations revealed no abnormalities.

Her complete haemogram, kidney function test, liver function test, and blood sugar level were within normal limits. The serum CA-125 level was raised (289.6U/ml, normal range being less than 35.0 U/ml) and serum CA 15-3 level was within normal limit. Chest x-ray, CT scan (whole abdomen) revealed no abnormalities. Fine needle aspiration cytology (FNAC) of the breast nodule (Fig. 2) and the ipsilateral supraclavicular node (Fig. 3) showed presence of papillary aggregates of malignant glandular cells. The malignant cells were mostly columnar cells with relatively high nuclear cyto-

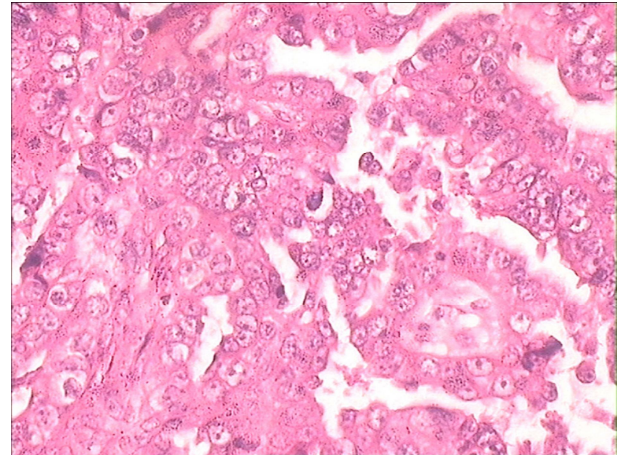
plasmic ratio with scanty cytoplasm. The nuclei were hyperchromatic with irregularly distributed coarse chromatin and inconspicuous nucleoli. A diagnosis of metastatic papillary serous cystadenocarcinoma was made, as the findings were same as the histopathological findings (Fig. 4) with that of the biopsy report of previous cytoreductive surgery. Multiple sections studied showed tumor composed of complex, branching papillae lined by variably stratified, eosinophilic, cuboid to low columnar cells often forming micropapillae. Areas of solid growth with irregularly infiltrating glands are also seen. Psammoma bodies were also noted (Fig. 5). Primary lesions of the breast was ruled out as the patient had no other lumps and the cytomorphology of the aspirates were not conforming to any of the primary tumor of the breast. Moreover, axillas were free of any adenopathy. The previous history of being operated for ovarian tumor was one of the most important finding. The patient's general condition was good. Surgery was not possible due to disseminated disease and patient was put on taxal-based palliative chemotherapy (combination of Paclitaxel and Cisplatin every 3 weeks for six cycles. So far, patient had received three cycles of chemotherapy and there were 70% reduction in size in respect of the breast and supraclavicular lesions



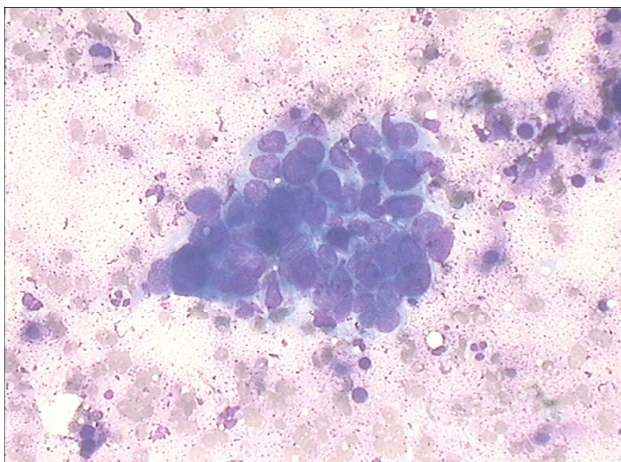
**Fig. 1-** Photograph showing the breast nodule



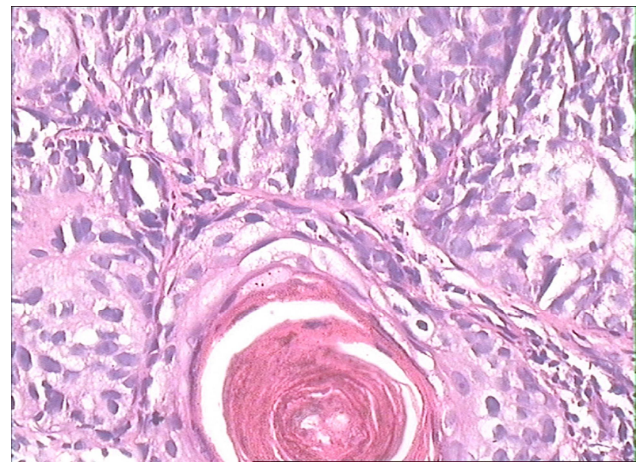
**Fig. 2-** Photomicrograph of FNA smear from supraclavicular node showing the metastatic cells (MGG stain)



**Fig. 4-** Photomicrograph showing papillary serous cyst adenocarcinoma of ovary (X100 H.E Stain)



**Fig. 3-** Photomicrograph of FNA smear showing metastatic deposits in breast (MGG stain)



**Fig. 5-** Photomicrograph showing psammoma body in papillary serous cyst adenocarcinoma of ovary (X400 H.E Stain)

## Discussion

Epithelial ovarian cancers spread mainly by direct extension, by exfoliation of clonogenic cells and by lymphatic spread to adjacent lymph node. Distant metastasis via blood route is uncommon but more frequently seen in patients who have survived for some years. Distant metastasis ultimately develops in 38% of patients who originally had intraperitoneal disease (6). Most patients with disease above the diaphragm have a right pleural effusion

Vol.6, No. 3, Summer 2011

(7). Hadju and Urban already reported an overall incidence of primary gynaecologic cancers metastatic to the breast of 0.17%, with only 0.07% of metastatic disease originating from a primary ovarian tumor (8). At presentation, 85% of breast metastasis was solitary tumors, only 4% of cases had diffused involvement, and in 62% of cases, metastases were found at upper outer quadrant of breast (8, 9). Metastasis usually develops after a

short period of treatment of primary tumor with an average duration of three years (10). In our case, metastasis developed 19 months later after cytoreductive operation and treatment. Type of ovarian cancer metastasizing to breast and lymph node were mostly of papillary serous cyst adenoma. Metastasis to breast (11) and axillary lymph nodes were reported in the literature (8).

Prognosis of ovarian metastasis to the breast confers a poor prognosis; most patients usually die within one year after the detection of metastatic breast tumor (12). Isolated breast metastasis may mimic primary breast carcinomas. Prognosis and treatment options are different in both breast carcinomas and breast metastasis, thereby lays the paramount importance of early diagnosis to differentiate them. Imaging, immunohistochemistry, and pathology can help in confirming the diagnosis. Recently survival rates are increasing with new effective chemotherapeutics in cases of ovarian carcinoma; this rare metastasis will be observed more frequently and should be treated as a systemic disease with appropriate chemotherapeutic agents. Our case showed that such breast metastasis could be still sensitive to cisplatin and taxol combination chemotherapy regimen. Those cases unresponsive to systemic therapy, mastectomy could be kept as an option for palliative care.

## References

1. Sanderson A, Bonington SC, Carrington BM, *et al.* Cerebral metastasis and other cerebral events in women with ovarian cancer. *Clin Radiol* 2002;57(9):815-9.
2. Balaji R, Ramachandran K, Anila KR. Ovarian carcinoma metastasis to the breast and imaging features with histopathologic correlation: a case report and review of the literature. *Clin Breast Cancer* 2009 ;9(3):196-8.
3. Barai S, Kumar R, Haloi AK, Dhanpati, Banopadhyaya G, Malhotra A. Bone scan demonstrating metastasis to the breast from an ovarian carcinoma and a review of the literature. *Clin Nucl Med* 2004;29(3):167-70.
4. Cormio G, di VG, Melilli GA, Loverro G, Cramarossa D, Selvaggi L. Ovarian carcinoma metastatic to the breast. *Gynecol Obstet Invest* 2001;52(1):73-4.
5. Dauplat J, Hacker NF, Nieberg RK, Berek JS, Rose TP, Sagae S. Distant metastases in epithelial ovarian carcinoma. *Cancer* 1987; 1;60(7):1561-6.
6. Julian CG, Goss J, Blanchard K, Woodruff JD. Biologic behavior of primary ovarian malignancy. *Obstet Gynecol* 1974 ;44(6):873-84.
7. Baykal C, Tulunay G, Ozfuttu A, *et al.* Breast and Ovarian Carcinoma in the Same Patient, Metastasis or Dual Primaries. *Turkish J Cancer* 2007;37(1):27-30.
8. Moore DH, Wilson DK, Hurteau JA, Look KY, Stehman FB, Sutton GP. Gynecologic cancers metastatic to the breast. *J Am Coll Surg* 1998;187(2):178-81.
9. Kayikcioglu F, Boran N, Ayhan A, Guler N. Inflammatory breast metastases of ovarian cancer: a case report. *Gynecol Oncol* 2001;83(3):613-6.
10. Pavithran K, Prabhash K, Hazarika D, Doval DC. Neuroendocrine carcinoma of gallbladder: report of 2 cases. *Hepatobiliary Pancreat Dis Int* 2005;4(1):144-6.
11. Ozmen V, Asoglu O, Karanlik H, Cabioglu N, Kecer M, Bakkaloglu H. Primary ovarian cancer presenting with axillary lymph node metastases: a report of two cases. *Acta Chir Belg* 2007;107(1):75-7.
12. Brown Iii JV, Epstein HD, Kim R. Rapid manifestation of CNS metastatic disease in a cervical carcinoma patient: a case report. *Oncology* 2007;73(3-4):273-6.