

Case Report

Primary Cutaneous Leiomyosarcoma in a Young Patient Previously Misdiagnosed as Pleomorphic Fibroma

Fariba Abbasi^{1,2}, Rahim Mahmudlu³, Yasaman Nikniaz², Makan Rezaie²

1. Solid Tumor Research Center, Urmia University
of Medical Sciences, Urmia, Iran

2. Dept. of Pathology, Faculty of Medicine, Urmia University
of Medical Sciences, Urmia, Iran

3. Dept. of Surgery, Faculty of Medicine, Urmia University
of Medical Sciences, Urmia, Iran

ABSTRACT

Cutaneous leiomyosarcoma is a relatively rare tumor accounts for about 2-3% of superficial soft tissue sarcomas. It occurs more frequently in males in fifth and sixth decades with a predilection for extremities. We report a 27 years old male with cutaneous leiomyosarcoma of thigh, previously diagnosed as pleomorphic fibroma. The tumor composed of pleomorphic spindle shaped cells with blunt ended nuclei and high mitotic activity. Smooth muscle actin was positive. In this case, the young age of the patient and previous misdiagnosis of the tumor are interesting. Subtle histologic features of low grade leiomyosarcoma can be a pitfall in diagnosis and so affects the optimal management of the patient as it occurred in previous sample of this case.

Keywords: Leiomyosarcoma, Skin, Iran

Introduction

Leiomyosarcoma is a rare malignant tumor of smooth muscle origin accounts for approximately 7% of all soft tissue sarcomas (1). Primary cutaneous leiomyosarcoma (PCL) is extremely rare, constitutes almost 2-3% of all superficial soft tissue sarcomas (2, 3). This

tumor mostly involves males between 40-60 years of age (1). The preferred site of involvement is limbs (1,3).

The tumor may be well to poorly differentiated, nodular or diffuse (4). The minimal criteria for malignancy are cellularity, some amount of atypia, and a few mitoses (4). Lesser differentiated areas show numerous anaplastic nuclei and atypical

Received: 17 September 2013

Accepted: 24 January 2014

Address Communications to: Dr. Fariba Abbasi, Department of pathology, Faculty of Medicine, Urmia University of Medical Sciences, Urmia, Iran.

Email: faribaak2002@yahoo.com

giant cells with bizarre nuclei (4). The histologic features especially in well differentiated types may be subtle (1,5). In these cases distinction from a benign lesion can be problematic (2,5).

Local recurrence and metastasis may be seen in cutaneous leiomyosarcoma (6). The treatment of choice is radical surgical excision (6). Tumor excision without adequate safe margin may result in recurrence with higher tendency to involvement of deeper structures and more aggressiveness than the primary one (6).

We would like to stress on interesting aspects of the presented case which are the young age of the patient, previous misdiagnosis as a benign lesion and also incomplete excision of that tumor resulted in recurrence with appearance of the tumor showing higher grade of differentiation.

Case Presentation

The patient was a 27 years old man who admitted with thigh mass at the site of previous excised tumor 2 years ago. At that time the histopathologic diagnosis was pleomorphic fibroma. The patient did not receive any other treatment and he was in good condition. Since a few months ago, a new mass appeared at the site of previous tumor and gradually enlarged. Routine laboratory tests were normal. The patient went under excision of the tumor. The specimen received in pathology laboratory composed of an ellipse of skin measuring 7×4×2 cm with an elevated ulcerated mass of 2.5 cm in diameter, located at 0.5 cm distance from the nearest margin. Cut surface of the tumor was white with some darkish discoloration.

Microscopic examination showed ulcerated skin tissue with dermal located tumor composed of spindle shaped cells with elongated or oval, moderately pleomorphic blunt ended nuclei arranged in interlacing fascicles and whorl pattern (Fig.1). Mitotic Figures (13-14/10HPF), some giant mononuclear and multinuclear tumoral cells, hya-

linization, necrosis (less than 50% of the examined tumor surface) were present (Fig.2, 3). The tumor involved entire thickness of the dermis and invaded into the subcutaneous fat. Immunohistochemistry (IHC) staining was negative for S-100 protein and CD34 and positive for SMA (Fig.4). These features were consistent with the diagnosis of leiomyosarcoma, grade 2 according to French Federation of Cancer Centers Sarcoma Group grading system. Surgical margins were intact. The patient referred to the Oncology Center for optimal treatment.

We reviewed the histopathologic slides of the previous sample precisely. The tumor composed of subepithelial proliferation of spindle shaped cells with little amount of pleomorphism and only 2 mitoses per 10 HPF arranged in interlacing fascicles (Fig.5). No tumoral giant cells and no necrosis were present. Surgical margins were involved. The paraffin embedded blocks of the sample retrieved from the archive and stained by SMA and desmin (which were not stained previously). Both markers showed reactivity (Fig.6). These features were consistent with LMS, grade 1, and not pleomorphic fibroma.

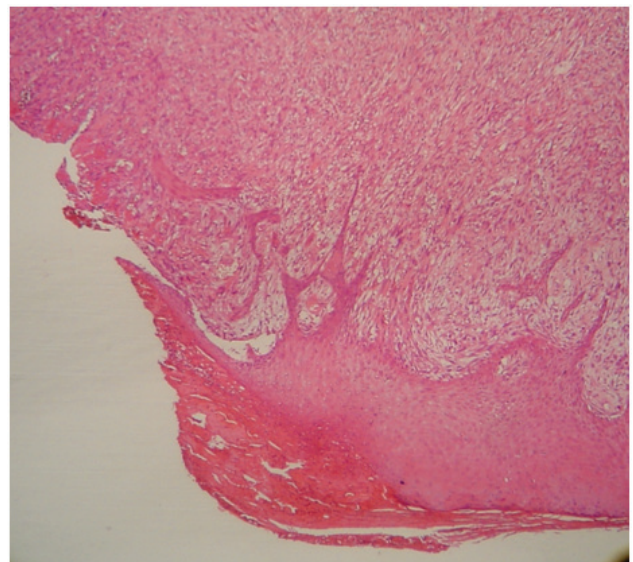


Fig.1: The dermal located tumor comprised of fascicles of pleomorphic spindle cells with cigar-shaped nuclei (×100)

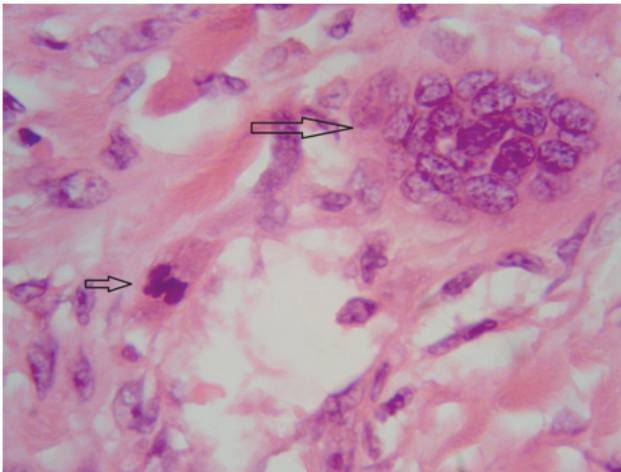


Fig.2: The tumor show nuclear pleomorphism with tumoral giant cells (large arrow) and mitosis (small arrow) in cutaneous leiomyosarcoma ($\times 400$)

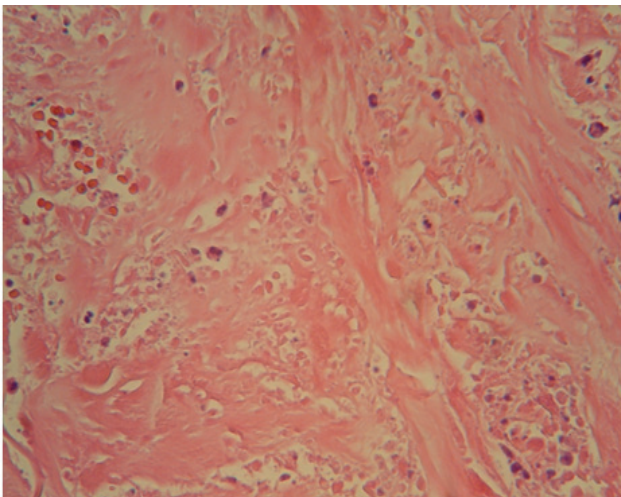


Fig. 3: Necrosis in cutaneous leiomyosarcoma ($\times 400$)

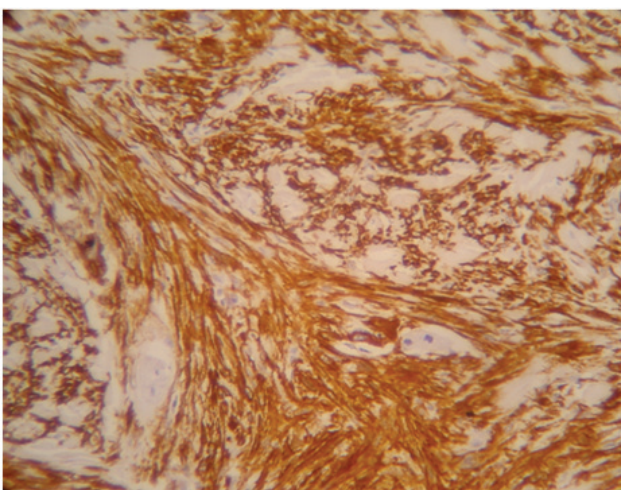


Fig.4: Cutaneous leiomyosarcoma: The tumoral cells show strong positivity for smooth muscle actin ($\times 400$)

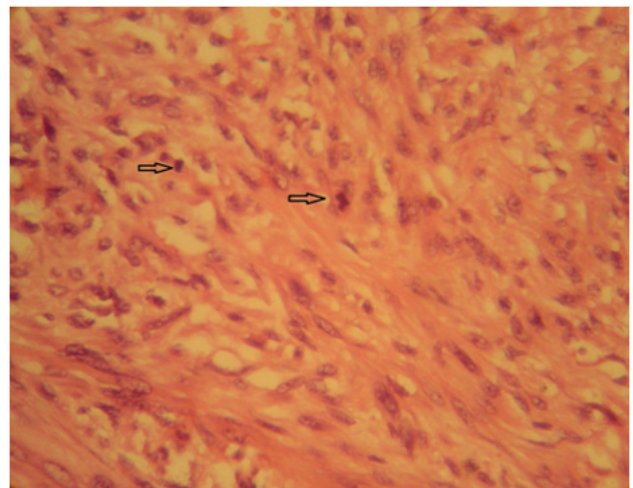


Fig.5: Previous sample (reported as pleomorphic fibroma): The tumor composed of mildly pleomorphic spindle shape cells with mitosis (arrows) ($\times 400$)

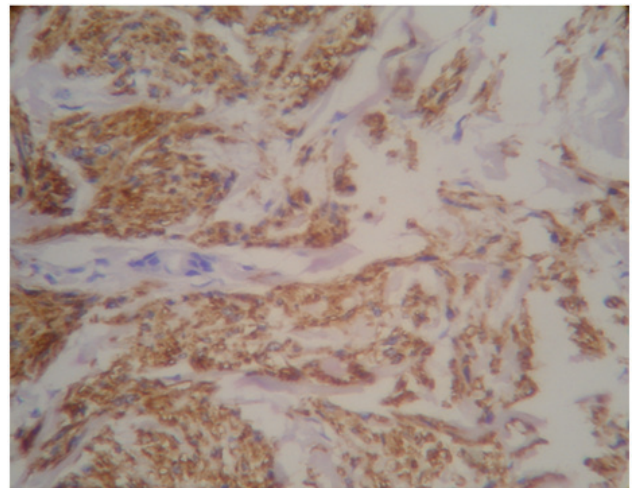


Fig.6: Previous sample (reported as pleomorphic fibroma): Tumoral cells show diffuse strong positivity for desmin ($\times 400$)

Discussion

Primary cutaneous leiomyosarcoma (PCL) is a rare soft tissue tumor accounts for about 2-3% of all superficial soft tissue sarcomas (1,2). This tumor affects males more than females and occurs mostly between 40-60 years of age (1). The presented patient was male, too but he was only 27 years old. The tumor exhibits a predilection for the limbs (3). PCL divided into superficial dermal and deep subcutaneous types. The dermal type is thought to arise from the arrector pili

muscle and subcutaneous type from the smooth muscle of the vessels(2).

Clinically, PCL presents as a single nodule measuring less than 2 centimeter (4). It may be painful or tender but ulceration is seen only rarely (4).The dermal tumors frequently showing adherence to the skin while subcutaneous types are mobile (7).In our case, the tumor was small, too(2.5cm) but with skin ulceration. In some cases, several nodules are present; in such cases metastasis should be suspected (4).

The pattern of growth may be nodular or diffuse (5). According to the study of Kaddu *et al.* (8), nodular tumors show high cellularity, prominent nuclear atypia, many mitosis and necrosis. By contrast, most tumors with diffuse growth pattern revealed low cellularity, well differentiated smooth muscle cells, inconspicuous mitosis and few or no necrotic cells (8). They conclude that tumors with diffuse growth pattern may constitute a pitfall in histologic diagnosis because of the presence of only subtle criteria for malignancy (8). In this presented case the growth pattern was diffuse but there was frank pleomorphism, relatively high mitotic rate(13-14/10HPF) and also necrosis.Immunohistochemically, muscle actin is positive in virtually all tumors, although desmin stained positively in 66% of cutaneous leiomyosarcomas (2).

The local recurrence is seen in almost 30% of dermal cases and in subcutaneous variants in about 50% and in around 30% of these patients metastasis occurs (6).Our case is a dermal type and showed recurrence after 2 years.

In this case, misdiagnosis was occurred 2 years ago. Pleomorphic fibroma usually appears as polypoid lesion and consists of coarse collagen bundles with sparse cells. Marked atypia and also multinucleated giant cells is seen but mitosis is not present (9). In our case, the first sample was not polypoid. Besides,there is no frank atypia and no multinucleated giant cells, but mitotic activity (2/10 HPF) is present. Pleomorphic fibroma shows no reactivity for desmin but desmin

staining is diffusely positive in previous sample of the patient (10). Based on these features, the diagnosis of pleomorphic fibroma could not be correct. Mentioned histologic features and especially IHC staining result consisted with the diagnosis of low grade leiomyosarcoma. It should be noted that histologic features of the first sample were really subtle, resulted in a misdiagnosis. We would like to stress that as Limaïem *et al.* mentioned in their study (2), such subtle histologic features can be a pitfall and may be misinterpreted as benign proliferation. Such misinterpretation was done about first sample of our patient.

The treatment of choice for dermal leiomyosarcoma is radical excision with free lateral margins measuring between 3-5 cm including subcutaneous tissue reaching the fascia (5).In our patient, complete excision of the tumor with free surgical margins was done and the patient referred to oncology team for optimal treatment.

Acknowledgment

This study was supported by Urmia University of Medical Sciences. We are grateful to Mr. Ali Jafari, technician of pathology for his assistance in processing and staining the samples. The authors declare that there is no conflict of interests.

References

- 1 .Karakatsani SA, Nikolidakis A, Tsavdaris G, Hotzoglou N, Krokos N, Kamas A. Cutaneous leiomyosarcoma of the scalp. A case report and short review. *Hellen J Surg* 2012;84 (5): 324-6.
- 2 .Limaïem F, Chally I, Bellil S, Mekni A, Nidhameddine K, Haouet S, et al. Primary cutaneous leiomyosarcoma: a histological and immunohistochemical study of 4 cases. *Egypt Dermatol Online J* 2007;3(1):3.
- 3 .Pol RA, Dannenberg H, Robertus JL, Ginkel RJV. Cutaneous leiomyosarcoma arising in a smallpox scar. *World J Surg Oncol* 2012;10:148.
4. Elder DE, Elenitsas R, Johnson BL, Murphy GF,

- Xu X. *Lever's Histopathology Of The Skin*. 10th ed. Philadelphia: Lippincott Williams & Wilkins; 2009.
5. Massi D, Franchi A, Alos L, Cook M, Di Palma S, Enguita AB, *etal.* Primary cutaneous leiomyosarcoma: clinicopathological analysis of 36 cases. *Histopathology* 2010;56(2):251-62.
6. Andre MC, Antunes JV, Reis MD, Fillipe PL, Almeida LMS. Cutaneous leiomyosarcoma on the trunk. *An Bras Dermatol* 2011;86(5): 999-1002.
7. Agale SV, Grover S, Zode R, Hande S. Primary Cutaneous Leiomyosarcoma. *Indian J Dermatol* 2011;56(6):728-30.
- 8 .Kaddu s, Beham A, Cerroni L, Humer- Fuchs U, Salmhofer W, Keri H. Cutaneous leiomyosarcoma. *Am J SurgPathol* 1997;21(9):979-87.
- 9 .Yadav YK, kushwaha R, Sharma U, Gupta K. Cytomorphology of pleomorphic fibroma of skin: A diagnostic enigma. *JCytol* 2013;30(1):71-3.
- 10 . Goldblum JR, Folpe AL, Weiss SW. *Enzinger& Weiss Soft Tissue Tumors*. 6th ed. Philadelphia: Saunders; 2014.