

Case Report

Infantile Inflammatory Myofibroblastic Tumor with Terminal Ileum Obstruction

Hadiseh Zakeridana¹, Ali Naderi², Ahmad Ahangaran³, Shahriar Dabiri¹

1. Dept. of Pathology, Kerman University of Medical Sciences, Kerman, Iran

2. Dept. of Pediatrics Oncology, Kerman University of Medical Sciences, Kerman, Iran

3. Dept. of Pediatric Surgery, Kerman University of Medical Sciences, Kerman, Iran

ABSTRACT

Inflammatory myofibroblastic tumor is an uncommon benign neoplasm and its presentation in small bowel is rare. Due to clinical manifestation, laboratory data and radiologic results, there is an increased risk of over diagnosis as malignant tumors particularly malignant lymphoma in childhood therefore may be resulting in wrong therapeutic approach. However pathologic findings could be demonstrated definite diagnosis based on markedly proliferation of bland looking spindle cells which their presence can be confirmed by immunohistochemistry staining to show myofibroblastic differentiation. We describe here an unusual presentation of inflammatory myofibroblastic tumor of the terminal ileum in a 19-month-old girl who presented with anemia, eosinophilia, intestinal obstruction, focal ossification and dystrophic calcification within the tumor.

Keyword: Abdominal Tumour, Inflammation, Myofibroblast

Introduction

Inflammatory myofibroblastic tumor (IMT) is a rare benign lesion. It has a wide range of clinical behavior according to the site of the lesions (1-3). Synonyms that frequently were used in the medical literature are as follows: inflammatory pseudotumor, plasma cell granuloma, plasma cell pseudotumor, xanthomatous pseudotumor, pseudosarcomatous myofibroblastic proliferation, and inflammatory myofibrohistiocytic proliferation (4).

The etiology of IMT is still unknown but development of IMT has been described after

trauma, surgery or infection (5). There have also been some reports regarding the association of IMT with Behcet's disease, Hodgkin's disease or chronic peptic ulcer (6). Although IMT is generally considered to be a benign lesion, there have been reports regarding recurrence, especially in cases of incomplete resection and extrapulmonary lesions, which are large and locally invasive (7).

There is a general agreement that the GI tract lesions are predominantly submucosa and composed of inflammatory plasma cells, histiocytes and lymphocytes in a matrix of

Received: 02 February 2012

Accepted: 17 November 2012

Address of communications to: Dr Shahriar Dabiri, Department of pathology, Afzalipour Medical School, Kerman University of Medical Sciences, Kerman, Iran

Email: dabiri12@yahoo.com

spindle-shaped myofibroblasts (8, 9). They are most commonly confused with sarcomas (10). A review of literature for this rare condition was done to delineate the natural history of this tumor and to do a histological confirmation of its benign nature. Because of the risk of local recurrence, IMT cases should have a long-term follow up. We report here this lesion in a 19-month-old girl with unusual clinical presentation of refractory anemia, intestinal obstruction with severe calcification and ossification.

Case Report

A 19 month-old girl admitted with abdominal distention. She had a chronic anemia (Hb:5.5 mg/dl) for about 3 months ago which was detected and treated symptomatically. Recent presentation was intermittent abdominal distention after feeding and constipation resulted in acute-abdomen presentation.

Other lab data were normal limit in biochemistry, hormone assays but 15% eosinophils in peripheral blood. Abdominal ultrasonography revealed a mass in terminal ileum which was partially obstructed the lumen (Fig. 1).

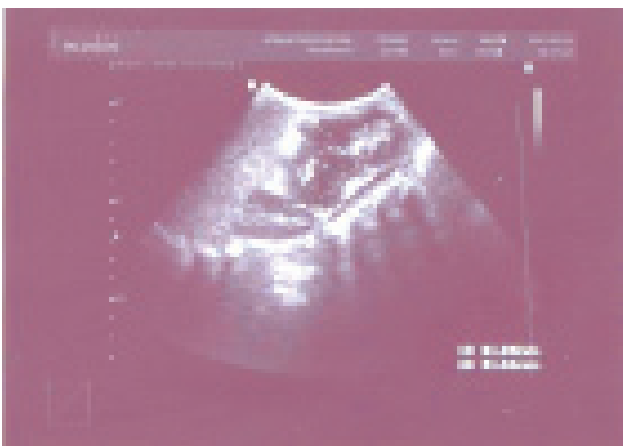


Fig. 1: Ultrasonography showed a mass in terminal ileum which was partially obstructed the lumen.

Total resection of mass was performed and gross examination revealed a well circumscribed firm to hard exo and endophytic creamy-white mass at terminal ileum measuring 9x5x5 cm. Cut surface showed focal bony consistency and whorling appearance (Fig. 2).



Fig. 2: A well formed exo-endophytic mass with homogeneous creamy white surface and focal bony consistency at terminal ileum.

H&E sections showed proliferation of spindle cells with oval to spindle shaped nuclei and eosinophilic to amphophilic cytoplasm which were widely separated and haphazardly distributed among with intercellular collagen. In addition there was mixed inflammatory infiltrate composed of myofibroblasts, histiocytes, lymphocytes, plasma cells and rare eosinophils. Areas of severe calcification were present. There was not any mitoses, atypia or nuclear hyperchromasia (Fig. 3).

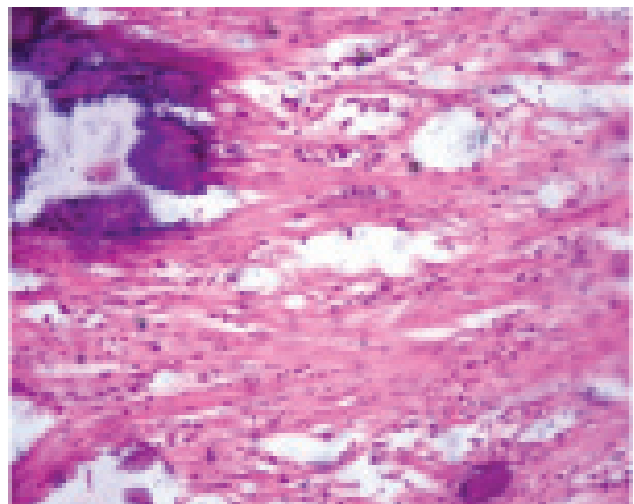


Fig. 3- Proliferation of spindle cells among with intercellular collagen and mixed inflammatory infiltrate with prominent number of eosinophils and plasma cells. Foci of calcification are presented at upper left of the picture (Hematoxylin-Eosin staining, magnification $\times 400$).

Immunohistochemical staining results were as follows: (Fig. 4)

S100: Strongly positive reaction in spindle myofibroblastic cells

SMA: Strongly positive reaction in spindle myofibroblastic cells

Vimentin: Strongly positive reaction in spindle myofibroblastic cells

ALK1: Weakly positive reaction in spindle myofibroblastic cells

CD34: Negative reaction in spindle myofibroblastic cells

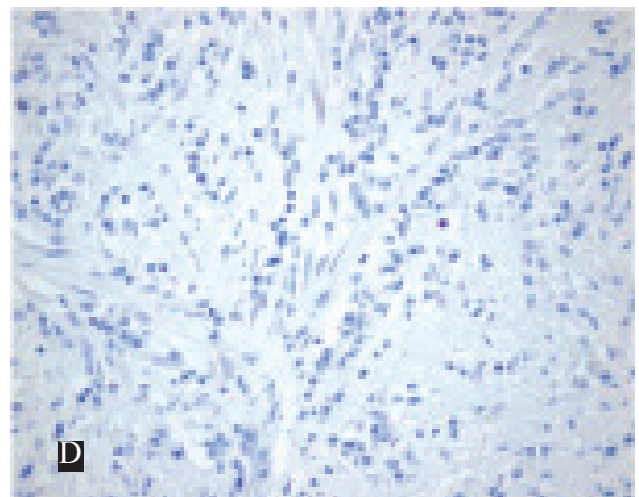
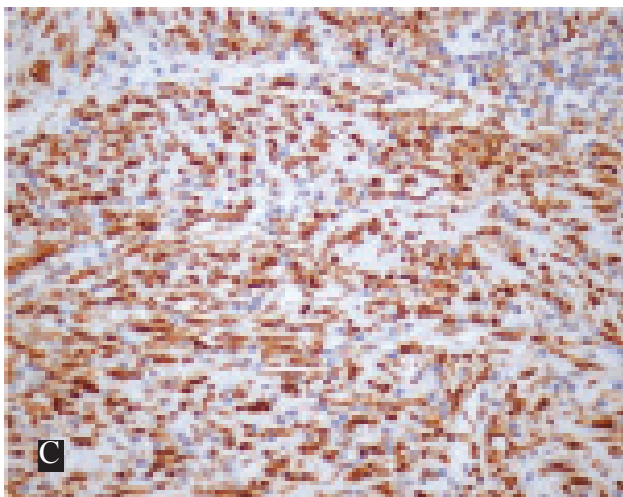
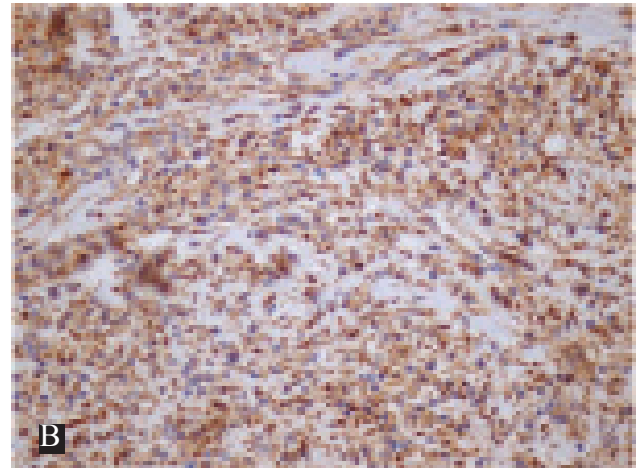
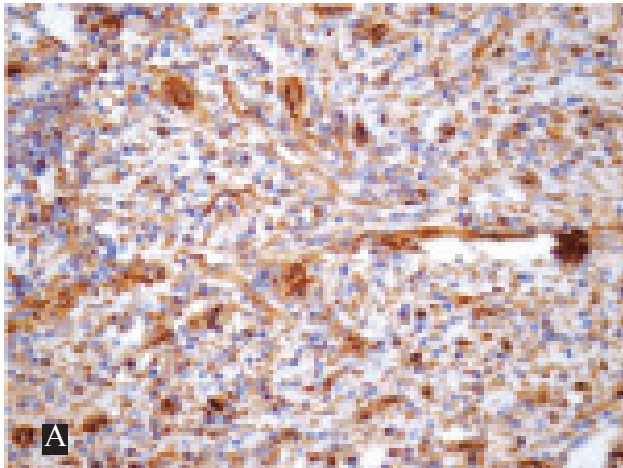
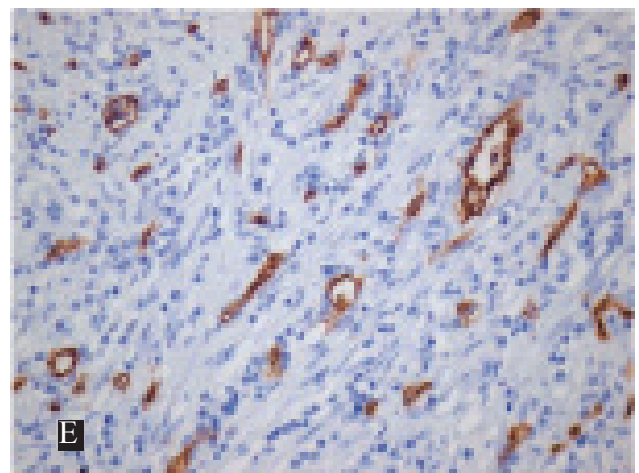


Fig. 4 - (A-E). Immunohistochemical staining. A-C: Showed strongly positive cytoplasmic reaction in spindle myofibroblastic cells in S-100, SMA, Vimentin (magnification $\times 400$). D: Showed weakly positive reaction of nuclei of spindle myofibroblastic cells by ALK1 (magnification $\times 1000$). E: Showed negative cytoplasmic reaction in spindle myofibroblastic cells and positive internal control of vessels (magnification $\times 400$)



Discussion

IMT occurs primarily in children and young adults but can occur at any age (1-3). Mean age of disease is approximately 10 years (11) and infantile cases have also been described (12, 13). Females are affected slightly more commonly than males (14). IMT was originally reported in the lung (15). Extra pulmonary sites including the bronchus, liver, small bowel, mesentery, bladder, kidney, spinal canal, meninges, stomach, pancreas and thyroid have also been reported (16).

Patients with intra-abdominal tumors most commonly presented with abdominal pain and mass with increased girth, or occasionally, with intestinal obstruction (12). Suster reported that some patients might be presented with non specific systemic symptoms as fever and weight loss. Children may also have growth failure. Common abnormalities presented with laboratory tests include an elevated erythrocyte sedimentation rate (ESR), leukocytosis, thrombocytosis, and hypergammaglobulinemia (17). These symptoms and laboratory abnormalities may disappear after surgical intervention and be distinct from those of sclerosing mesenteritis, usually diagnosed in the absence of constitutional symptoms and laboratory abnormalities (18). In our case anemia might be due to secondary effects of malabsorption of hemoglobin biochemical structure precursors or chronic blood loss of slow growing tumor in terminal ileum. Severe calcification and ossification of this entity due to chronicity of lesion had not been reported previously even in two other neonatal cases with abdominal obstruction (19, 20).

IMT shows three major subtypes in histologic appearance: fibromyxoid and vascular pattern, proliferating pattern, and sclerosing patterns. Immunohistochemistry have revealed that spindle cells of these lesions have originally myofibroblastic differentiation (6). The spindle

cells have reaction with antibodies against vimentin, smooth-muscle actin (SMA) and muscle-specific actin. Differential diagnoses of IMT include the gastrointestinal stromal tumor (GIST) and myofibroma for the benign lesion. Myofibroma shows nodular pattern of myoid cells around thin-walled blood vessels. GIST can be excluded by histologic features and positive to CD117 in contrast to IMT. The gastrointestinal autonomic nerve (GAN) tumors are histologically similar to IMT, but they are uniformly negative to muscle-specific actin and CD 68 (21).

Although neoplastic lesions generally have a benign behavior, intra abdominal and retroperitoneal lesions of this type have typically higher local recurrence rates and even more distant metastases (13). Intra- abdominal IMT has a propensity for more aggressive clinical behavior than their extraabdominal counterparts (12). Clonal cytogenetic abnormalities have been demonstrated in some cases (22-24) particularly defined abnormalities on chromosome 2 that result in ALK re-arrangement and is more commonly seen in pediatric than in adult cases (25, 26). Biselli (27) recently found that almost 50% of pediatric extrapulmonary IMT is aneuploid. TP53 mutation and MDM2 amplification are rare (26).

Because of the rarity of this proliferation in the terminal ileum, its natural history and biological potential are still uncertain (13), we reported a case of inflammatory myofibroblastic tumor in uncommon site and unusual clinical presentation with severe calcification and anemia.

IMT could not be distinguished clinically and radiologically from highly malignant neoplasm. The most important diagnostic aid is to bear this entity in mind when a child presents with intestinal obstruction associated with an abdominal mass. Radical surgical procedures or potentially harmful therapy should be avoided, and appropriate treatment is achieved by total excision of the lesion in most of the cases.

Acknowledgement

The authors declare that there is no conflict of interest.

Reference

- Sanders BM, West KW, Gingalewski C, Engums S, Davis M, Grosfeld JL. Inflammatory pseudo-tumor of the alimentary tract: Clinical and surgical experience. *J Pediatr Surg* 2001; 36:169-73.
- Karnak I, Senocak ME, Ciftci AO, Caglar M, Bingol-Kologlu M, Tanyel FC, *et al.* Inflammatory myofibroblastic tumor in children: diagnosis and treatment. *J Pediatr Surg* 2001; 36(6):908-12.
- Kutluk T, Emir S, Karnak I, Gaglar M, Buyukpamukcu M. Mesenteric inflammatory pseudotumor: unusual presentation with leukemoid reaction and massive calcified mass. *J Pediatr Surg* 2002;24(2):158-9.
- Weiss ShW, Goldblum JR. Elzinger and Weiss's soft tissue tumors. 5th ed. Mosby: Philadelphia; 2008.
- Scott L, Blair G, Taylor G, Dimmick J, Fraser G. Inflammatory pseudotumors in children. *J Pediatr Surg* 1988;23(8):755-8.
- Huang CC, Lien HH, Chen DF, Tsai MS. Pediatric intra-abdominal inflammatory myofibroblastic tumor. *Asian J Surg* 2006;29(1):58-61.
- Yung A, Merchant W, Goulden V. A case of isolated cutaneous pseudo-inflammatory tumor. *Dermopathol* 2005; 30(4):369-72.
- Ryan GB, Cliff WJ, Gabbiani G, Irlé C, Montandon D, Statkov PR, *et al.* Myofibroblasts in human granulation tissue. *Hum Pathol* 1974;5(1): 55-67.
- Perrone T, DeWolf-Peeters C, Frizzera G. Inflammatory pseudotumor of lymph nodes: a distinctive pattern of nodal reaction. *Am J Surg Pathol* 1988;12(5):351-61.
- Emory TS, Monihan JM, Carr NJ, Sobin LH. Sclerosing mesenteritis, mesenteric panniculitis and mesenteric lipodystrophy: a single entity? *Am J Surg Pathol* 1997;21(4):392-8.
- Bonyet JP, Basset J, Dijoux D. Abdominal inflammatory myofibroblastic tumors in children. Report of an appendiceal case and a review of the literature. *J Pediatr Surg* 1996; 31(9): 1311-4.
- Riedel BD, Wong RC, Ey EH. Gastric inflammatory myofibroblastic tumor (inflammatory pseudo-tumor) in infancy: case report and review of the literature. *J Pediatr Gastroenterol Nutr* 1994;19(4):437-43.
- Phisek Y, Surachai S, Poonsiri S, Tula D. Inflammatory myofibroblastic tumor of the small intestine: a case report of a 2 month-old infant. *J Med Assoc Thai* 2009;92(1):114-9.
- Donner LR, Trompler RA, White RR. Progression of inflammatory myofibroblastic tumor (inflammatory pseudotumor) of soft tissue into sarcoma after several recurrences. *Hum Pathol* 1996;27(10):1095-8.
- Middleton L, PDuray PH, Merino MJ. The histological spectrum of hemangiopericytoma: application of immunohistochemical analysis including proliferative markers to facilitate diagnosis and predict prognosis. *Hum pathol* 1998;29(6):634-40.
- Trillo AA, Rowden G. The histogenesis of inflammatory fibroid polyps of the gastrointestinal tract. *Histopathol* 1991;19(5):431-6.
- Suster S, Morton JR. Inflammatory fibroid polyp of the small intestine: ultrastructural and immunohistochemical observations. *Ultrast Pathol* 1990;14(2):109-19.
- Coffin CM, Dehner LP, Meis-kindblom JM. Inflammatory myoblastic tumor, inflammatory fibrosarcoma and related lesions. A historical review with differential diagnostic considerations. *Semin Diagn Pathol* 1998;15:102-19.
- Yimyaem P, Saranrittichai S, Sinawat P, Dhiensiri T. Inflammatory myofibroblastic tumor of the small intestine: a case report of a 2 month-old infant. *J Med Assoc Thai* 2009;92(1):114-9.
- Demirkan NC, Akalin T, Yilmaz F, Ozgenc F, Ozcan C, Alkanat MB, *et al.* Inflammatory myofibroblastic tumor of small bowel wall in childhood: Report of a case and a review of the literature. *Pathology International* 2001; 51(1): 47-9.
- Shek TW, Luk IS, Loong F, Ip P, Ma L. Inflammatory cell-rich gastrointestinal autonomic nerve tumor. An expansion of its histologic spectrum. *Am J Surg Pathol*

- 1996;20(3):325-31.
22. Treisman SP, Gillis DA, Lee CL, Giacomantonio M, Resch L. Omental-mesenteric inflammatory pseudotumor. Cytogenetic demonstration of genetic changes and monoclonality in one tumor. *Cancer* 1994;73(5):1433-7.
23. Su LD, Atayde-Perez A, Sheldon S, Fletcher JA, Weiss SW. Inflammatory myofibroblastic tumor: cytogenetic evidence supporting clonal origin. *Mod Pathol* 1998;11(4):364-8.
24. Snyder CS, Dell'Aquila M, Haghghi P, Baergen RN, Suh YK, Yi ES. Clonal changes in inflammatory pseudotumor of the lung: a case report. *Cancer* 1995;76(9):1545-9.
25. Rubin BP, Coffin CM, Fanburg-Smith JC. Inflammatory myofibroblastic tumor in adults. *Mod Pathol* 2003;16:19.
26. Yamamoto H, Oda Y, Saito T, Sakamoto A, Miajima K, Tamiya S, *et al.* P53 mutation and MDM2 amplification in inflammatory myofibroblastic tumors. *Histopathology* 2003;42(5):431-9.
27. Biselli R, Ferlini C, Fattorossi A, Boldrini R, Bosman C. Inflammatory myofibroblastic tumor (inflammatory pseudotumor): DNA flow cytometric analysis of nine pediatric cases. *Cancer* 1996;77:778-84.