

Case Report

Proliferating Pilomatricoma: A Case Report and Review of Literature

Nalini Gupta

Dept. of Histopathology, SRL (Religare) Reference Laboratory, Gurgaon , India

ABSTRACT

Proliferating pilomatricoma is a distinctive rare variant of pilomatricoma first described in 1997. Very few cases of proliferating pilomatricoma have been reported in the literature until date. This report is a case of 65 years old male presenting with hard nodular lump on the right side of neck slowly increasing in size for the last 8 months. Wide excision of the lump was performed with clear surgical margins. Histopathology revealed a tumor mass composed of lobular proliferation of basaloid cells in association with adjacent focal areas containing cornified material with shadow cells. Variable nuclear atypia and scattered mitotic activity was noted in basaloid cells, so a final diagnosis of proliferating pilomatricoma was rendered. This report herein reviews histopathological features of this rare entity.

Keywords: Pilomatricoma, Pathology, India, Case Report

Introduction

Proliferating pilomatricoma is a recently recognized variant of pilomatricoma composed of large solid, solid -cystic basaloid cell areas with small foci of shadow cells (1). They have a greater potential of reoccurrence than usual pilomatricomas (2). Proliferating pilomatricoma is a rare pathological entity with only five cases reports (with 14 cases) in the lit-

erature until date (2-6). These cases needs to be recognized separately because of their potential for reoccurrence than usual pilomatricoma and less malignant potential than other carcinomas including basal cell carcinoma with matrical differentiation and matrical carcinoma and hence the need to publish. This report herein reviews the clinicopathological features, which aids in the diagnosis of this rare entity.

Received: 18 November 2013

Accepted: 03 February 2013

Address Communications to: Dr Nalini Gupta, ,Department of Histopathology SRL Diagnostics, Gurgaon, India.

Email: drnalinibansal@yahoo.com

Case Report

A 65-year-old male presented with hard swelling on right side of neck for past eight months. The swelling was gradually increasing in size. There was no history of trauma at that site. FNAC of the lump was not done. Physical examination revealed a raised dome shaped firm to hard reddish brown nodule measuring 6 × 5 cm. Overlying skin is stretched out. No cervical or other lymph nodes were noted. Wide excision of the lump was done.

Grossly wide excision specimen was received in formalin comprising of skin with subcutaneous tissue. Surface of skin showed a raised nodular growth measuring 6.5×5×4 cm. Serial section of the growth were yellowish white with areas of calcification. The neoplasm was seen 0.2 cm away from the base of resection and well away from other skin and soft tissue margins (Fig. 1).

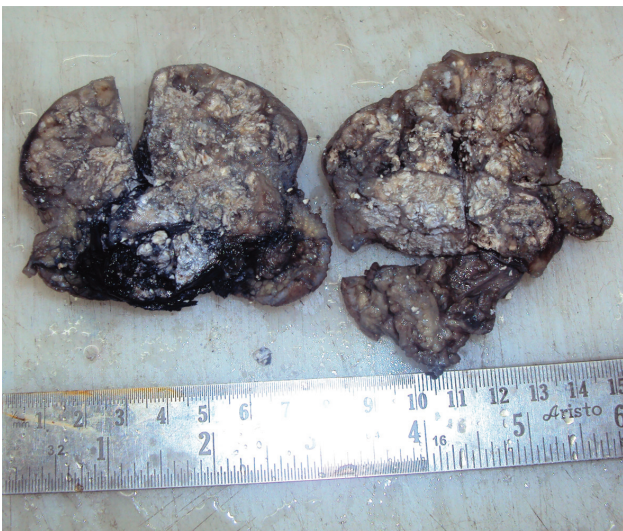

Fig. 1: Gross photograph showing an ill-defined raised nodular mass with grey white cut surface

Histopathological examination showed a neoplasm with solid cystic architecture composed of prominent lobular proliferation of basaloid cells with variable nuclear atypia and scattered mitosis. Areas of shadow cell with foci of calcification noted. No atypical mitotic activity/ marked nuclear pleomorphism noted in basaloid cell. No lymphovascular or perineural invasion identified.

Based on the above histopathological findings a final diagnosis of proliferating pilomatricoma was rendered (Fig 2, 3).

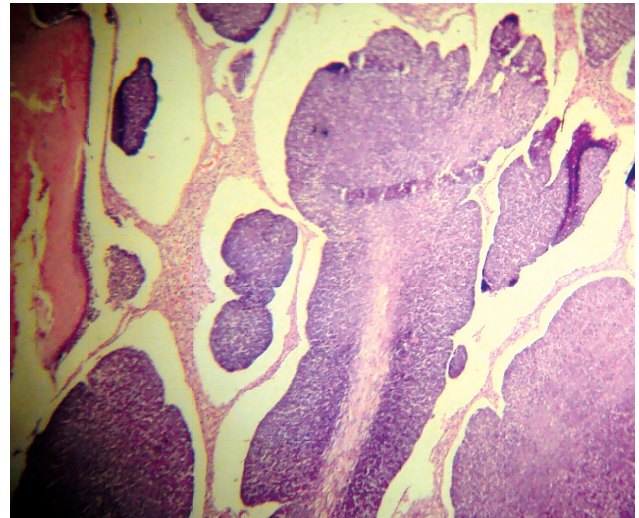


Fig. 2: Micrograph showing marked basaloid cell proliferation. (H&E staining ×400)

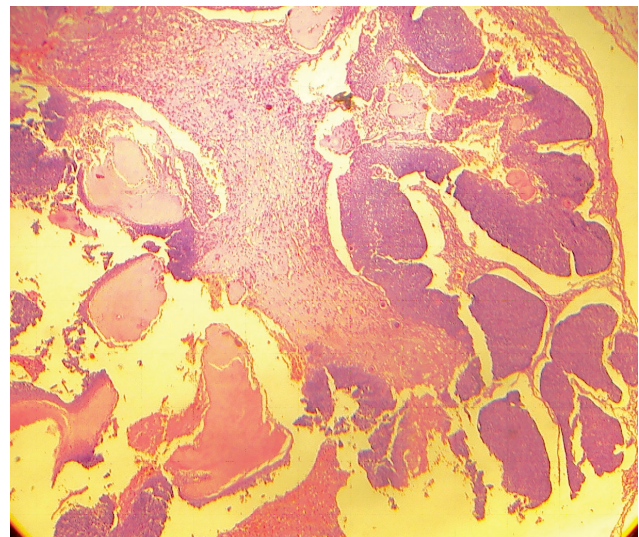


Fig. 3: Micrograph showing shadow cells with basaloid cell proliferation. (H&E staining ×100)

Discussion

Proliferating pilomatricoma is a rare neoplasm first described by Kaddu *et al.* in 1997 as a distinctive histopathological entity characterised by presence of relatively large solid or solid cystic basaloid cell areas with small foci of shadow cells (1, 2).

To the best of our knowledge only 14 patients in 5

reports of proliferating pilomatricoma have been documented in the world literature till date (2- 6). Pilomatricomas are benign adnexal tumours with matrical differentiation and are composed of proliferating basaloid and eosinophilic shadow keratinised cells. The term proliferative pilomatricoma is used when neoplasm is composed of lobular proliferation of basaloid cells with variable nuclear atypia and mitotic figures in addition to shadow cells.

The importance lies in the diagnostic dilemmas that they can pose, as they have been mistaken on various occasions to be matricoma, basal cells carcinoma with matrical differentiation and matrical carcinoma. The silhouette of matricoma differs from proliferating pilomatricoma, with matricoma comprising of predominantly solid basaloid cell proliferation with only focal areas of shadow cells. Cystic areas are not seen (7).

In Basal cell carcinoma with matrical differentiation, the tumor is seen arising from basal layer of the epidermis. Typical features of basal cell carcinoma will also be seen in addition to shadow cells (8).

Matrical carcinoma are characterised by areas of cellular pleomorphism, crowding of cells and numerous mitotic figures including occasional atypical ones (9, 10) .

In a study by kaddu *et al.*, 9 patients were studied most presented with solitary cutaneous nodule on the head and neck (7 patients), upper arm (1 patient) and back (1 patient). All the lesions were treated by simple excision. Follow up was available in 7 of 9 patients and revealed reoccurrence in one patient whose lesion reoccurred 3 times (2). Most cases are reported in the age group of 42-88 years (mean age 66.5 years) with a single case reported in an 18-year-old woman (2-6). All reports have shown that these neoplasms should be excised with adequate surgical margins, and careful follow-up are strongly recommended.

In our case lesion was seen on neck in a 65-year-old male similar to what has been reported earlier. Proliferating pilomatricoma is a rare pathological entity among the hair matrical tumor and awareness of its occurrence is important for the practising pathologist. Detection of this tumor would serve a basis for further research in the pathogenesis and provide a better insight of the clinical behaviour of these rare neoplasms.

Acknowledgement

Mr Sachin Roy, Mr Brijpal Yadav, Mr Samai Singh SSO, JSO and DEO Religare Reference Laboratories Gurgaon are highly appreciated. The authors declare that there is no conflict of interest.

References

1. Boit P, Burg G, Weedon D, Sarasin A. Pathology and Genetics of skin tumors. Lyon:IARC press;2006.
2. Kaddu S, Soyer HP, Wolf IH, Kerl H. Proliferating Pilomatricoma. J Cutan Pathol 1997; 24:228-34.
3. Sakai A, Maruyama Y, Hayashi A. Proliferating Pilomatricoma; a subset of Pilomatricoma. J Plast reconstr Aesthet Surg 2007; 61:811-4.
4. Haque JS, Maheshwari M, Ryatt KS, Abdullah A. Proliferating Pilomatricoma Mimicking Pyogenic Granuloma. J Eur Acad Dermatol 2007;21:688-9.
5. Niiyama S, Amoh Y, Saito N, Takasu H, Katsuoka K. Proliferating Pilomatricoma Europ J of Dermatol 2009;19(2):188-89.
6. Ji-Won B, Chan-Yi B, Bo-Hee Y, Hee-Jin S, Hyeon-Sook L, Jeong-Hyun S, *et al.* Proliferating Pilomatricoma. Am J Dermatopathol 2011;33(7):754-5.
7. Tabbon B, Cerroni L. Where pigmented pilomatricoma and melanocytic matricoma collide. Am J Dermatopathol 2010;32(8):769-73.
8. Sagol O, Ozer E. Basal cell carcinoma of the skin with matrical differentiation, a case report. Eastern J Med 1999;4(1):37-8.
9. Melancon JM, Tom WL, Lee RA, Jackson M, Jiang

SB. Management of Pilomatrix Carcinoma: A Case Report of Successful Treatment with Mohs Micrographic Surgery and Review of the Literature. *Dermatol Sur* 2011;37(12):1798-805.

10. Jeong IS, Oh BS, Kim SJ, Yun CH, Beom MS, Kim DW. Pilomatrix Carcinoma in the Chest Wall around an Eloesser Open Window - A case report. *Korean J Thorac Cardiovasc Surg* 2011;44(3):269-71.