

Case Report

Recurrence of Primary Granulocytic Sarcoma as an Untreatable Scrotal Ulcer

Abazar Akbarzadeh Pasha¹, Sepideh Siadati², Shahriar Shafaei², Mohsen Vakili Sadeghi³

1. Dept. of Urology, Babol University of Medical Sciences, Babol, Iran

2. Dept. of Pathology, Babol University of Medical Sciences, Babol, Iran

3. Dept. of Hematology & Oncology, Babol University of Medical Sciences, Babol, Iran

ABSTRACT

Primary myeloid sarcoma (MS) is a rare tumor and even more rare in multiple organs with no evidence of bone marrow involvement. This report describes an unusual case of a 19-year-old male presenting scrotal MS with a history of subconjunctival MS, 5 months ago. Bone marrow biopsies showed no evidence of acute leukemia. Despite radiotherapy for first involvement and chemotherapy for second presentation, his condition deteriorated and he unfortunately died. This case is presented here to remind an unusual presentation of MS and to address that the pathologist should bear in mind the possibility of MS when making the differential diagnosis of unusual lymphoma or undifferentiated nonhematological tumors.

Keywords: Myeloid Sarcoma, Scrotum, Ulcer

Introduction

Myeloid sarcoma (MS) is a rare extramedullary tumor of myeloid origin (myeloblast or immature myeloid cell) and usually occurs in association with or after the diagnosis of acute myeloid leukemia (AML). It can occur as an evidence of relapse in a known case of AML in remission. This tumor may represent as a blast crisis of chronic myeloid leukemia or as leukemia transformation

in myelodysplastic syndrome (1-8). MS can present in any site but most commonly affects the skin, lymph node, gastrointestinal tract and bone (1-3). Very rarely, MS can occur without bone marrow or peripheral blood involvement as an isolated finding (nonleukemic MS), this is known as "primary MS" and in this situation the diagnosis may be difficult. These patients may develop AML after weeks to months (average 10.5 months) (5, 9-11). More rarely, MS can

Received: 09 Mar 2013

Accepted: 15 Jul 2013

Address Communications to: Dr. Sepideh Siadati, Department of Pathology, Babol University of Medical Sciences, Babol, Iran.

E-mail : siadati_sepideh@yahoo.com

involve the multiple organs.

Case reports about the isolated recurrence of primary MS are rare (12). We describe here a case of primary MS in a 19-year-old male as a relapse of primary subconjunctival MS that presents as a nonhealing genital ulcer.

Case Report

A 19-year-old male with one month history of progressive scrotal and proximal penile skin swelling and ulcer was admitted in urology department of Shahid Beheshti Hospital, Babol, Iran in December 2011. Except fever he did not have any other systemic symptoms. Genital examination showed right scrotal and proximal penile skin edema and erythema accompanied by a large 5 × 3 CM mucopurulent ulcer with well defined, slightly raised borders (Fig.1). He had a history of left subconjunctival mass and underwent surgery and radiotherapy 5 months ago with the diagnosis of primary MS.

In spite of antibiotic therapy and debridement, the ulcer spread and involved the adjacent skin (Fig. 2). Pathologic examination of scrotal biopsy revealed diffuse infiltration of large cells, with round to slightly irregular nuclei, two or four nucleoli consistent with myeloblast. Immunohistochemical (IHC) staining showed a hematopoietic neoplasm (non B cell, non T cell type) that was positive for CD45, S-100, Vimentin, CD 117 (C-Kit) and myeloperoxidase (Fig. 3). AE1/AE3, CD20, CD30, MNF-116 were negative (Fig. 4). Peripheral blood smear, bone marrow aspiration and biopsy were normocellular and negative for evidence of acute leukemia or any type of myeloproliferative disorders.

He was diagnosed as cutaneous MS (Leukemia cutis) and treated with 7+3 standard chemotherapy regimen for AML (Cytarabine and Daunorubicin). After the first course of chemotherapy, the size of the ulcer reduced but the patient's fever continued. Two months later, he was readmitted because of pancytopenia and fever. Repeated

bone marrow aspiration revealed normocellular marrow. A few days later after two doses of G-CSF injection, WBCs increased to 4600/ μ lit and then one day chemotherapy was prescribed. In spite of appropriate supportive care, patient developed severe pancytopenia and expired one week later.

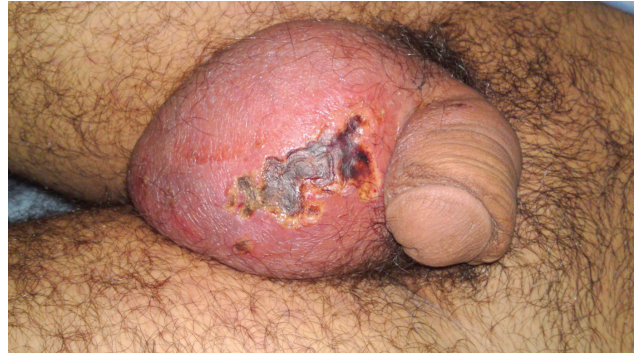

Fig.1: Scrotal ulcer at first presentation

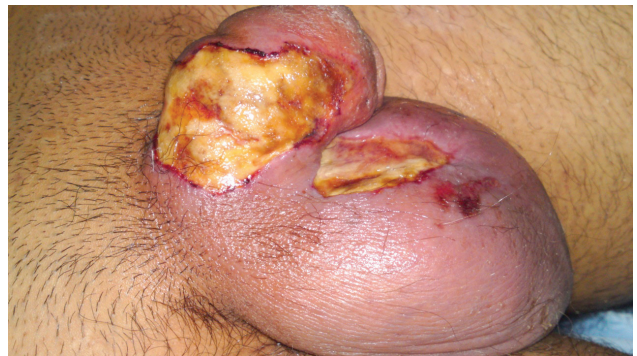

Fig. 2: Extension of scrotal ulcer to penile skin.

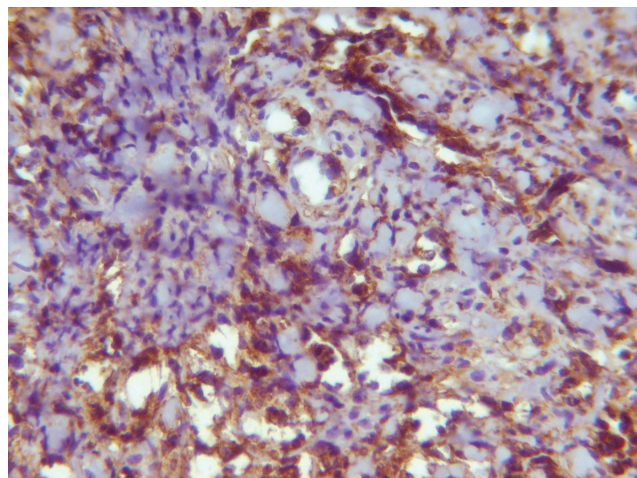


Fig. 3: Positive immunoreaction for myeloperoxidase in tumor cells ($\times 400$)

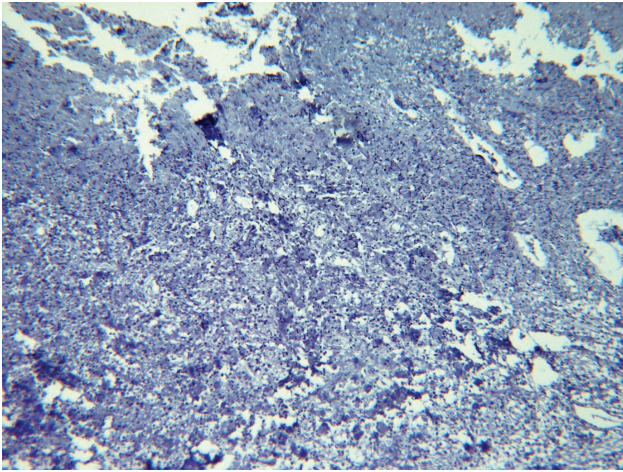


Fig. 4: Negative immunoreaction for AE1/AE3 in tumor cells ($\times 100$)

Discussion

At first, Burns described this tumor in 1811 and the term chloroma was used by King due to green hue made by the myeloperoxidase in tumor cells when the specimen is fresh (1, 13). The association between chloroma and acute leukemia was recognized by Dock and Warthin (14). Because these tumors can have other colors, the term “granulocytic sarcoma” was introduced by Rappaport (13). In recent years, the term “myeloid sarcoma” has been generally accepted.

MS are more frequent in children and young adults and slightly more common in male (15). They occur in approximately 4% to 5% of myeloid leukemia (3). MS with no evidence of leukemia (primary MS) is rare and diagnosis can be difficult and usually misdiagnosed as sarcoma or lymphoma. The most common sites of these nonleukemic MS are the skin, central nervous system, lymph nodes and gastrointestinal tract (7-10). Cutaneous MS (leukemia cutis) represents with infiltration of leukaemia cells in the skin. The term “leukemids” is used for description of nonspecific manifestations of leukemia in the skin (15). Presentation of acute leukemia as isolated skin involvement is rare (16). More rarely, MS can represent in multiple anatomic sites (15).

In our case, involvement of multiple anatomic

sites occurs within 5 months without any evidence of leukemia. Histologically, MS could be seen in various stages of differentiation. Therefore, broad panel of IHC using monoclonal antibodies including MPO, CD34, and CD117 is necessary (1-11). The diagnosis of MS using IHC is not difficult especially with an established history of hematologic disorder but in the absence of peripheral blood or bone marrow involvement (primary cases) misdiagnosis is possible and may cause a diagnostic challenge. Correct diagnosis followed by prompt treatment is mandatory. In our patient, tumor cells were immunohistochemically positive for CD117, vimentin and CD45. B cell and T cell lymphomas were excluded by negative stains for CD3 and CD20. This case is unique because of the involvement of two separate anatomical sites with 5 months interval.

Conclusion

Physicians should be aware of the recurrence of the isolated MS and pay attention to the presence of this entity. Also, urologists should bear in mind the possibility of malignancy when the genital ulcer is unresponsive to conventional drugs and surgical intervention.

Acknowledgements

The authors declare that there is no conflict of interest.

References

1. Benjazia E, Khalifa M, Benabdelkader A, Laatiri A, Braham A, Letaief A, *et al.* Granulocytic sarcoma of the rectum: Report of one case that presented with rectal bleeding. *World J Gastrointest Pathophysiol* 2010 ; 1(4): 144-6.
2. Pileri SA, Ascani S, Cox MC, Campidelli C, Bacci F, Piccioli M, *et al.* Myeloid Sarcoma: clinico - pathologic, phenotypic and cytogenetic analysis of 92 adult patients. *Leukemia* 2007; 21: 340 - 50.
3. Sharma R, Torka P. Painless Lumps: A Manifestation

- of Granulocytic Sarcoma. *Am J Med* 2010;123(10):902-3.
4. Maarkoc F, Bozdogan N, Yukruk FA, Gumuc EB, Akdur NC. Granulocytic sarcomas: difficulties in diagnosis. *Tumori* 2010; 96: 149-53.
 5. Amritanand R, Venkatesh K, Premkumar AJ, Sundararaj GD. pathological dislocation of the dorsal spine following granulocytic sarcoma in a non-leukaemic patient. *Eur Spine J* 2010; 19 (suppl.2) : S114-S7.
 6. Audouin J, comperat E, Le Tourneau A, Camilleri-Broet S, Adida C, Molina T, *et al.* Myeloid sarcoma: clinical and morphologic criteria useful for diagnosis. *Int J Pathol* 2003 ;11(4):271-82.
 7. Hang XF, Xin HG, Wang L, Xu Wsh, Wang Jx, Ni W *et al.* Nonleukemic myeloid sarcoma of the liver: a case report and review of literature. *Hepatol Int* 2011; 5: 747-50.
 8. Quintas - Cardama A, Fraga M, Antunez J, Forteza J. primary extramedullary myeloid tumor of the breast: a case report and review of the literature. *Ann Hematol* 2003; 82:431-4.
 9. Hwang JIK, Kim TY. Primary granulocytic sarcoma of the face. *Ann Dermatol* 2001; 23 (suppl.2): S214-S17.
 10. Shea B, Reddy V, Abbitt P, Benda R, Douglas V, Wingard J. Granulocytic sarcoma (Chloroma) of the breast: A diagnostic dilemma and review of the literature. *The breast J* 2004; 10: 48-53.
 11. Xu Q, wang M, You Q, Wang H, Ye K, Zhan R, *et al.* Isolated recurrence of granulocytic sarcoma. *Neural Med Chir* 2009; 49: 611-5.
 12. Naresh KN, Zokaie S, Madhavan KS, Chzu A. The hammersmith hospital hematopathology case of the month: Myeloid sarcoma with langerhans cell proliferation. *Leuk Lymphoma* 2010; 51(6): 1128-34.
 13. King A. A case of chloroma. *Month J Med* 1853; 17: 97.
 14. Dock G, Warthin AS. A new case of chloroma with leukemia. *Trans Assoc Am Phys* 1904; 19(64): 115.
 15. Cheah KL, Lim LC, Teong HH, Chua SH. A case of generalised cutaneous granulocytic sarcoma in an elderly patient with myelodysplastic syndrome. *Singapore Med J* 2002 : 43(10); 527-9.
 16. Mazzaglia PJ, Strenger R, Castillo JJ. Extramedullary relapse of acute myeloid leukemia in a surgical wound. *Leuk Lymphoma* 2011; 52(3): 541-3.