

Case Report

Primary Malignant Melanoma of the Gastrointestinal Tract: Report of Two Cases

Akbar Safaei¹, Seyed Masood Tabib², Mohamad Reza Farzaneh¹,
Jahanbanoo Shahryari¹, Mohamad Bahmaniar³

1. Dept. of Pathology, Molecular Pathology and Cytogenetic Ward, Shiraz University of
Medical Sciences, Shiraz, Iran

2. Internal ward, Boushehr University of Medical Sciences, Boushehr, Iran

3. Dept. of Pathology, Fatemeh Zahra Hospital, Boushehr University of
Medical Sciences, Boushehr, Iran.

ABSTRACT

Although gastrointestinal involvement by metastatic malignant melanoma is common but primary gastrointestinal (GI) melanoma has been reported in rare cases. In this study we report two cases of primary gastrointestinal malignant melanoma that one of them is a known case of neurofibromatosis type 1(NF1). Both cases showed no evidence of any lesions in skin and eye. Malignant melanoma of GI tract in patient with neurofibroma is reported with hypothesis of a possible relation between two pathologies. Both primary GI melanoma and combination of NF1 with primary GI melanoma are rare entities discussed in this article.

Keywords: Melanoma, Gastrointestinal Tract, Neurofibromatosis

Introduction

Malignant melanoma (MM) is seen mostly in skin and eye but primary MM originating in the internal organs is rare but well documented in the literature. Malignant melanoma is rare and accounts 1-3% of all malignant tumors of the digestive system

(1). Primary MM occurs most often in the skin and much less in the choroid layer of the eyes, under the nail, leptomeninges, nasal mucosa, oropharynx, esophagus, airway mucosa, vagina and anorectal area. Malignant melanoma is the commonest malignancy that metastasizes to internal organs (2, 3). Small intestine in the GI tract is

Received: 30 Mar 2013

Accepted: 18 Oct 2013

Address Communications to: Dr. Mohamad Reza Farzaneh, Fellow of Molecular Pathology and Cytogenetics, Pathology department, Shiraz University of Medical Sciences, Shiraz, Iran.

Email: mrfarzaneh@yahoo.com

the most common site for metastatic malignant melanoma (4).

The differential diagnosis of primary malignant melanoma is quite broad including poorly differentiated carcinoma, gastrointestinal stromal tumor, other malignant mesenchymal tumors, such as leiomyosarcoma and malignant peripheral nerve sheath tumor. Immunohistochemistry can define the expression of classic markers such as vimentin, S-100 protein, HMB-45, Melan-A and tyrosinase in the absence of epithelial, smooth muscles and lymphoid markers (5).

NF1 is one of the most common autosomal dominant transmitted neurocutaneous disorders produced via mutation in gene of neurofibromin protein. The prevalence of NF1 is about 1 in 3500 individuals and affecting the development and growth control of a variety of tissues (6).

Literature review showed very rare reports about relation between MM and NF1(7), so the first case we report is a very rare case of NF1 presented with multiple lesions in GI tract that IHC study showed primary MM.

1st Case Report

A middle age 40 yr old single lady was presented to internist with nonspecific dyspeptic symptom and vague abdominal pain. She was a known case of NF1. Routine laboratory exams were normal except for mild anemia and elevated ESR. Ultrasound study of abdomenopelvic area revealed multiple target lesions in liver suggestive for metastases. Upper GI endoscopy disclosed multiple discrete black dome shaped lesions in stomach, duodenum and jejunum (Fig. 1). These lesions had a 3-10 mm diameter with black hue and some of them had central umbilication. Endoscopic findings were highly suggestive for metastatic involvement of upper GI tract or malignant melanoma.

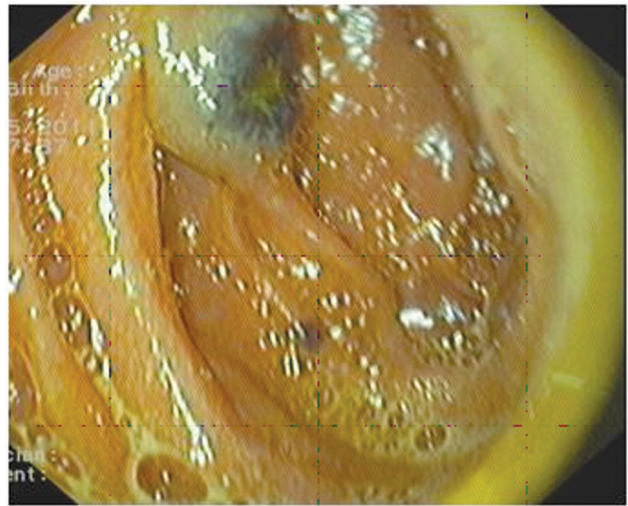


Fig.1: Colonoscopy: A large mass, with black hue originating just at dentate line detected with retroflexion maneuver during colonoscopy (Case 1).

The patient suffered from constipation, straining defecation and minor rectal bleeding for several months. Digital rectal examination revealed a large & hard mass just originating at anorectal junction. Moreover we noted typical finding of neurofibromatosis during her complete physical examination as multiple café-au-lait macules and multiple neurofibroma. We performed full colonoscopy up to cecum and also terminal ileum, which disclosed only a large mass, about 35 x 35 mm in size, with black hue originating just at dentate line (Fig. 2). Her colonoscopic examination was otherwise normal. Careful physical examination of patient did not show any cutaneous or ocular lesions suspicious for melanoma. There was no other tumor elsewhere in the body. She had no history of weight loss, melena, and hematemesis. Histopathology of gastric and colon endoscopic biopsy showed neoplastic cells in a sheet-like growth pattern without glandular differentiation (Fig. 3A, B). S100 protein and HMB-45 antibodies were strongly positive, thus confirming a diagnosis of GI melanoma (Fig. 4A, B, C). According to history, physical examination and pathologic finding diagnosis of advanced primary gastrointestinal malignant melanoma was made.

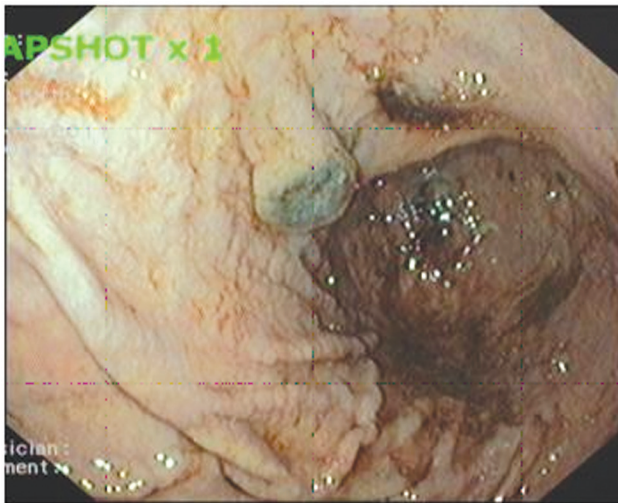


Fig. 2: Gastric endoscopy: Multiple discrete elevated lesions in stomach. These lesions had a 3-10 mm diameter with black hue & some of them had central umbilication (Case 1).

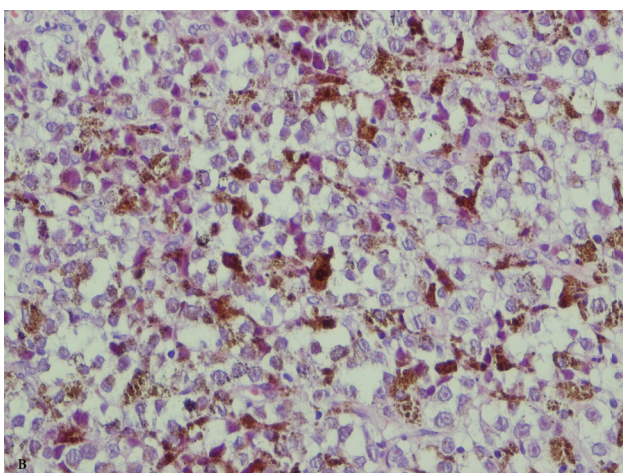
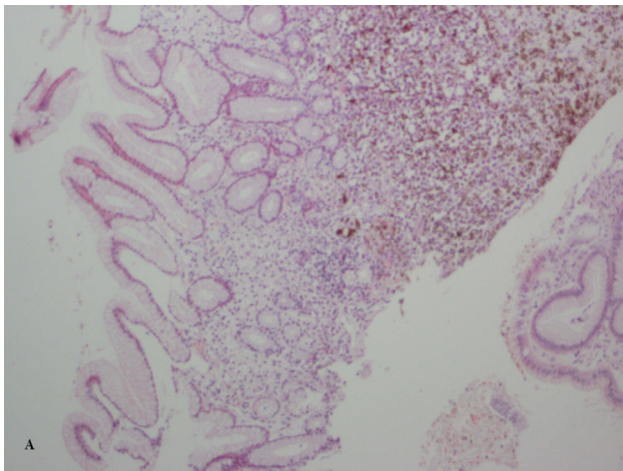


Fig. 3: **A)** Stomach malignant melanoma H&E stain $\times 100$ (Case 1); **B)** Stomach malignant melanoma H&E stain $\times 400$ (Case 1)

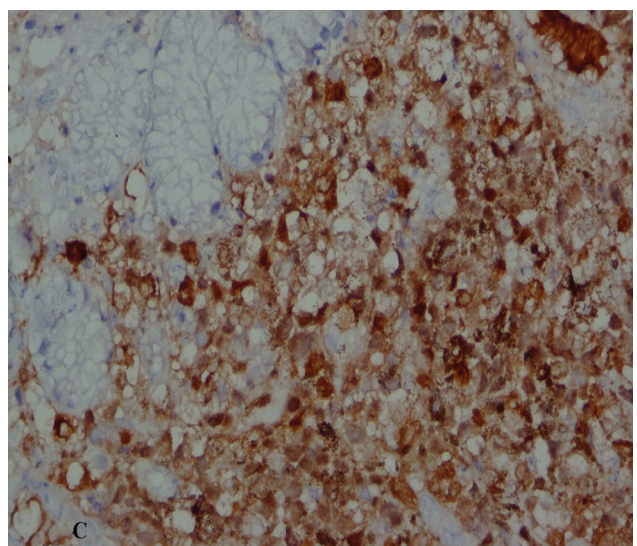
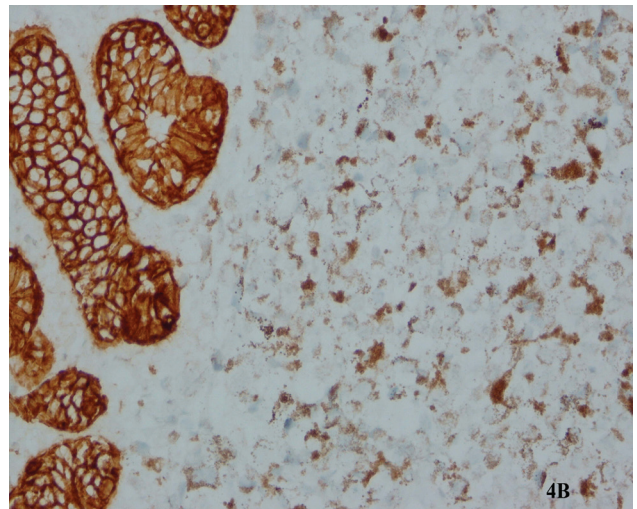
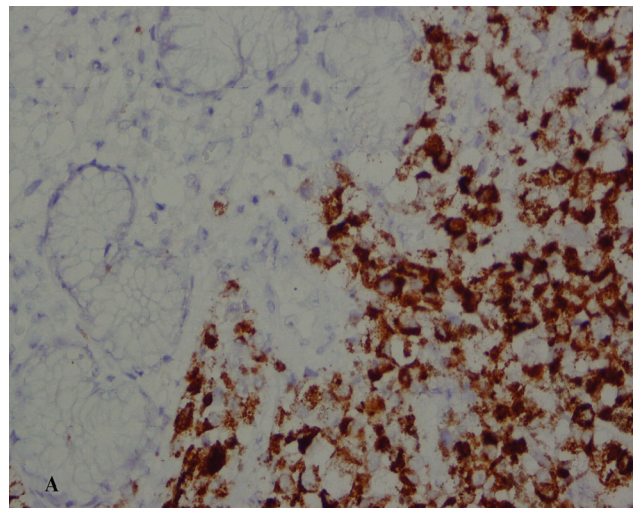


Fig. 4: **A)** Malignant melanoma immunohistochemistry positive HMB45 antibody(case 1); **B)** Malignant melanoma immunohistochemistry positive CK antibody (Case 1); **C)** Malignant melanoma immunohistochemistry positive S100 antibody (Case 1).

2nd Case Report

A 64 years old lady presented with rectorrhagia after trauma. The patient had no history of abnormal bowel habit, bleeding tendency or symptoms of anemia. In physical examination including skin examination, funduscopy of eye and rectal examination, she had not pigmentd lesions in any part of skin, normal fonduscopy and

no palpable mass in digital rectal examination. Lab data was normal. Ultrasound study of abdomenopelvic area revealed some degrees of wall thickening in right side of rectum suggestive of neoplastic lesion. Colonoscopic examination showed pigmented lesion in distal part of rectum. With suggestion of neoplastic lesions laparotomy and abdominopelvic resection was done.

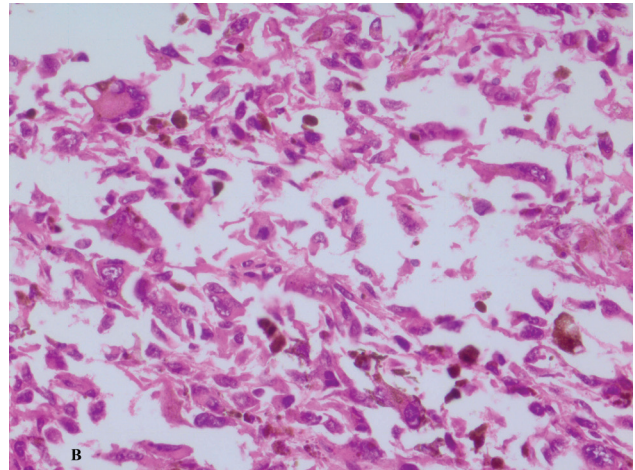
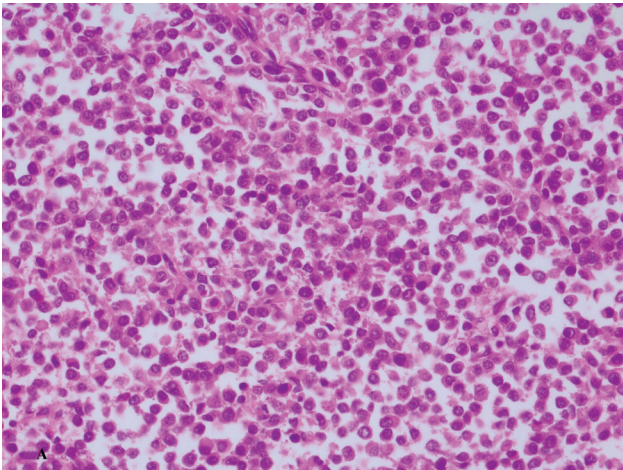


Fig. 5: **A)** Malignant melanoma, H&E stain $\times 100$ (case 2) ; **B)** Malignant melanoma, H&E staining $\times 400$ (Case 2).

Colectomy specimen was sent to pathology ward and several cut sections showed a pigmented brown mass measuring 3x3 x2 cm with surface ulceration. Microscopic sections showed diffuse

infiltration of small cells with large nuclei and pigmented cytoplasm (Fig. 5a, B). In some areas tumor cells show severe pleomorphism and pigmentation

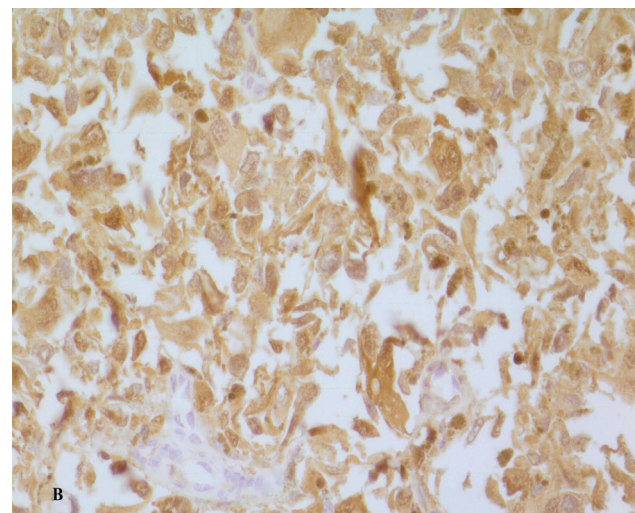
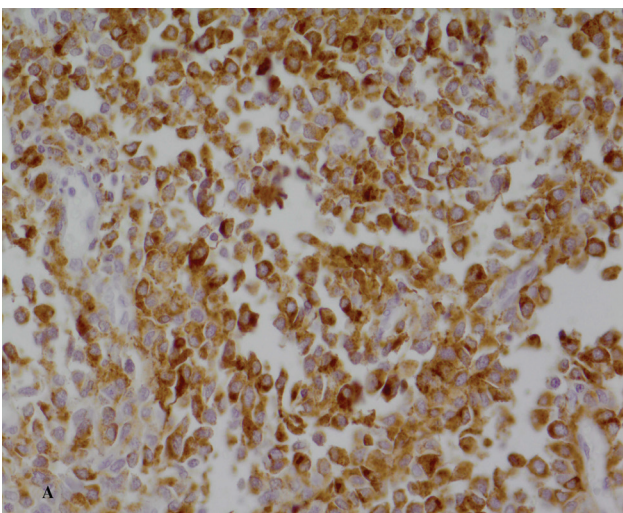
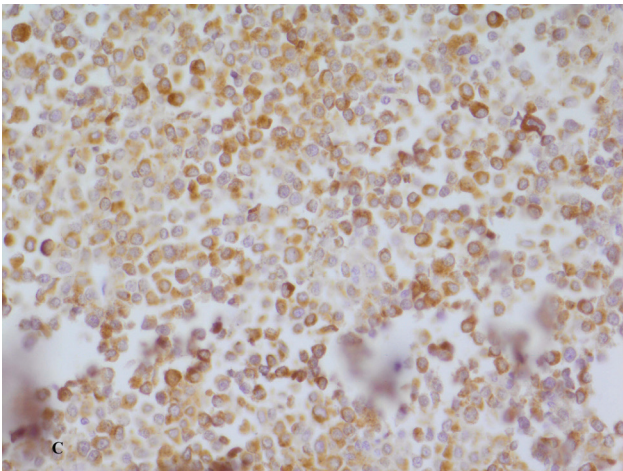


Fig. 6: **A)** Malignant melanoma immunohistochemistry positive HMB45 antibody (Case 2); **B)** Malignant melanoma immunohistochemistry positive S100 antibody (Case 2);



C) Malignant melanoma immunohistochemistry positive Melan A antibody (Case 2).

Discussion

Neurofibromatosis type 1 is a cutaneous disorder that present with multiple cafe'-au-lait macules and neurofibromas which can develop in early childhood (8). Neurofibromin is a protein belonging to the guanosine triphosphate-activating protein family, and participates in cell proliferation control (9). Melanocytes also derive from neural crest cells but MM incidence is not markedly elevated in NF1. There are few case studies that showed association between neurofibroma and malignant melanoma especially in rectum. In first case we presented a rare case that is a known case of NF1 and presented with intestinal lesion which IHC on it revealed MM. The second case was a 64 yr old lady with multiple dark and black pigmented rectal lesions but physical exam showed no evidence skin or eye lesions. In second case also IHC study was done and all markers for MM showed positive reaction. The most important differential diagnosis in these cases is poorly differentiated carcinoma especially in the first case. MM was detected in 0.1% to 5.4% of patients with NF1 (10). Zöller *et al.* in the study of 70 patients with neurofibromatosis type 1 reported only one case of malignant melanoma of skin (11). Bin Amer and Al-Khenaizan reported a 21 month old boy with NF-1 and malignant melanoma of deep organ presented with hepatosplenomegaly, bilateral lung infiltration and bone

involvement. The patient had pigmented skin lesion (10). Our 1st case was asymptomatic NF1 for many years, but recently developed intestinal lesions and MM melanoma in gastrointestinal tract without skin involvement or change in NF1 lesions in her skin. The clinical behavior of MM of gastrointestinal tract is similar to other malignant tumors in gastrointestinal area such as gastrointestinal bleeding, weight loss and anemia (12). "Primary malignant melanoma can arise from mucosa of the gastrointestinal tract, particularly from the esophagus and anorectal area" (13). Zöller *et al.* report 70 Swedish people with NF1 whom increased four-fold malignancy but did not support suggestions of an increased incidence of malignant melanoma (11). However Brasfield and Das Gupta were agree and suggested that NF1 increased the risk the incidence of malignant melanoma (14). Stacy *et al.* reported a case of conjunctival MM in a patient with NF-1 that could be successfully treated with excision, cryotherapy, and topical mitomycin C (15). Primary gastrointestinal melanoma is rare tumor especially when accompanied with NF1. Primary malignant melanoma of gastrointestinal tract may be missed so early detection and resection is helpful for patients and also is critical for long term cure however overall prognosis is poor. Benign and malignant tumors are parts of NF1 so it needs attention both in the clinical setting and in family counseling in adulthood.

Conclusion

Comparing to the present study we need more cases to find exact relation between NF1 lesions and increased risk of MM. In the present study we report two cases of primary malignant melanoma of gastrointestinal tract that one of them is known case of NF1 with no evidence of primary cutaneous or ocular malignant melanoma. It is logical to suggest a relation between malignant melanoma and neurofibromatosis type 1 because both of them arise from neural crest. Criteria's for diagnosis of primary gastrointestinal

melanoma include absence of concurrent skin and eye lesions. We recommended close follow up of patients with NF-1 for occult malignant melanoma.

Acknowledgements

All ethical issues were observed by authors during the study. The authors declare that there is no conflict of interest.

References

1. Kruger S, Noack F, Blochle C, Feller AC. Primary malignant melanoma of the small bowel: a case report and review of the literature. *Tumori* 2005;91(1):73-6.
2. Bisceglia M, Perri F, Tucci A, Tardio M, Panniello G, Vita G, *et al.* Primary Malignant Melanoma of the Esophagus A Clinicopathologic Study of a Case With Comprehensive Literature Review. *Adv Anat Pathol* 2011;18:235-52.
3. Kadivar TF, Vanek VW, Krishnan EU. Primary malignant melanoma of the small bowel: a case study. *Am Surg* 1992;58(7):418-22.
4. Blecker D, Abraham S, Furth E E, Kochman ML. Melanoma in the gastrointestinal tract. *Am J Gastroenterol* 1999;94(12):3427-33.
5. Kenney B, Dotto J, Homer R, Shafi N, Davydova L. Primary malignant melanoma of the transverse colon: report of a case and review of the literature. *Int J Surg Pathol* 2007;15(4):401-7.
6. De Schepper S, Boucneau J, Lambert J, Messiaen L, Naeyaert JM. Pigment cell-related manifestations in neurofibromatosis type 1: an overview. *Pigment cell Res* 2005;18(1):13-24.
7. Salvi PF, Lombardi A, Puzzovio A, Stagnitti F, Tisba M, Gaudinieri A, *et al.* Cutaneous melanoma with neurofibromatosis type 1: rare association? A case report and review of the literature. *Ann Ital Chir* 2004;75(1):91-5.
8. Rubben A, Bausch B, Nikkels A. Somatic deletion of the NF1 gene in a neurofibromatosis type 1-associated malignant melanoma demonstrated by digital PCR. *Molecular Cancer* 2006;5:36.
9. Xu G, O'Connell P, Viskochil D, Cawthon R, Robertson M, Culver M, *et al.* The neurofibromatosis type 1 gene encodes a protein related to GAP. *Cell* 1990;62(3):599-608.
10. Bin Amer Y, Al-Khenaizan S. Fatal malignant melanoma in a child with neurofibromatosis type 1. *Int J Dermatol* 2007;46(9):967-70.
11. Zoeller M, Rembeck B, Ode'n A, Samuelsson M, Angervall L. Malignant and Benign Tumors in Patients with Neurofibromatosis Type 1 in a Defined Swedish Population. *Cancer* 1997;79:2125-31.
12. Elsayed AM, Albahra M, Nzeako U C, Sobin L H. Malignant melanomas in the small intestine: A study of 103 patients. *Am J Gastroenterol* 1996;91(5):1004-6.
13. Ravi A. Primary Gastric Melanoma: A Rare Cause of Upper Gastrointestinal Bleeding. *Gastroenterol Hepatol* 2008;4(11):7997.
14. Brasfield RD, Das Gupta TK. Von Recklinghausen's disease a clinico-pathological study. *Ann Surg* 1972;175:86-104.
15. Stacy RC, Kenyon KR, Jakobiec FA, Colby KA. Conjunctival melanoma arising from primary acquired melanosis in a patient with neurofibromatosis type I. *Cornea* 2010;29(2):232-4.