

## Case Report

### A Rare Case of Myeloid Sarcoma Presenting as Nasal Cavity Mass

Leena Jayabackthan, Jayaprakash Chandrashekar  
Nisha Jayashankar Marla, Muktha Ramesh Pai

*Dept. of Pathology, Father Muller Medical College, Mangalore, India*

#### ABSTRACT

Myeloid Sarcoma (MS) is a tumor mass consisting of myeloblast with or without maturation occurring at an anatomical site other than the bone marrow. Incidence of MS ranges from 1-9% and is most commonly misdiagnosed as Non Hodgkins Lymphoma or poorly differentiated carcinoma. MS can occur in various sites but nasal cavity involvement is rare. Here we report a case of MS presenting as nasal polyp since 2 weeks in a 30 year old male patient who presented to Otolaryngology department of Father Muller Medical College Hospital, India in 2012. Patient was eventually found to have Acute Myeloid Leukemia (AML). This case highlights the importance of hematological and histological correlation coupled with Immunohistochemistry which is mandatory for the accurate diagnosis of this rare entity.

**Keywords:** Myeloid Sarcoma, Nasal Cavity, India, Case Report

#### Introduction

Extramedullary involvement by acute leukemia is relatively rare but clinically significant phenomenon that often poses diagnostic and therapeutic dilemmas (1). Myeloid sarcoma and leukemia cutis are 2 well-known extramedullary manifestations (1).

Granulocytic (myeloid) sarcomas (GS) are rare hematological neoplasm composed of immature myeloid cells at an extramedullary site. Patients

with GS have a poor prognosis (2). It was first described in 1811 by Burns and King (3). In 1853 they termed it chloroma for the green color of the tumor when exposed to air, due to the presence of myeloperoxidase in the tumor cells. As this color was inconsistent and the lesion consisted of immature cells of granulocytic lineage Rappaport suggested designating this neoplasm as granulocytic sarcoma (3). The rate of occurrence is approximately 1 to 9% of patients with AML,

---

*Received: 07 January 2013*

*Accepted: 18 October 2013*

*Address Communications to: Dr. Leena Priya, Department of Pathology, University of Father Muller Medical College, Mangalore, India.*

*Email: drleenapriya@yahoo.co.in*

preferentially in young patients or in children with no difference between sexes (4). The correct diagnosis of MS are essential for adequate therapy which is often delayed due to the high misdiagnosis rate(4). MS are rare neoplasms whose knowledge is largely based on case reports and/or technically dated contributions. There have been only a few reports of MS occurring in the nasal cavity, irrespective of whether the lesion was either de novo or secondary to leukemia. MS is often misdiagnosed as non-Hodgkin's lymphoma (NHL), especially in case of de novo lesions, in the absence of proper immunohistochemical studies (5, 6). While there are reports of these tumors occurring in the nasal cavity and paranasal sinuses, (6) such cases are thought to be exceedingly rare.

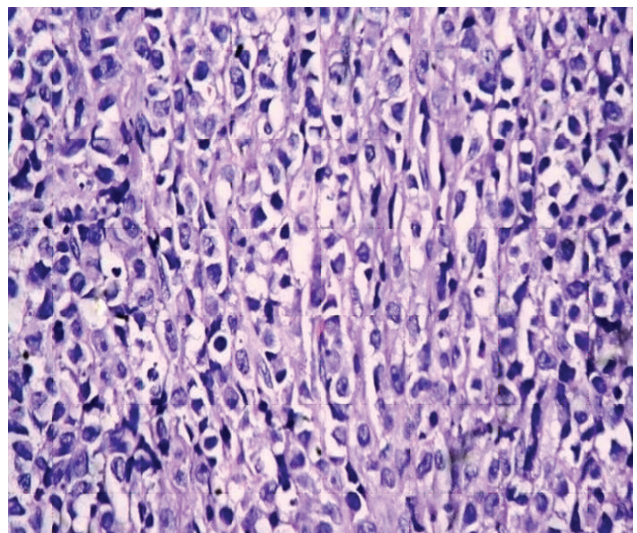
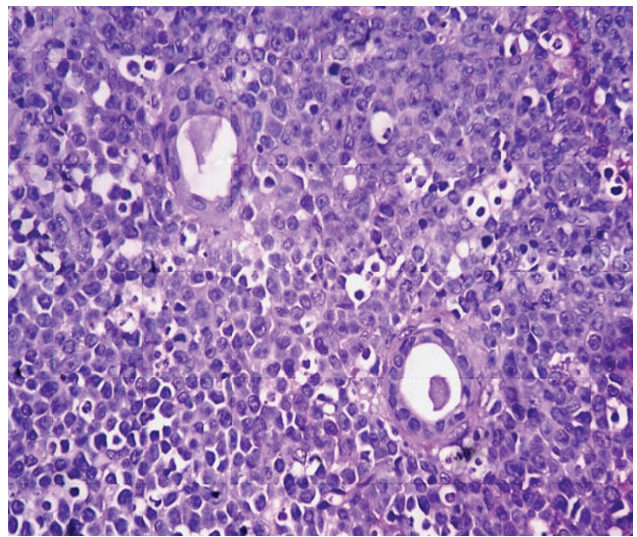
We describe a new case of granulocytic sarcoma of the nasal cavity.

### Case Report

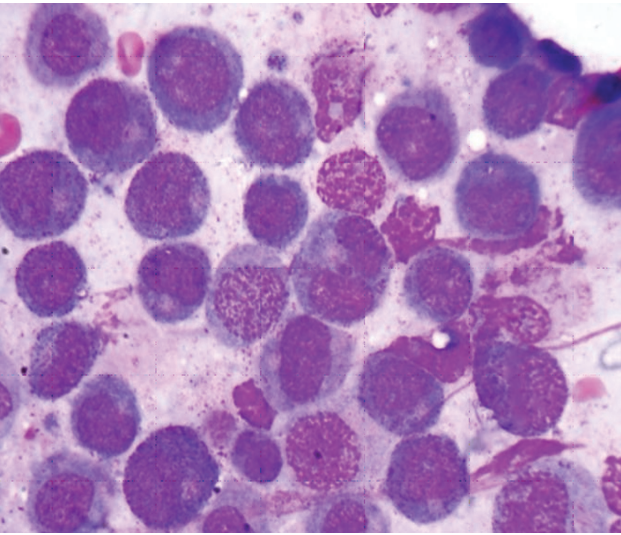
A 30 years "old" male presented with headache, nasal obstruction and decreased vision in the right eye since 2 weeks 'was admitted in Otolaryngology department of Father Muller Medical College Hospital, Karnataka, India in June 2012. He had no significant past history. Clinical examination showed a deviation of nasal septum and a mass arising near the middle meatus.

CT scan showed opacity in nasopharynx with extension into nasal cavity, maxillary sinus, ethmoidal sinuses, and right orbital apex suggestive of neoplastic etiology. A biopsy of the nasal mass was done. On microscopic examination, normal nasopharyngeal tissue architecture was replaced by scattered medium-to-large cells with a high nucleocytoplasmic ratio, a pale cytoplasm, and round-to oval nuclei with open chromatin and prominent nucleoli. The cells were seen surrounding ductal structures (Fig. 1A). The cells were typically arranged in Indian file pattern

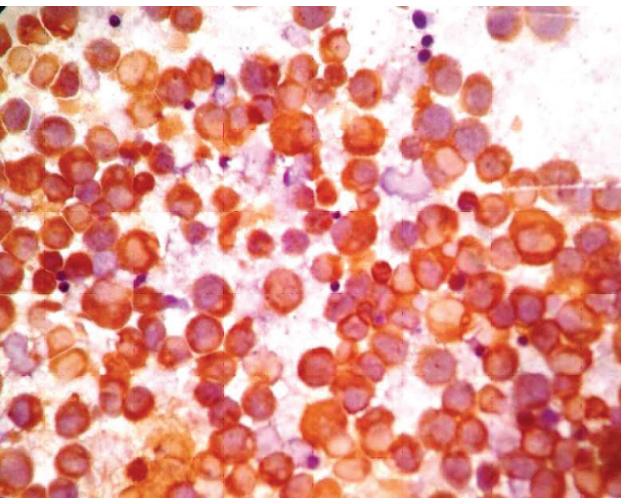
(Fig. 1B). Some background cells exhibited lobulated or banded nuclei and eosinophilic granular cytoplasm, resembling immature eosinophils. Possibility of a Non Hodgkin's lymphoma was considered. Eventually peripheral smear showed atypical cells and bone marrow aspirate showed infiltration by blasts (Fig. 2) which was positive for Sudan black and Myeloperoxidase morphologically suggestive of Acute Myeloid leukemia. Subsequent Immunohistochemistry on the biopsy was positive for CD34 and CD117 (Fig. 3) thus confirming the diagnosis of MS.



**Fig. 1: A)** Microscopy of nasal mass shows cells with round to oval nucleus, open chromatin and prominent nucleoli, (H &E  $\times 10$ ). **B)** Microscopy of nasal mass showing cells arranged in Indian file pattern, (H & E  $\times 20$ )



**Fig. 2:** Bone marrow aspirate smears show predominantly promyelocytes having large nucleus with open chromatin and prominent nucleoli ( $\times 100$ ).



**Fig. 3:** Immunohistochemistry: Blast cells showing strong positivity for CD 117 ( $\times 40$ ).

### Discussion

Myeloid Sarcoma is a tumor mass consisting of myeloblasts with or without maturation occurring at an anatomical site other than the bone marrow. With extensive morphological and immunohistochemical analysis, the MS are classified into five types: a) immature granulocytic sarcoma (IGS); b) differentiated granulocytic sarcoma (DGC); c) monoblastic sarcoma (MBLS); d) monocytic sarcoma, and myelomonocytic sarcoma (MMS) (4).

The involved sites include the skin, lymph node, female reproductive tract, breast, gut, lymph node, and testis. In the head and neck region, myeloid sarcoma develops primarily in the orbital region. Nasopharynx is rarely involved (7, 8). The differential diagnosis of GS must include reactive lesions, benign neoplasms and malignant neoplasms such as sarcomas, lymphomas, epidermoid carcinomas and metastasis of other neoplasm (9).

MS can present De novo, or secondary. Literature reveals very few cases of myeloid sarcoma presenting as nasal mass. Occasionally, it can be the first and the only manifestation of AML, leading to diagnostic challenges (10). Nasal mass was the first manifestation of AML in this case. A report by Prades *et al.* also had similar presentation as our case (6). Epistaxis, prolonged upper respiratory infection resistant to standard therapy has also been described in literature (6, 8). Alexiev *et al.* studied thirteen cases and the largest study of 92 cases by Pileri *et al.* showed nasal cavity as an exceedingly rare site for myeloid sarcomas (4, 11). The histological features of myeloid sarcoma are variable ranging from well differentiated to poorly differentiated cell types. Hence histological diagnosis is difficult especially in unsuspected cases. However careful examination of tissue sections for eosinophilic myelocytes appears to be an important feature that can help clinch the diagnosis (12). We observed a characteristic Indian file pattern infiltrating into the surrounding stroma which is not a feature of lymphomas. Since most of these cases are misdiagnosed as lymphomas this particular pattern appears to be a histological clue towards diagnosis of myeloid sarcoma and not lymphoma. An incomplete workup may be misleading because NHL and MS share morphologic similarities and both express leukocyte antigens, such as CD43 and CD45. The correct diagnosis is missed in about 50% of the cases. Hence a high index of suspicion coupled with ancillary studies such as Immunohistochemistry is mandatory for the diag-

nosis as the prognosis in these patients is poor (13). MS, in adults, are most frequently associated with French-American-British subtypes M2 and M4, which is probably one of the most important risk factors for extramedullary involvement in patients with AML (14).

An immunohistochemical panel including CD43, MPO, CD117, CD68, CD34, CD3 and CD20 can successfully identify the majority of MS in formalin-fixed, paraffin-embedded tissue. MPO and CD117 are the most sensitive of the markers for myeloid differentiation while monocytic precursors consistently strongly express CD68 and CD163 (4). The most common genetic aberrations in MS associated with hematopoietic disorders are t(8, 21), inv 16 and trisomy 8 (14).

### Conclusion

Myeloid sarcomas presenting as Sinonasal and nasopharyngeal mass is unusual. Making the correct diagnosis of these relatively rare tumors can be challenging, especially those that are poorly differentiated variants. Myeloid sarcomas should be considered in the differential diagnosis of any unusual looking, difficult to classify lymphoma. A thorough clinical and hematological correlation along with Immunohistochemistry is mandatory for the correct diagnosis.

### Acknowledgements

The authors declare that there is no conflict of interests.

### References

1. Albano F, Specchi G. Extramedullary disease (EMD) in acute promyelocytic leukemia (APL). *Mediterr J Hematol Infect Dis* 2011;3(1):e2011066.
2. Paydas S, Zorludemir S, Ergin M. Granulocytic sarcoma: 32 cases and review of the literature. *Leuk Lymphoma* 2006; 47:2527-41.
3. Ferri E, Minotto C, Ianniello F, Cavaleri S, Armato E, Capuzzo E Maxillo-ethmoidal chloroma in acute myeloid leukaemia: Case report. *Acta Otorhinolaryngol Ital* 2005; 25: 195-9.
4. Alexiev AB, Wang W, and Zhao FX. Myeloid Sarcoma: a histologic, immunohistochemical and cytogenetic study. *Diagn Pathol* 2007;2: 42.
5. Yamamoto Y, Uchima T, Konoike Y, Nakamin H. Myeloid Sarcoma in the Nasal Cavities that Developed during the Course of Acute Myelomonocytic Leukemia. *J Clin Exp Hematopathol* 2010; 50(2):165-70.
6. Prades JM, Alaani A, Mosnier JF, Dumollard JM, Martin C. Granulocytic sarcoma of the nasal cavity. *Rhinology* 2002; 40:159-61.
7. Yamauchi K, Yasuda M. Comparison in treatments of nonleukemic granulocytic sarcoma: Report of two cases and a review of 72 cases in the literature. *Cancer* 2002;94:1739-46.
8. Gorman M, Ahmed KA, Pallera A, Samant A. Granulocytic sarcoma of the nasal cavity. *Ear Nose Throat J* 2009;88(11):1210-2.
9. Osterne RLV, Matos-Brito RG, Alves APNN, Nogueira TNAG, Rocha-Filho FD, Meneses FA, *et al.* Oral Granulocytic Sarcoma: A case report. *Med Oral Patol Oral Cir Bucal* 2009;14(5):232-5.
10. Messenger M, Amielh D, Chevallier C, Mariette C. Isolated granulocytic sarcoma of the pancreas: A tricky diagnostic for primary pancreatic extramedullary acute myeloid leukemia. *World J Surg Oncol* 2012 ;10:13.
11. Pileri SA, Ascani S, Cox CM, Campidelli C, Bacci F, Piccioli M, *et al.* Myeloid sarcoma: clinico-pathologic, phenotypic and cytogenetic analysis of 92 adult patients. *Leukemia* 2007; 21: 340-50.
12. Cho FS, Liu CY, Tsai JH *et al.* Myeloid Sarcoma Mimicking Nasopharyngeal Carcinoma. *J Clin Oncol* 2011; 29(1): 706-8.
13. Neiman RS, Barcos M, Berard C, Bonner H, Mann R, Rydell RE, *et al.* Granulocytic sarcoma: A clinicopathologic study of 61 biopsied cases. *Cancer* 1981; 48(6):1426-37.
14. AlKhateeb H, Badheeb A, Haddad H, Marei L, Abbasi S. Myeloid Sarcoma: Clinicopathologic, Cytogenetic, and Outcome Analysis of 21 Adult Patients. *Leukemia Res Treatment* 2011;2011:523168.