

Case Report

Primary Tuberculosis of Breast: Case Report

Ehsan Malekianzadeh, Sedigheh Khazaei, Babak Izadi, Mahtab Rahbar

*Dept. of Molecular Pathology, Research Center, Imam Reza University Hospital, Kermanshah
University of Medical Sciences, Kermanshah, Iran*

ABSTRACT

Although breast tuberculosis still remains rare, but in endemic countries should be in differential diagnosis of breast cancer and abscess. Imaging modalities cannot distinguish between cancer and tuberculosis. Acid fast bacilli stain; culture and PCR are helpful diagnostic methods but unfortunately are not very sensitive. Negative results do not rule out this diagnosis, so it seems definite diagnosis can be made by open biopsy and histologic evidence (granuloma tissues). In this case, a 33 years old woman was referred to the Infectious Ward in Imam Reza Hospital, Medical University of Kermanshah, western Iran in 2011; complaining of one lump in her left breast which did not response to usual therapy (painkillers and antibiotics). Fine needle aspiration for histologic and cytologic evaluations were negative but open biopsy showed granulomatous tissues, anti-tuberculosis chemotherapy was begun and response was significant then PCR was reported positive. We think in endemic area, empirical treatment can be started based on histological evidence and proper clinical manifestation.

Keyword: Breast, Tuberculosis, Iran

Introduction

Tuberculosis is a very old disease. It was co-existed with human as far back as 5000 BC, according to the spine tuberculosis lesion (Pott's disease) from egyptian mummies.

Currently one person becomes newly infected every second worldwide. *Mycobacterium tuberculosis* mostly affects lungs but can involve any organ (1) and nearly 17.9% of TB cases have only extra pulmonary manifestation. Some tissues have relative resistance to tuberculosis

Received: 11 May 2013

Accepted: 18 October 2013

Address Communications to: Sedigheh Khazaei, Molecular Pathology Research Center, Emam Reza Hospital, Zakaria Razi Bly, Kermanshah, Iran.

Email: skhazaei2003@yahoo.com

(spleen, breast and skeletal muscles).

Tuberculosis of breast is seen quite rare (0.1-0.5% of all tuberculosis cases) (2, 3) and it constitute approximately 3% of all surgical breast diseases in developing countries (4) but may be raising especially in immunocompromised patients and with development of drug resistance strains of *M. tuberculosis* (5, 6). Breast tuberculosis was first described by Sir-Astley Cooper in 1829 as the “scrofulous swelling in the bosom of young women” (7). It is usually seen in young (20-50 years), married, multiparous and breast-feeding women (6-10). However, it was seen in prepubescent, elderly woman and even in men (7, 9) and might be the first manifestation of HIV infection (6). Breast can be affected primary (breast solely) or secondary (with other foci in the body) (11).

Presentation of breast tuberculosis is variable and may be confused and misdiagnosed with pyogenic abscess, carcinoma of breast and in less with the others granulomatosis disease like sarcoidosis and fungal infections (6, 7).

The most common clinical presentation is hard, irregular, unilateral occasionally bilaterally lump in the centrum or the upper outer quadrant of the breast, often associated with an inflammation of the overlying skin with regional lymphadenopathy (up to 15%) clinical examination usually fails to differentiate breast tuberculosis from breast carcinoma (3, 6, 9, 10).

Case Report

A 33 yr- old Iranian non pregnant woman was referred to the Infectious Ward in Imam Reza Hospital, Medical University of Kermanshah, western Iran September 201.

Eight months before admission she was well when felt pain and mild stiffness in the upper part of her left breast, she was visited by general

practitioner and discharged with ibuprofen and recommended warm pack. Her symptoms was not better significantly and she took painkiller occasionally after two months she noticed a tender solid mass 2×2 cm in internal upper of her left breast with erythema skin on it.

She was visited again by a family medicine and treated by cloxacillin capsule 500 milligram each 6 hours for 2 weeks but there was no improvement, until two draining fistulas appeared on the left breast and referred to our hospital. In history she denied any disease but reported pulmonary tuberculosis in her grandmother (whom was treated by anti-tuberculosis drugs)

In physical examination, there was a 2× 2 cm mobile non-tender solid mass in the upper right quadrant of her left breast with two small fistulas with semi- purulent secretions under pressure. Skin over mass was erythematous. There was no nipple retraction. In the left auxiliary there was a non tender 2×3 cm lymph node.

The other exams and all laboratory evaluations were normal because of variable differential diagnosis besides tuberculosis (e.g. malignancy) FNA and chest CT scan was done to confirm diagnosis (Fig. 1).

Histology analysis showed chronic granulomatous inflammation with caseous necrosis and longhorns-type giant cell and no malignant or atypical cell was detected (Fig. 2).

Anti TB drugs (rifampin, isoniazid, pyrazinamide and ethambutol) was prescribed according to histologic findings. Diagnosis was confirmed by molecular detection of *M. tuberculosis* complex by PCR. Treatment by anti tuberculosis drugs continued for 6 months. Response and improvement was significant.

She is currently being followed-up and the disease shows no signs of recurrence until now.

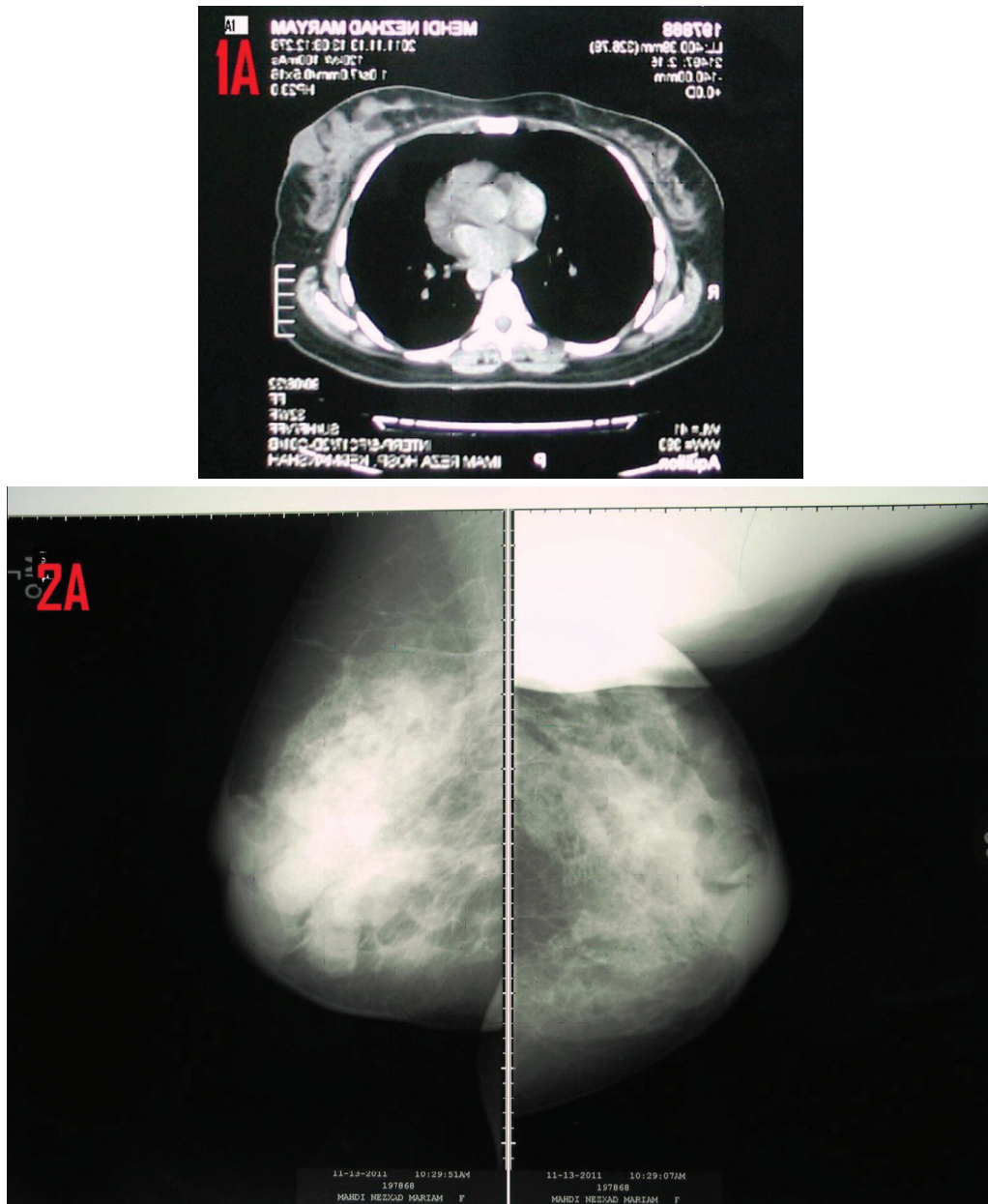


Fig.1: A) In lung CT generalized swelling of left breast was present; B) Mammography revealed inflammatory mass in left breast.

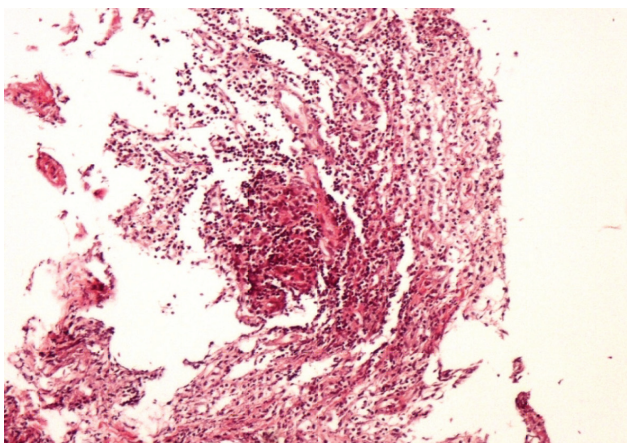


Fig.2: Granulomatous necrosis, Hematoxylin and Eosin staining $\times 100$

Discussion

In 1829, Sir Astley Cooper defined breast tuberculosis as the scrofulous swelling of bosom (1). Although breast tuberculosis is a rare disease and its incidence range 0.1-0.52, it has been increasing in endemic region. It is mainly classified as primary and secondary from. In the primary tuberculosis of breast, the only location of disease is the breast and infection spreads by hematogenous or direct extension (direct extension occurs by contact of infected material with irritated skin or breast ducts during the lactation period).

Secondary forms are seen more frequently and a prior history of tuberculosis exists in these cases. The main routes of spread are hematogenous, retrograde spread from axillary lymph nodes, or direct extension from lung, pleura, mediastinum, ribs, sternum and articular lesion (2). In our case, breast tuberculosis was considered to be primary form because the others tuberculosis infection focuses were not detected by physical examination or radiological examination, and there was no prior history.

Breast tuberculosis was classified into five different types by McKeown and Wilkinson:

- (I) Nodular tubercular mastitis.
- (II) Disseminated or confluent tubercular mastitis.
- (III) Sclerous tubercular mastitis.
- (IV) Tuberculous mastitis obliterans.
- (V) Acute miliary tubercular mastitis.

Risk factors are multiparity, lactation, trauma, past history of suppurative mastitis, and AIDS (7).

Breast tuberculosis can be presented as a lump, ulcer, and breast abscess with or without secreting sinus lump is commonly seen in the central or upper outer quadrant of the breast (7) left and right breast involve equally but bilateral involvement is very rare. Constitutional symptoms such as fever, weight loss, night sweats are not common (8). The involvement of the nipple and areola is a rare in TB (8).

Radiologic imaging modalities like mammography and ultrasonography are unreliable in distinguishing breast tuberculosis from breast carcinoma (the serious differential diagnosis of breast tuberculosis) (8). Similarly computed tomography (CT) scan and MRI do not give a conclusive diagnosis without histopathological confirmation. CT scan is useful in differentiating between the primary and secondary forms it is also helpful in evaluating the relationship between deeply located lesion with the chest wall and pleura and in detecting parenchymal lesions of the lung (2). It

can give valuable guides to surgery and estimation of the disease including the involvement of the chest wall (8).

Others studies showed that; First, imaging modalities for breast tuberculosis are non-diagnostic. Second, positive smear of secretions for Acid-Fast Bacilli include minority of samples (negative smear does not rule out breast tuberculosis). Third, fine needle aspiration (FNA) for cytology and histology is an important diagnostic tool for breast tuberculosis but negative FNA cannot rule out it definitely (12-14).

In our case despite negative fine needle aspiration, open biopsy was done and histological examination revealed granulomatous inflammation and we decided to start anti-tuberculosis drugs for patient according to clinical features, living in endemic area and histological evidence. Response to treatment was significant and PCR for *M. tuberculosis* was positive so we think in endemic area, treatment can start empirically based on histological evidence in suspected cases and negative FNA should be confirmed by open biopsy and PCR.

Conclusion

Breast tuberculosis is rare but in endemic countries still remains one of the differential diagnosis of breast abscess (particularly if chronic and does not response to routine antibiotics) in our case we diagnosed this breast tuberculosis according to history (chronicity, fistulas) and histologic evidence (granulomatous tissue) and at last with PCR positive. It seems negative acid fast bacilli stain, culture and even FNA cannot rule out breast tuberculosis completely (especially in endemic countries).

Acknowledgement

The authors declare that there is no conflict of interests.

References

1. Sen M, Gorpelioglu C, Bozer M. Isolated primary breast tuberculosis report of three cases and review of the literature. *Clinics* 2009;64(6):607-10.
2. Kervancioglu S, Kervancioglu R, Ozkur A, SAirikci A. Primary tuberculosis of the breast. *Diagn Interv Radiol* 2005;11(4):210-2.
3. Mirsaeidi SM, Masjedi MR, Mansouri SD, Velayati AA. Tuberculosis of the breast: report of 4 clinical cases and literature review. *Eas Mediter Health J* 2007; 13(3):670-6.
4. Khanna R, Prasanna GV, Gupta P, Kumar M, Khanna S, Khanna AK. Mammary tuberculosis: report on 52 cases. *Postgrad Med J* 2002; 78(921):422-4.
5. Tewari M, Shukla HS. Breast tuberculosis: diagnosis, clinical features & management. *Indian J Med Res* 2005; 122(2):103-10.
6. Kapan M, Toksoz M, Bakir SD, Sak ME, Evsen MS. Tuberculosis of breast. *Eur J Gen Med* 2010;7(2):216-9.
7. Wani I, Lone AM, Malik R, Wani KA, Wani RA, Hussain I, *et al.* Secondary tuberculosis of breast: case report. *ISRN Surgery* 2011;Article ID 529368.
8. Kao PT, Tu MY, Tang SH, Ma HK. Tuberculosis of the breast with erythema nodosum: a case reprot. *J Med Case Rep* 2010;29(4):124.
9. Ghorbani G, Tavakoli F. Tuberculosis of breast in a woman with history of prolactinoma: A case report. *J Reprod Infertil* 2002; 1: 63-8.
10. Atamanalp S, Gundogdu C, Polat P, Ozturk G, Aydinli B, Oren D, *et al.* Clinical presentation of breast tuberculosis in eastern Anatolia. *Turk J Med Sci* 2010;40(2):293-7.
11. Yuen J, Lam T, Leong L. Primary tuberculosis of the breast. *J HK Coll Radiol* 2003;6:33-5.
12. Ahmed R, Sultan F. Granulomatous mastitis: a review of 14 cases. *J Ayub Med Coll Abbottabad* 2006;18(1):52-4.
13. Fadaei-Araghi M, Geranpayeh L, Frani S, Matloob R, Kuraki S. Case report Breast tuberculosis: Report of eight cases. *Arch Iranian Med* 2008;11(4):463-65.
14. Tewari M, Shukla HS. breast tuberculosis: diagnosis, clinical features and management. *Indian J Med*;122:103-110.