

## Peripheral Primitive Neuroectodermal Tumor of the Ovary: The Report of Two Rare Cases

Fatemeh Nili<sup>1</sup>, Azadeh Sedighi Moghadam Pour<sup>1</sup>, Hedieh Moradi Tabriz<sup>2</sup>, Parisa Sedighi Moghadam Pour<sup>3</sup>,  
Hana Saffar<sup>1\*</sup>

1. APCP, Dept. of Anatomical and Surgical Pathology, Cancer Institute, Imam Khomeini Hospital Complex, Tehran University of Medical Sciences, Tehran, Iran
2. APCP, Dept. of Anatomical and Surgical Pathology and Laboratory Medicine, Sina Hospital, Tehran University of Medical Sciences, Tehran, Iran
3. Radiologist, Guilan University of Medical Sciences, Guilan, Iran

---

### KEYWORDS

Neuroectodermal Tumor  
pPNET,  
Ovary

---

### Article Info

Received 17 March 2017;  
Accepted 13 Sep 2018;  
Published Online 25 Sep 2018;

---

### ABSTRACT

Peripheral primitive neuroectodermal tumor (pPNET) is a highly aggressive small round cell tumor belonging to PNET/Ewing sarcoma family. Ovarian tumors composed of primitive neuroectodermal elements are extremely rare.

Herein we reported two cases of peripheral primitive neuroectodermal tumors of ovary in two patients with different clinical presentations. Definite diagnoses were made based on the histomorphology and immunohistochemistry results.

With respect to different clinical behaviors, treatment modalities and prognosis of peripheral primitive neuroectodermal tumors compared to other known ovarian neoplasms, it is essential to consider this entity as a differential diagnosis in ovarian tumors especially in young patients.

---

### Corresponding information:

Hana Saffar, APCP, Dept. of Anatomical and Surgical Pathology, Cancer Institute, Imam Khomeini Hospital Complex, Tehran University of Medical Sciences, Tehran, Iran, E-mail: hana\_saffar283@yahoo.com

Copyright © 2018, IRANIAN JOURNAL OF PATHOLOGY. This is an open-access article distributed under the terms of the Creative Commons Attribution-non-commercial 4.0 International License which permits copy and redistribute the material just in noncommercial usages, provided the original work is properly cited.

### Introduction

Primitive neuroectodermal tumor (PNET) belongs to a group of highly malignant neoplasms which are composed of small round cells of neuroectodermal origin. These tumors are subclassified as central and peripheral subtypes according to the location and the cell of origin (1, 2). Peripheral PNET (pPNET) is an unusual subtype which occurs outside the central and sympathetic nervous system. Several cases are reported in ovaries, uterus, abdominal cavity, peritoneum and lung (3).

Primary neuroectodermal tumors of the ovary are considered as monophasic teratomas exclusively or almost exclusively composed of neuroectodermal tissue. Fewer than 100 neuroectodermal tumors of the ovary have been reported in the literature. These tumors were classified as ependymoma, astrocytoma, glioblastoma multiforme, ependymoblastoma or as

primitive neuroepithelial tumors such as medulloblastoma, medulloepithelioma and neuroblastoma (4).

Herein, we presented two cases of pPNET in 23 and 52 year-old women arising from ovaries extending to pelvic cavity and peritoneum.

### Case Reports

#### Case 1

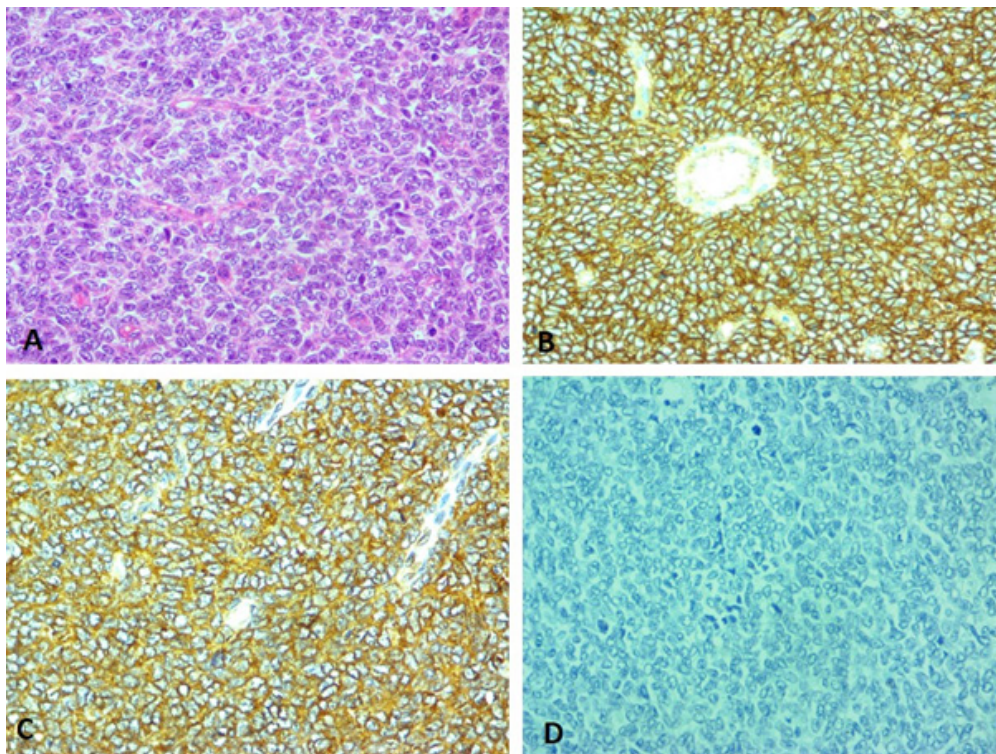
A 23-year-old nulligravida woman with irregular menstrual bleeding and abdominal pain referred to our hospital. She showed elevated level of serum CA125 up to 1072 U/ml. Other tumor markers including AFP, BHCG and CA19-9 were within normal limits. Pelvic ultrasonography revealed bilateral adnexal thick-walled cystic masses with multiple thin internal septae and tense ascites in peritoneal cavity. All of these findings were suggestive of krukensberg tumor. Magnetic resonance imaging (MRI) showed large amount of ascites in pelvic cavity and two large

thick-walled cystic masses in midline and left side of the pelvic cavity, measuring 66 and 76 mm, both with rapid wall contrast enhancement in favor of bilateral ovarian cystic tumors. Bowel loops with diffuse serosal enhancement were noted in the cul-de-sac indicative of diffuse peritoneal seeding.

During laparotomy, massive ascites and diffuse involvement of omentum, small intestine and rectum was identified. Large bilateral ovarian masses seemed inoperable. Only omentectomy and ovarian biopsy were done.

Microscopic examination revealed neoplastic tissue composed of very crowded small cells with high nuclear-cytoplasmic ratio and mild pleomorphism in nuclei mainly arranged in sheets with occasional organoid pattern. Frequent mitotic activity was also seen (Figure 1).

Further investigation by immunohistochemical (IHC) study showed positive result for MIC2 (CD99), NSE, Synaptophysin and Vimentin. Negative markers included CK AE1/AE3, CK7, CK20, EMA, Inhibin, Calretinine, LCA, P53, WT1 and GFAP.



**Figure 1.** Proliferation of small round cells in a patternless manner H&E 40X (A), Immunohistochemistry study showing positive reaction with CD99 (B) and NSE(C). Negative reaction for Calretinin (D)

According to the above histopathological and immunohistochemical findings the diagnosis of small round cell tumor, compatible with primitive neuroectodermal tumor was made.

Two weeks later, chemotherapy with five cycles of Mesna, Vincristine, Adriamycin and Cyclophosphamide was started. Subsequently, she underwent total abdominal hysterectomy, bilateral salpingo-oophorectomy and resection of parts of ileum and rectum. Histopathological examination revealed extensive fibrosis and necrosis in ovaries and small residue of

tumor at the serosal surface of resected bowels. After 15 months from the initial presentation, she survived without evidence of recurrence or metastasis receiving chemotherapy.

### Case 2

A 52-year-old multigravida woman with two months history of abdominal pain was evaluated. A large pelvic mass measuring 109x78x67mm along with significant amount of ascites were noted. No distinct preserved ovarian tissue was detected. Core needle biopsy was performed. Histopathologic and IHC

study revealed small round cell tumor with strong immunoreactivity for CD99 and NSE compatible with pPNET. After six cycles of treatment with chemotherapeutic agents including Vincristine, Doxorubicin, Cyclophosphamide and Ifosfamide, the patient underwent total abdominal hysterectomy and bilateral salpingo-oophorectomy along with omentectomy and lymphadenectomy.

Macroscopic examination revealed enlarged ovaries measuring 5.5x 4.5x4 and 5x4.5x3.5 cm with solid-cystic cut surfaces and foci of necrosis and fibrosis.

On microscopic examination, patternless proliferation of small round cells with small amount of cytoplasm and round to oval rather uniform nuclei outgrown by extensive foci of necrosis and fibrosis in both ovaries were seen. IHC findings were similar to the biopsy sample and the first case.

### Discussion

PNETs are the most common type of all neuroectodermal ovarian tumors (5). When associated with teratoma, they are thought to be of germ cell origin. However, in the pure forms, neometaplasia in müllerian-related tissues is considered as their origin (6).

Less than 100 cases of ovarian pPNET have been reported in the literature. Most of them were diagnosed in the third and fourth decades of life, but occasionally they were first discovered in children, adolescents or older women (4). Fischer et al. reported the oldest case of ovarian PNET in a 75-year-old woman coexisting with endometrioid adenocarcinoma (13). There was no specific clinical sign and symptom, serologic marker or radiologic finding for preoperative diagnosis. Pathologic examination was the only accurate method of diagnosis which can be achieved through the core needle biopsy in the case of high clinical suspicion for high grade tumors other than epithelial malignancies.

Microscopically, this tumor is reminiscent of primitive neuroectodermal tumors in the nervous system (4). The tumor is frequently confused with other types of ovarian tumors such as granulosa cell tumor, small cell carcinoma of hypercalcemic type, and endometri-

od carcinoma (6). Strong immunoreactivity for CD99, and negative reaction for sex cord stromal, epithelial and hematolymphoid markers facilitate the correct diagnosis (7). In 99% of PNET cases, the reciprocal translocation t (11; 22) was observed in cytogenetic examination. Kawauchi et al. detected characteristic chromosomal translocation t (11; 22) in one case of ovarian PNET with reverse transcriptase (RT)-PCR (8). Unfortunately, molecular analysis for evaluating the translocation was not available in our center.

Although rare, PNET is a highly aggressive tumor of ovary which must be differentiated from metastatic tumors by several investigations. Most of the reported cases in the literature were in advanced stages at the time of presentation. Involvement of pelvic cavity or distant metastasis to the lung, bone and bone marrow are the most common ways of spread. Yousefi et al. reported 3 cases of pelvic PNET with distant metastasis to lung and brain (1). The clinical stage is the most important prognostic factor and the outcome is generally poor. The survival rate was reported in range of 10.8-36 months (3).

Rarity of PNET in ovary makes it impossible to perform a randomized clinical study for management of this neoplasm.

One of the largest studies conducted by Morovic and Damjanov showed that disease stage appears to be the most important prognostic factor in PNET of the ovary (4).

Although there are reported cases of stage IA disease with survival rate of 3-5 years which were only treated with staging laparotomy, stage IC patients must also receive adjuvant chemotherapy. For women in stage III-IV disease, despite their low effectiveness, debulking surgery in combination with chemotherapy should be considered (9).

The optimal chemotherapy regimen for management of ovarian PNETs is unknown. Using Cisplatin-based regimens such as BEP (Bleomycin, Etoposide and Cisplatin) directed in germ cell tumors, is not advocated by some authors (10). Their recommendation is a combination of Doxorubicin, Ifosfamide and Cyclophosphamide. In one of the largest studies by Erlich



et al. in 2010 on transformed testicular PNETs, Cyclophosphamide, Doxorubicin, Vincristin alternating with Etoposide and Ifosfomide was recommended as the treatment of choice (11). However, some authors prefer integrated regimens for both germ cell and neuroectodermal tumors (12). In both reported cases in this study, the recommended regimen for Ewing's sarcoma family of bone/soft tissue sarcomas were considered for the neoadjuvant treatment and partial

response was detected after complementary surgery.

### Conclusion

Primitive neuroectodermal tumor of ovary is a rare entity with an aggressive behavior. It must be considered as a differential diagnosis of ovarian or pelvic masses especially in young women.

### Conflict of interest

All authors declare that there is no conflict of interest regarding the publication of this article.

### References

1. Yousefi Z, Sharifi N, Hasanzadeh M, Mottaghi M, Bolandy S. Peripheral Primitive Neuroectodermal Tumor of the Pelvis. *Iran J Med Sci.* 2014; 39(1): 71-4. PMID: [24453398](#)
2. Kim YJ, Jang BW, Lee SK, Kim BK, Nam SL. a case of primitive neuroectodermal tumor of the ovary. *Int J Gyn cancer.* 2004;14(2):370-2. <https://doi.org/10.1111/j.1048-891X.2004.014224.x> PMID: [15086740](#)
3. Kuk JY, Yoon SY, Kim MJ, Lee JW, Kim BG, Bae DS. A case of primitive neuroectodermal tumor of the ovary. *Korean J Obstet Gynecol.*2012;55 (10):777-781. <http://dx.doi.org/10.5468/KJOG.2012.55.10.777>
4. Morovic A, Damjanov I. Neuroectodermal ovarian tumors: A Brief Overview. *Histol Histopathol.* 2008; 23(6): 765-71. <https://doi.org/10.14670/HH-23.765> PMID: [18366014](#)
5. Gupta N. Ovary tumor, other tumors not specific to ovary, [www.pathologyoutlines.com](http://www.pathologyoutlines.com)
6. Guerrieri C, Jarsfelt I. Ependymoma of the ovary a case report with immunohistochemical, ultrastructural, and DNA cytometric findings, as well as histogenetic considerations. *Am J Surg Pathol.* 1993;17(6):623-32. <https://doi.org/10.1097/00000478-199306000-00011> PMID: [8333561](#)
7. Mutter GL, Prat J. Pathology of female reproductive tract. 3rd edition, New York, Churchill Livingstone, Elsevier;2014.
8. Kawauchi SI, Fukuda T, Miyamoto S, Yoshioka J, Shirahama S, Saito T, et al. Peripheral primitive neuroectodermal tumor of the ovary confirmed by CD99 immunostaining, karyotypic analysis, and RT-PCR for EWS/FLI-1 chimeric mRNA. *Am J Surg Pathol.* 1998; 22(11):1417-22. PMID: [9808135](#)
9. Lim YK, Ku CW, Teo GC, Lim SL, Tee CS. Central primary primitive neuroectodermal tumor (cPNET) arising from an ovarian mature cystic teratoma in pregnancy: A case report and review of medical literature. *Gynecol Oncol Case Rep.* 2013; 4: 56–9. <https://doi.org/10.1016/j.gynor.2013.01.004> PMID: [24371678](#)
10. Ganjoo KN, Foster RS, Michael H, Donohue JP, Einhorn LH. Germ cell tumor associated primitive neuroectodermal tumors. *J Urol.* 2001;165(5): 1514–1516. [https://doi.org/10.1016/S0022-5347\(05\)66339-2](https://doi.org/10.1016/S0022-5347(05)66339-2)
11. Ehrlich Y, Beck SD, Ulbright TM, Cheng L, Brames MJ, Andreou M, et al. Outcome analysis of patients with transformed teratoma to primitive neuroectodermal tumor. *Ann Oncol.* 2010;21(9):1846–1850. <https://doi.org/10.1093/annonc/mdq045> PMID: [20231305](#)
12. Al-Jumaily U, Al-Hussaini M, Ajlouni F, Abulruz A, Sultan I. Ovarian germ cell tumors with rhabdomyosarcomatous components and later development of growing teratoma syndrome: a case report. *J Med Case Rep.* 2012;6:13. <https://dx.doi.org/10.1186%2F1752-1947-6-13> PMID: [22248255](#)

### How to Cite This Article

Nili F, Sedighi Moghadam Pour A, Moradi Tabriz H, Sedighi Moghadam Pour P, Saffar H. Peripheral Primitive Neuroectodermal Tumor of the Ovary: The Report of Two Rare Cases. *Iranian Journal of Pathology*, 2018; 13(4): 467-470.