

Meningioangiomas in an otherwise healthy 13 year-old boy: A case report with emphasis on histopathological findings.

Dorna Motevalli, Naser Kamalian, Seyed Mohammad Tavangar

Dept. of Pathology, School of Medicine, Tehran University of Medical Sciences, Tehran, Iran

KEY WORDS

Meningioangiomas
sporadic
seizure
histopathology

ABSTRACT

Meningioangiomas is regarded as a rare benign hamartomatous condition mostly involving the cerebral cortex and overlying leptomeninges. A strong association of MA with neurofibromatosis type 2 has been documented in published articles. Herein we report a case of an otherwise healthy 13-year-old boy with no family history or stigmata of neurofibromatosis who presented with intractable seizures. MRI revealed a 2x2 cm mass lesion in the frontal lobe. The patient underwent complete surgical resection of the lesion. Although the primary radiologic impression of the lesion was glioma, pathological evaluation of the resected specimen showed mainly proliferation of meningotheelial cells and fibroblast-like cells with many thickened blood vessels, which are typical for diagnosis of meningioangiomas. After surgical removal of the lesion, the patient is free of seizures.

ARTICLE INFO

Received 29 Aug 2015;

Accepted 12 Feb 2016;

©Iran J Pathol. All rights reserved.

Corresponding Information: Dr. Seyed Mohammad Tavangar, Dept. of Pathology, Shariati Hospital, Tehran University of Medical Sciences, Tehran, Iran.
Tel: 00989121485080 Email: tavangar@ams.ac.ir

COPYRIGHT © 2016, IRANIAN JOURNAL OF PATHOLOGY. This is an open-access article distributed under the terms of the Creative Commons Attribution-noncommercial 4.0 International License which permits copy and redistribute the material just in noncommercial usages, provided the original work is properly cited.

Introduction

Meningioangiomas (MA) is an extremely rare malformative non-neoplastic condition of cerebral cortex and overlying leptomeninges (1,2). The diagnosis of MA is difficult based on clinical and imaging alone, therefore histomorphological examination plays an important role and remains the most reliable way in establishing the diagnosis. Because of the rarity of MA and its hamartomatous nature, it can be mistaken with similar pathologies such as meningiomas, cavernous malformations, and other vascular abnormalities, therefore a thorough clinical, radiological, and histopathological correlation is

recommended to avoid any further aggressive treatment (1-4). Herein we present a case of Meningioangiomas, emphasizing of histomorphological characteristics.

A review of the published English articles in PubMed was done in April 2015 with Keywords meningioangiomas, meningio angiomas and meningeal angiomas. The result was 118 articles that used for collecting data. Other articles were regarding Meningioangiomas in animals. To the best of our knowledge about 130 cases of meningioangiomas have been published in the literature, many of the reported cases are associated with genetic disease especially

neurofibromatosis type 2. Most of the published articles are emphasizing on radiologic characteristics of MA. In this article we discuss about histopathological characteristics of this rare benign lesion.

Case Report

The patient was a 13-year-old male with recent sudden-onset intractable seizures. He had no family history or stigmata of neurofibromatosis

and he otherwise healthy. MR imaging revealed a 2x2 cm lesion in frontal lobe with radiologic impression of glioma, the lesion was completely resected by neurosurgeons. The resected lesion was sent to pathology laboratory. Grossly, the whole specimen consists of multiple irregular pieces of tan brown, rubbery tissue together measuring 5x3x0.4 cm and borders were not apparent. On microscopic examination, there were proliferation of meningothelial cells and fibroblast-like cells with many variable, predominantly thickened blood vessels (Figure 1 and Figure 2). The mentioned irregularly thick-walled

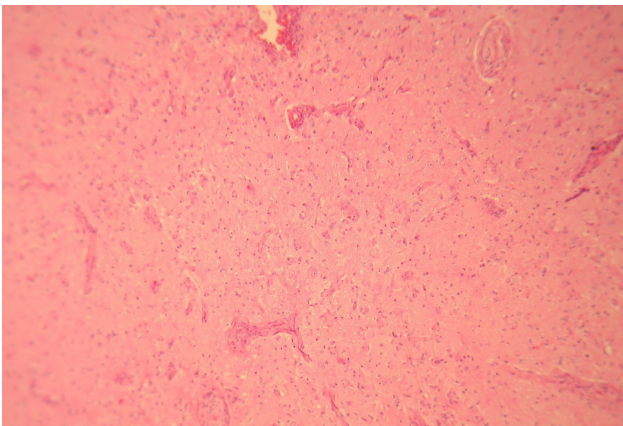


Fig. 1
Figure shows increased cortical vascularity and proliferation of small-size vasculature in the cortex, No mitotic activity, no necrosis, no marked pleomorphism is seen (Hematoxylin and Eosin, 100X)

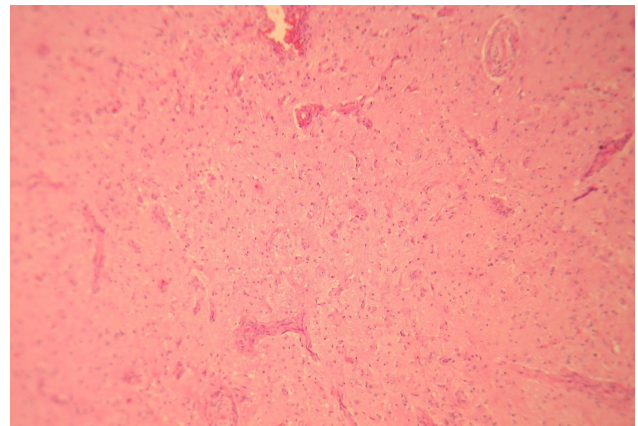


Fig. 2
Irregularly thick walled hyalinized blood vessels are noted. (Hematoxylin and Eosin, 400X)

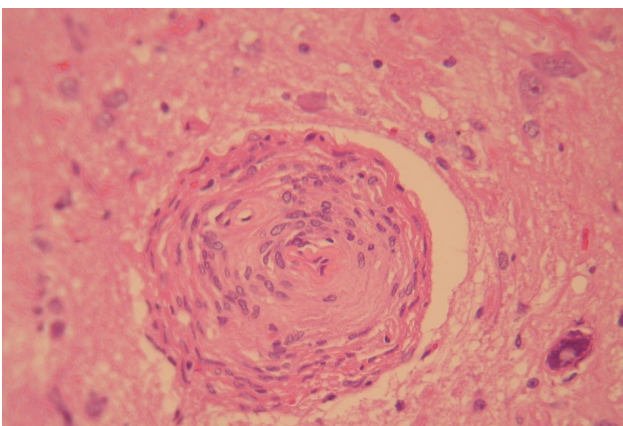


Fig. 3
There is perivascular cuff which is a consequence of prominent perivascular meningothelial cell proliferation. (Hematoxylin and Eosin, 400X)

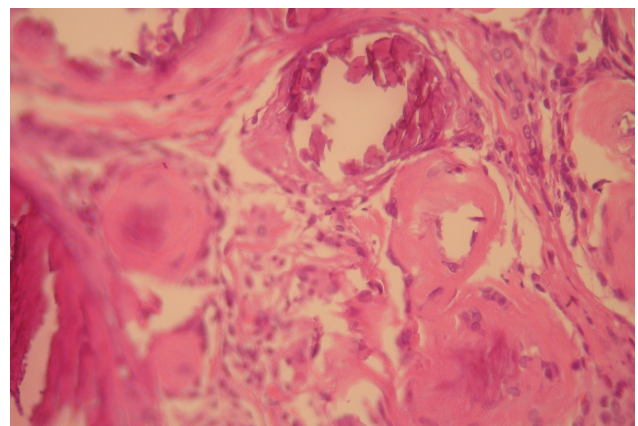


Fig. 4
Calcified blood vessels are seen in the periphery of the lesion (Hematoxylin and Eosin, 400X)

blood vessels and meningotheial cells were extended into the gray matter from the meningeal surface. Calcified psammoma bodies were identified. There was also perivascular proliferation of fibroblast-like cells and meningotheial cells which ensheathed and thickened vessels (Figure 3). Areas of reactive gliosis, some calcified blood vessels with areas of collagenous connective tissue were also seen. (Figure 4) These findings are typical for diagnosis of meningioangiomas.

Immunohistochemistry study showed negativity for CD34, except in endothelial cells of blood vessels; Synaptophysin stained ganglion-like cells (membranous pattern); GFAP was positive in glial cells and background glial components.

Discussion

MA was first described by Peter Bassoe and Frank Nuzum in 1915 in autopsy of a patient with neurofibromatosis type 2 (5). In 1937, Worster-Drought et. al. described another case and named the lesion "meningioangiomas" (6). MA affects both male and female gender although male predilection is noted in the reported cases.

This lesion has been reported in all ages ranging from 14 months to 60 year-old, but the majority of cases are teenagers and young adults (3,4,7).

MA has been reported more frequently in frontotemporal-parietal area although in some cases the lesions were located in brainstem and thalamus, third ventricle, cingulate gyrus, and pulvinar area. Interestingly, a right hemispheric predilection is noted in reported cases (7,8).

The most common clinical presentation of MA is refractory seizures in sporadic MA as in our case. Headache is another less frequent complaint (2,4,7,9). In patients with neurofibromatosis type 2, MA is usually found incidentally in

post-mortem autopsy and it is not associated with seizures (7,8). The tumor is slow growing and does not present with increase intracranial pressure (7).

The exact pathogenesis of MA remains to be elucidated, however, there are several hypothesis in this regard. Till now, MA is mostly categorized as a hamartomatous lesion originating from vessels, leptomeninges and cerebral cortex (1,2,7-9).

The strong association of MA and NF type2 and also increased frequency of meningioma in patients with abnormalities of chromosome 22, have been lead to attention on gene alterations of this chromosome. It has been postulated that a meningioma related tumor suppressor gene is located on chromosome 22, but it appears to be different from NF2 gene (10).

Association of MA with brain lesions and tumors has been reported in five cases which were associated with berry aneurisms and CNS tumors eg. Meningioma and Oligodendroglioma (2,11).

Grossly, in most of the cases, MA described as a solitary well-demarcated, firm thickening of cortex with a meningeal plaque, however, it has been described in other forms of diffuse, multiple and cystic lesions in some cases specially in association with neurofibromatosis (7).

Histopathologically, meningioangiomas shows increased proliferation of small-size vasculature in the cortex. There is perivascular cuff of meningotheial cells and fibroblasts accompanied with collagen deposition in cortex and underlying white matter. Leptomeningeal thickening and calcification around vessels are usually present. Psammoma bodies are also variably identified (1,2,7-9).

Differential diagnosis of MA includes a wide spectrum of brain lesions ranging from benign to malignant entities. The main histopathologic differential diagnosis is invasive meningioma

because the invasive component of meningioma shows the same reactive gliosis and perivascular proliferating spindle cells, but MA has lower index of proliferation. (12) Another differential diagnosis is intracerebral schwannoma which can also show perivascular proliferation of spindle cells around the vessel. (13)

Surgical resection is the treatment of choice and the only curative therapy in almost all cases. The prognosis following surgery is excellent (14).

Conclusively, MA is a rare benign lesion of brain, which can be cured by total surgical removal with excellent prognosis in most of the cases, therefore it is important to diagnose this entity to avoid further invasive treatments. Imaging diagnoses for MA is difficult due to non-specific characteristics. (15) The definite diagnosis relies on histopathologic examination of the tumor. As mentioned above, MA is a hamartomatous lesion it can mimic a vast spectrum of benign and malignant brain lesions, therefore more knowledge about histopathologic characteristics of MA is necessary for pathologist to avoid misdiagnosis.

Conclusion

MA is a rare benign lesion of brain, cured by total surgical removal with excellent prognosis in most of the cases. Therefore it is important to diagnose this entity to avoid further invasive treatments. Imaging diagnoses for MA is difficult due to non-specific characteristics (15). The definite diagnosis relies on histopathologic examination of the tumor. As mentioned above, MA is a hamartomatous lesion which can mimic a vast spectrum of benign and malignant brain lesions, therefore more knowledge about histopathologic characteristics of MA is necessary for pathologist to avoid misdiagnosis.

Acknowledgements

The authors declare that there is no conflict of interests.

References

1. Arcos A, Serramito R, Santin JM, Prieto A, Gelabert M, Rodriguez-Osorio X, et al. Meningioangiomatosis: clinical-radiological features and surgical outcome. *Neurocirugia* 2010;21(6):461-6.
2. Cui H, Shi H, Chen X, Wang W, Lai R, Han A. Clinicopathological Features of Meningioangiomatosis Associated with Meningioma: A Case Report with Literature Review. *Case Rep Oncol Med* 2012;2012:5.
3. Abdulazim A, Samis Zella MA, Rapp M, Gierga K, Langen KJ, Steiger HJ, et al. Meningioangiomatosis in a patient with progressive focal neurological deficit-case report and review of literature. *BRIT J NEUROSURG* 2013;27(2):253-5.
4. Sun Z, Jin F, Zhang J, Fu Y, Li W, Guo H, et al. Three cases of sporadic meningioangiomatosis with different imaging appearances: case report and review of the literature. *World J Surg Oncol* 2015;13:89.
5. Bassoe P, Nuzum F. Report of a case of central and peripheral neurofibromatosis. *J Nerv Ment Dis* 1915; 42: 785-96
6. Worster-Drought, C. , W. E. C. Dickson , and W. H. McMenemey . Multiple meningeal and perineural tumours with analogous changes in the glia and ependymal (neurofibroblastomatosis). *Brain* 1937. 60:85-117.
7. Savargaonkar P, Chen S, Bhuiya T, Valderrama E, Bloom T, Farmer PM. Meningioangiomatosis: report of three cases and review of the literature. *Ann Clin Lab Sci* 2003;33(1):115-8.
8. Omeis I, Hillard VH, Braun A, Benzil DL, Murali R, Harter DH. Meningioangiomatosis associated with neurofibromatosis: report of 2 cases in a single family and review of the literature. *Surg neurol* 2006; 65(6):595-603.
9. Halper J, Scheithauer BW, Okazaki H, Laws ER, Jr. Meningio-angiomatosis: a report of six cases with special reference to the occurrence of neurofibrillary

tangles. *J Neuropathol Exp Neurol* 1986;45(4):426-46.

10. Dumanski JP, Rouleau GA, Nordenskjold M, Collins VP. Molecular genetic analysis of chromosome 22 in 81 cases of meningioma. *Cancer Res* 1990;50(18):5863-7.

11. Cui H, Shi H, Chen X, Wang W, Lai R, Han A. Clinicopathological features of meningioangiomas associated with meningioma: a case report with literature review. *Case Rep Oncol Med* 2012;2012:296286.

12. Li J, Song X, Gui Q. [Meningioangiomas: a clinicopathological study of five cases]. *Zhonghua Bing Li Xue Za Zhi*. 2015 May;44(5):310-4.

13. Ishihara M, Miyagawa-Hayashino A, Nakashima Y, Haga H, Takahashi JA, Manabe T. Intracerebral schwannoma in a child with infiltration along perivascular spaces resembling meningioangiomas. *Pathol Int* 2009 Aug;59(8):583-7.

14. Sun Z, Jin F, Zhang J, Fu Y, Li W, Guo H, et al. Three cases of sporadic meningioangiomas with different imaging appearances: case report and review of the literature. *World J Surg Oncol* 2015; 13: 89.

15. Kunishio K, Yamamoto Y, Sunami N, Satoh T, Asari S, Yoshino T, et al. Histopathologic investigation

of a case of meningioangiomas not associated with von Recklinghausen's disease. *Surgical neurology* 1987;27(6):575-9.

Intracerebral schwannoma in a child with infiltration along perivascular spaces resembling meningioangiomas. *Pathol Int* 2009 Aug;59(8):583-7.

14- Sun Z, Jin F, Zhang J, Fu Y, Li W, Guo H, et al. Three cases of sporadic meningioangiomas with different imaging appearances: case report and review of the literature. *World J Surg Oncol* 2015; 13: 89.

15- Kunishio K, Yamamoto Y, Sunami N, Satoh T, Asari S, Yoshino T, et al. Histopathologic investigation of a case of meningioangiomas not associated with von Recklinghausen's disease. *Surgical neurology* 1987;27(6):575-9.

How to cite this article:

Motevalli D, Kamalian N, Tavangar SM. Meningioangiomas in an otherwise healthy 13 year-old boy: A case report with emphasis on histopathological findings. *Iran J Pathol*. 2016;11(3):291-5.