

<http://www.ijp.iranpath.org/>

A Tete – a – tete of benign, borderline and malignant fibrohistiocytic tumor

Rashmi. M.V¹, Pavithra. P¹, Shivakumarappa. G.M.²

1. Dept. of Pathology, Sri Siddhartha Medical College, Tumkur, Karnataka – 572104, India

2. Dept. of Surgery, Sri Siddhartha Medical College, Tumkur, Karnataka – 572104, India

KEY WORDS

Benign fibrous histiocytoma
Dermatofibrosarcoma protruberans
Fibrosarcoma arising from DFSP

ABSTRACT

Dermatofibrosarcoma protruberans is a relatively uncommon slow growing, locally aggressive fibrous tumor of the skin. It has a propensity of progressing to fibrosarcomatous change in 5% of the cases. We present a case of a 56 yr old male with presented to the outpatient department of surgery, Sri Siddhartha Medical College, Tumkur with a chest swelling in 2013. FNAC was inconclusive and the mass was excised. On histopathology, areas of benign fibrohistiocytic tumor, dermatofibrosarcoma protruberans and fibrosarcomatous dermatofibrosarcoma were identified in the same tumor. Immunohistochemistry confirmed the diagnosis of DFSP with fibrosarcomatous change. Although, transformed DFSP is more aggressive, the prognosis is influenced by the extent of excision and with wide excision, there may be little increased risk for recurrence and metastasis over that of conventional DFSP.

ARTICLE INFO

Received 22 Jun 2015;
Accepted 12 Feb 2016;

©Iran J Pathol. All rights reserved.

Corresponding Information: Dr. Rashmi. M.V., Dept. of Pathology, Sri Siddhartha Medical College, Tumkur, Karnataka – 572104, India. Tel: 09449666400.
E-mail: rashmiarava@yahoo.com

COPYRIGHT © 2016, IRANIAN JOURNAL OF PATHOLOGY. This is an open-access article distributed under the terms of the Creative Commons Attribution-noncommercial 4.0 International License which permits copy and redistribute the material just in noncommercial usages, provided the original work is properly cited.

Introduction

Dermatofibrosarcoma protruberans (DFSP) is a fibrohistiocytic tumor of intermediate malignancy and a well known entity (1). DFSP constitutes 6% of soft tissue sarcomas and of these extremely few cases transform to fibrosarcoma (FS-DFSP) (2, 3). In contrast to classical DFSP, FS-DFSP has an aggressive behavior with regarding the tumor progression, shorter recurrence interval and a poorer prognosis (2). A review of the literature yielded very few cases showing abrupt transition from DFSP to FS-DFSP (4).

However, we describe a case where the benign, borderline and malignant regions were

very well defined and no transitional areas were noted, making it difficult to explain the theory of transition from benign to borderline to malignant fibrohistiocytic tumor. Though, the occurrence of DFSP and FS-DFSP in a single tumor has been reported in the literature, the coexistence of benign, borderline and malignant fibrohistiocytic tumors in the same lesion has not been documented so far. Hence, we present this case for its rare presentation.

Case Report

A 55 yr old male presented with a slow grow-

ing, painless mass on the right side of the chest wall below the nipple and areolar region. On examination, an elevated, violaceous nodule was noted on the skin surface and on palpation a firm mass measuring around 7 x 5 cms was noticed beneath the surface.

After obtaining the necessary consent, fine needle aspiration cytology (FNAC) was performed. The smears were moderately cellular and showed spindle cells in cohesive clusters and singly with a slight tendency towards streaming. These cells showed moderate anisokaryosis, granular chromatin and small nucleoli. However, occasional single cells showed pleomorphism and hyperchromasia. A diagnosis of spindle cell lesion was made and excision advised in the view of the few cells showing pleomorphism. A wide excision of the mass was done and sent for histopathological examination. A nodular mass with an overlying elliptical portion of skin and violaceous nodule was received. The mass in total measured 7 x 5 x 4 cms. The violaceous nodule measured 0.8 x 0.7 cms. Cut section of the violaceous nodule showed a grey-white and homogenous appearance. Beneath the skin surface, three well defined nodules were noticed, of which two nodules were grey-white and homogenous and the third nodule was grey-white and granular. On histopathology, the violaceous nodule was com-

posed of slender, fibroblasts arranged in distinct storiform pattern with occasional mitoses. These features were consistent with DFSP (Fig. 1). The two homogenous nodules showed sparsely cellular areas. The cells appeared bland without any cytological atypia. These areas were considered as benign fibrohistiocytic tumor. The nodule with granular appearance showed fibrosarcomatous change composed of highly cellular areas with spindle cells in sheets and vague storiform patterns. The cells showed moderate pleomorphism, hyperchromasia and 10-12 mitoses/10 hpf (Fig. 2) and infiltration into the subcutaneous fat. On immunohistochemistry, tumor cells showed positivity for CD34 and vimentin. However, CD34 expression was decreased in the areas of sarcomatous change and absent in the surgical margins. It was also not seen in the benign fibrohistiocytic areas. The tumor was positive for SMA and CD117 and Ki-67 was positive in 30-40% of the cells. CD 68, S-100 and desmin were negative. A diagnosis of fibrosarcoma arising in DFSP along with coexistent benign fibrous histiocytoma and DFSP was made.

Discussion

DFSP is a malignant cutaneous tumor locally

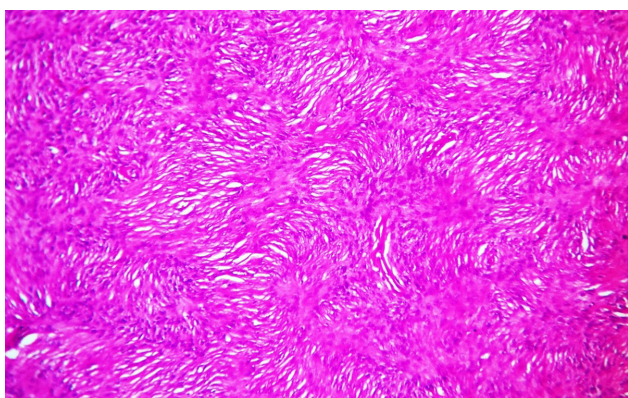


Fig. 1
Photomicrograph areas of dermatofibrosarcoma protuberans showing slender spindle cells arranged in a distinct storiform pattern (H & E, x10)

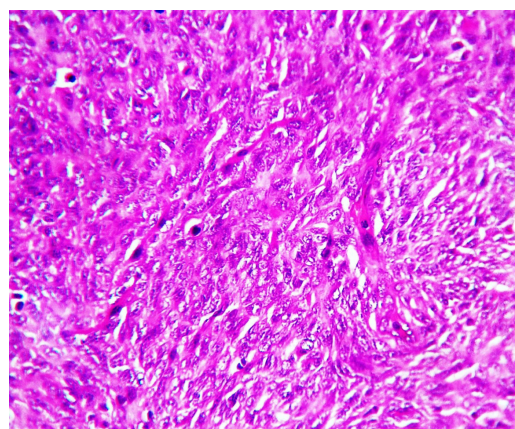


Fig. 2
Photomicrograph showing areas of fibrosarcomatous-DFSP and increased abnormal mitotic activity (H & E, x10)

aggressive and has a low metastatic potential but has a high propensity for local relapse (5). It was first described by Taylor in 1980 as sarcoma similar to keloid and was recognized as a unique entity by Darier and Ferrand in 1924. It was coined by Hoffmann in 1925 as Darier – Ferrand tumor or DFSP as the nodules protruded on the skin (6, 7).

The incidence of this tumor is 0.8 – 5 cases / million / yr and constitutes 2-6% of soft tissue sarcomas, occurring more often in blacks with a M: F: 1:1. It is more common in 30-50 yr of age with the trunk being the most common site of occurrence (40-60%) followed by limbs (20-30%) and head and neck regions (10-15%) (3, 8). The case discussed here also presented on the trunk.

DFSP, being heterogenous morphologically has many variants like fibrosarcoma variant (FS-DFSP), myxoid, atrophic, sclerosing, palisaded, pigmented or Bednar's tumor, granular cell, myogenic differentiation and a combined variant with giant cell angiofibroblastoma (2, 10).

Majority of DFSPs are low grade tumors and only 10-15% contain a high grade FS component (5). The diagnostic criteria for sarcomatous changes in DFSP are the presence of classical features of DFSP on histology and the presence of such a change in at least 5% of the lesion (1, 7). Our case showed sarcomatous change in nearly 25% of the total tumor area. The presence of mitotically active cellular areas composed of spindle cells with FS change or transformation in fascicular pattern defined these areas (1). This change in DFSP is considered as a form of tumor progression which is associated with worse prognosis than the typical DFSP (9). However, in the present case the three differentiations of the tumor presented as three separate nodules, making it difficult to explain the concept of progression.

A transformation should be suspected in cases of rapidly enlarging, sometimes painful tumor (6).

These tumors are strongly positive for CD34 and vimentin. CD34 helps in differentiating DFSP from other soft tissue tumors which stains positive in 84-100% of DFSPs but only half of the cases of FS-DFSPs stain positive with this marker (8, 10). In the fibrosarcomatous areas the staining is lower and weak, focal or negative (10, 11). A CD34 stain at the surgical margins helps in identifying tumor cells and more so in treating recurrent DFSP where the tumor cells are often interspersed within scar tissue (12). They are negative for S100, factor XIIIa, CD44, SMA, desmin, keratin and EMA (5, 10). The present case also was immunohistochemically similar especially with regard to CD34, which was reduced in the sarcomatous areas and absent at the surgical margins. Apo D differentiates DFSP from benign fibrous histiocytoma (5). Nestin, an intermediate filament which is expressed on neuroectodermal stem cells is also expressed in DFSP suggesting an origin from pluripotent neuromesenchymal stem cells. "This marker may help in differentiating DFSP from dermatofibroma" (7).

Molecular studies have shown a reciprocal t (17;22) (q22;q13) a supernumerary ring chromosome derived from the translocation r (17;22) highly characteristic of DFSP in more than 90% of the cases (9, 13). The COL1 α 1-PDGFB fusion transcript is seen not only in conventional DFSP but also in a small series of DFSP with FS areas (6, 9).

The incidence of local recurrence in FS-DFSP is 73-89% and distant metastasis is 14-36 % (2). However other studies quote an incidence of 10-15% risk of metastasis (6). In the present case no recurrence or metastasis was noted after two years of follow up.

The loco-regional extension of tumor sites can be demonstrated by MRI and PET scan before the treatment is initiated, which shows highly intense fixation of fluorodeoxyglucose on tumor sites (6). CT and MRI are useful in deciding the line of excision and to avoid inadequate exci-

sions (14).

The recurrent potential of DFSPs is related to the extent of resection and therefore, local treatment is the crucial determinant of the behavior in case of low to high grade sarcomas of the extremities. Though wide local excisions with negative margins reduce and even at times eradicate the tumors, literature review has yielded cases of local recurrences and dissemination in tumors treated in such a manner (1, 13). Further, in the absence of recurrence, the risk of metastasis is greatly reduced (1). Moh's microsurgery, radiotherapy and chemotherapy have shown to play a role in controlling the local recurrences (3). Excellent prognosis can be achieved with a wide margin of 3-5 cm excision (14).

Conclusion

FS-DFSP is rare and all DFSPs need to be suspected for malignancy on FNAC smears. When such a suspicion arises, a wide excision of the mass should be advised and the tumor should be extensively sampled for the detection of sarcomatous areas. CT and MRI should be performed to assess the margins before surgery and examination of the surgical margins of the resected mass with the aid of immunohistochemical stains will reduce the chances of recurrence.

Acknowledgements

The authors declare that there is no conflict of interests.

References

1. Szollosi Z, Nemes Z. Transformed dermatofibrosarcoma protuberans: a clinicopathological study of eight

cases. *J Clin Pathol* 2005; 58: 751-6.

2. Arican O, Bakaris S, Bulbuloglu E, Ezberci F. Myoid differentiation and EMA expression in fibrosarcomatous dermatofibrosarcoma protuberans. *Acta Dermatoven APA* 2006; 15(1): 39-44.

3. Prabhu R, Kumar N, Sadhu S, Shenoy R. Fibrosarcomatous dermatofibrosarcoma protuberans: A case report of an aggressive soft tissue sarcoma. *J Clin Exp Res* 2013; 1(3): 71-73.

4. Mentzel T, Beham A, Katenkamp D, Dei Tos AP, Fletcher CD. Fibrosarcomatous ("high grade") dermatofibrosarcoma protuberans : Clinicopathologic and immunohistochemical study of a series of 41 cases with emphasis on prognostic significance. *Am J Surg Pathol* 1998; 22(5): 576-87.

5. Angouridakis N, Kafas P, Jerjes W et al. Dermatofibrosarcoma protuberans with fibrosarcomatous transformation of head and neck. *Head Neck Oncol* 2011; 3: 5.

6. Kerob D, Pedeutour F, Leboeuf C et al. Value of cytogenetic analysis in treatment of dermatofibrosarcoma protuberans. *JCO* 2008; 26(10): 1757-9.

7. Serra – Guillen C, Llombart B, Sanmartin O. Dermatofibrosarcoma protuberans. *Actas Dermosifiliogr* 2012; 103: 762-77.

8. Kim SJ, Jung HK, Kim KI. Axillary metastasis in abdominal dermatofibrosarcoma protuberans with the fibrosarcomatous changes: A case report. *J Korean Soc Radiol* 2013; 68(5): 417-21.

9. Szollosi Z, Scholtz B, Egervari K, Nemes Z. Transformed dermatofibrosarcoma protuberans: real time polymerase chain reaction of COL1A1-PDGFB fusion transcripts in sarcomatous areas. *J Clin Pathol* 2007; 60: 190-4.

10. Campos M, Zarco C, Acquadro F. Myxoid dermatofibrosarcoma protuberans in childhood. *Actas Dermosifiliogr* 2012; 103: 422-6.

11. Palmerini E, Gambarotti M, Staals EL et al. Fibrosarcomatous changes and expression of CD34+ and apolipoprotein – D in dermatofibrosarcoma protuberans. *Clinical Sarcoma Research* 2012; 2: 4.

12. Asuquo ME, Umoh MS, Ebughe G. Dermatofibrosarcoma protuberans: case reports. *Ann Afr Med* 2007; 6(2): 80-3.

13. Edelweiss M, Malpica A. Dermatofibrosarcoma protruberans of the vulva: A clinicopathologic and immunohistochemical study of 13 cases. *Am J Surg Pathol* 2010; 34: 393-400.

14. Gupta AK, Singh H, Manalel AM, Jaiswal NK. A rare case of scalp dermato-fibrosarcoma-protruberans with intracranial extension and distant soft tissue and liver

metastasis. *Calicut Med J* 2011; 9(2): 8-11.

How to cite this article:

M.V. R, P P, G.M. S. A Tete – a – tete of benign, borderline and malignant fibrohistiocytic tumor. *Iran J Pathol.* 2016; 11(3):286-90.